

**ANTERIOR GUIDANCE AND CONDYLAR GUIDANCE IN
CLASS II DIVISION 1 MALOCCLUSIONS TREATED WITH
ACTIVATOR AND TWINBLOCK**

The logo of Mahidol University is a large, circular emblem in the background. It features a central golden stupa-like structure with a flame-like base, set against a light blue circular field. This is surrounded by a golden ring containing Thai script. The entire emblem is set within a larger, faint golden circle.

PHANLOP TRIBUPPACHATSAKUL

**A THESIS SUBMITTED IN PARTIAL FULFILLMENT
OF THE REQUIREMENTS FOR
THE DEGREE OF MASTER OF SCIENCE
(ORTHODONTICS)**

**FACULTY OF GRADUATE STUDIES
MAHIDOL UNIVERSITY**

2006

ISBN 974-04-7177-3

COPYRIGHT OF MAHIDOL UNIVERSITY

Thesis
Entitled

**ANTERIOR GUIDANCE AND CONDYLAR GUIDANCE IN
CLASS II DIVISION 1 MALOCCLUSIONS TREATED
WITH ACTIVATOR AND TWINBLOCK**

Phanlop Tribuppachatsakul

Mr. Phanlop Tribuppachatsakul
Candidate

Jiraporn Chaiwat

Assoc. Prof. Jiraporn Chaiwat,
D.D.S., Training in Orthodontics
Diplomate Thai Board of Orthodontics
Major-Advisor

P. Sawraengkit

Assoc. Prof. Pornrachanee Sawaengkit,
B.Sc., D.D.S., M.S.(Orthodontics)
Diplomate Thai Board of Orthodontics
Co-Advisor

Chainut Chongrak

Prof. Chainut Chongrak,
D.D.S.(Hons.), M.S.(Dental Radiology),
Diplomate Thai Board of Oral Diagnostic
Sciences
Co-Advisor

M.R. Jisnuson Svasti

Prof. Dr. M.R. Jisnuson Svasti,
Ph.D.
Dean
Faculty of Graduate Studies

Surachai Dechkunakorn

Assoc. Prof. Surachai Dechkunakorn,
B.Sc., D.D.S.
Diplomate Thai Board of Orthodontics
Chair
Master of Science Programme in
Orthodontics
Faculty of Dentistry

Thesis
Entitled

**ANTERIOR GUIDANCE AND CONDYLAR GUIDANCE IN
CLASS II DIVISION 1 MALOCCLUSIONS TREATED
WITH ACTIVATOR AND TWINBLOCK**

was submitted to the Faculty of Graduate Studies, Mahidol University
For the degree of Master of Science (Orthodontics)

on
April 17, 2006

Phanlop Tribuppachatsakul

Mr. Phanlop Tribuppachatsakul
Candidate

Jiraporn Chaiwat

Assoc. Prof. Jiraporn Chaiwat,
D.D.S., Training in Orthodontics
Diplomate Thai Board of Orthodontics
Chair

P. Pornrachanee Sawacngkil

Assoc. Prof. Pornrachanee Sawacngkil,
B.Sc, D.D.S., M.S.(Orthodontics)
Diplomate Thai Board of Orthodontics
Member

Somchai Satravaha

Clin. Assoc. Prof. Dr. Somchai Satravaha,
D.D.S.(Hons)
Dr.med.dent.(Magna Cum Laude)
Zahnarztin fuer Kieferorthopaedie
Diplomate Thai Board of Orthodontics
Member

Chainut Chongruk

Prof. Chainut Chongruk,
D.D.S.(Hons.), M.S.(Dental Radiology)
Diplomate Thai Board of Oral Diagnostic
Sciences
Member

M.R. Jisnuson Svasti

Prof. Dr. M.R. Jisnuson Svasti,
Ph.D.
Dean
Faculty of Graduate Studies
Mahidol University

Theeralaksa Sudthasthira

Assist. Prof. Theeralaksa Sudthasthira,
Ph.D.
Dean
Faculty of Dentistry
Mahidol University

ACKNOWLEDGEMENT

The success of this thesis can be attributed to the extensive support and assistance from my major advisor, Associate Professor Jiraporn Chaiwat and my co-advisor, Associate Professor Pornrachanee Sawaengkit and Professor Chainut Chongruk. I deeply thank them for their valuable advice and guidance, constructive comments and encouragement in this research.

I wish to thank Associate Professor Jiraporn Chaiwat and Professor Chainut Chongruk for kindness in examining the accuracy of the cephalograms and providing suggestions for improvement during their busy days.

I would like to thank Dr. Sumalee Singhaniyom for her suggestions in statistics.

I would like to thank Clinical Associate Professor Dr. Somchai Satravaha, who was the external examiner of this defense.

I deeply thank my colleagues in Orthodontics for all of their assistance and permitting the use of their cephalograms.

Finally, I also thank my family and Pivara Tangnoi for their entire care, love and kindness encouragement.

Phanlop Tribuppachatsakul

ANTERIOR GUIDANCE AND CONDYLAR GUIDANCE IN CLASS II DIVISION 1 MALOCCLUSIONS TREATED WITH ACTIVATOR AND TWINBLOCK**PHANLOP TRIBUPPACHATSAKUL 4736025 DTOD/M****M.Sc. (ORTHODONTICS)****THESIS ADVISOR : JIRAPORN CHAIWAT, D.D.S., Dip. in Ortho.,
PORNACHANEE SAWAENGKIT M.S. (ORTHODONTICS), CHAINUT
CHONGRUK M.S. (DENTAL RADIOLOGY)****ABSTRACT**

The principle aims of dentofacial orthopaedic treatments of skeletal Class II division 1 malocclusions with Activator and Twinblock appliances are to correct dental arch relationships and to improve the patient's profile. Numerous studies have reported an influence of Activator and Twinblock appliances on orthodontic and orthopaedic effects, but no previous clinical study has considered treatment effects on anterior guidance and condylar guidance of this therapy.

The purpose of this retrospective clinical cephalometric investigation was to evaluate: 1) anterior guidance, 2) condylar guidance, 3) relationship of anterior guidance to condylar guidance, and 4) dento-alveolar and skeletal changes which were produced by Activator and Twinblock appliances in treatment of Class II division 1 malocclusions. A sample group of 53 growing patients (40 Activator and 13 Twinblock; 23 boys and 30 girls; initial mean age 10.47 years) were treated for a mean period of 10.59 months. For comparison, the records of 12 untreated patients (4 boys and 8 girls) were followed to produce control data, which were individually matched to the test group for malocclusions characteristics, age and treatment time. Lateral cephalograms of each patient were taken at pre- and post-treatment. Each cephalogram was traced and digitized by the same individual, and rechecked for accuracy by second and third professional observers. The mean, standard deviation, and correlation for linear and angular cephalometric measurement were analyzed statistically.

The results of treatment effects, when compared with the controls, indicated that the anterior guidance was steeper, whereas there was no significant change in the condylar guidance; the difference between anterior guidance and condylar guidance was increased and the relation of anterior guidance and condylar guidance was improved. In addition, sagittal skeletal and dento-alveolar discrepancies were improved with an increase of mandibular length, retrusion and lingual tipping of upper incisors, and labial tipping of lower incisors. Overbite and overjet were decreased. Anterior facial height was increased. The treatment did not induce remodeling of the glenoid fossa and condyle in position. In conclusion, the anterior guidance can be changed by Activator and Twinblock appliances, but the condylar guidance can not be changed by treatment. Furthermore, the relation between the anterior guidance and condylar guidance was improved and the disclusive movement may be able to be provided.

**KEY WORDS: ANTERIOR GUIDANCE/ CONDYLAR GUIDANCE/
ACTIVATOR/ TWINBLOCK/ CLASS II**

167 P. ISBN 974-04-7177-3

แนวนำปลายฟันหน้า และแนวนำคอนค้ายล์ ในผู้ที่มีการสบฟันผิดปกติแบบที่ 2 ประเภทที่ 1 ที่รักษาด้วยเครื่องมือแอกทิเวเตอร์และทวินบล็อก (ANTERIOR GUIDANCE AND CONDYLAR GUIDANCE IN CLASS II DIVISION 1 MALOCCLUSIONS TREATED WITH ACTIVATOR AND TWINBLOCK)

พัลลภ ศรีบุษชาติสกุล 4736025 DTOD/M

วท.ม. (ทันตกรรมจัดฟัน)

คณะกรรมการควบคุมวิทยานิพนธ์ : จิราภรณ์ ชัยวัฒน์, D.D.S., Dip. in Ortho.,
พรรัชนี แสงวกิจ, M.S.(Orthodontics), ใจนุช จงรักษ์, M.S.(Dental Radiology)

บทคัดย่อ

หลักการของการรักษาผู้ที่มีการสบฟันผิดปกติแบบที่ 2 ประเภทที่ 1 ที่รักษาด้วยเครื่องมือแอกทิเวเตอร์และทวินบล็อกคือ เพื่อแก้ไขความผิดปกติของการสบฟันและปรับปรุงลักษณะใบหน้าด้านข้างของผู้ป่วย การศึกษาที่ผ่านมามีกล่าวถึงผลการรักษาต่อโครงสร้างกระดูกขากรรไกรและผลต่อการเคลื่อนไหวฟัน แต่ยังไม่มีการศึกษาใดที่มุ่งเน้นพิจารณาถึงผลต่อแนวนำปลายฟันหน้าและแนวนำคอนค้ายล์จากการใช้เครื่องมือแอกทิเวเตอร์และทวินบล็อก

การศึกษานี้เป็นการศึกษาแบบย้อนหลังโดยใช้ภาพถ่ายรังสีกะโหลกศีรษะด้านข้าง โดยมีวัตถุประสงค์เพื่อ 1) หาค่าแนวนำปลายฟันหน้า 2) หาค่าแนวนำคอนค้ายล์ 3) ความสัมพันธ์ของแนวนำทั้งสอง และ 4) การเปลี่ยนแปลงของโครงสร้างกระดูกขากรรไกรและฟันที่เกิดขึ้นจากการใช้เครื่องมือแอกทิเวเตอร์และทวินบล็อกในผู้ที่มีการสบฟันผิดปกติแบบที่ 2 ประเภทที่ 1 กลุ่มตัวอย่างทดลองเป็นผู้ยังที่มีการเจริญเติบโต 53 ราย แบ่งเป็นกลุ่มที่ใช้เครื่องมือแอกทิเวเตอร์ 40 ราย ทวินบล็อก 13 ราย แยกเป็นเพศชาย 23 ราย เพศหญิง 30 ราย อายุเริ่มต้นเฉลี่ย 10.47 ปี ระยะเวลาการรักษาเฉลี่ย 10.59 ปี มีกลุ่มตัวอย่างควบคุมแบ่งเป็นเพศชาย 4 ราย เพศหญิง 8 ราย เพื่อเปรียบเทียบผลการรักษา ภาพถ่ายรังสีกะโหลกศีรษะด้านข้างก่อนและหลังการรักษาจะถูกวาดลอกฉายและวัดคำนวณหาค่ามุมและระยะทางของตัวแปรต่างๆ โดยที่ภาพถ่ายรังสีจะได้รับการตรวจสอบคุณภาพและความถูกต้องจากผู้มีประสบการณ์และชำนาญด้านภาพถ่ายรังสีก่อนนำมาวิเคราะห์เพื่อหาผลที่เกิดขึ้นจากการรักษาต่อไป

ผลการศึกษาพบว่าการรักษาามีผลทำให้แนวนำปลายฟันหน้ามีความชันมากขึ้น แต่ไม่พบการเปลี่ยนแปลงของแนวนำคอนค้ายล์อย่างมีนัยสำคัญ ค่าความแตกต่างของสองมุมนี้มีค่าเพิ่มมากขึ้นรวมถึงความสัมพันธ์ที่ดีขึ้น ความผิดปกติของโครงสร้างกระดูกขากรรไกรและฟันได้รับการแก้ไขให้ดีขึ้น ขากรรไกรล่างมีความยาวมากขึ้น ฟันหน้าบนถูกเคลื่อนเข้าด้านใน ฟันหน้าล่างเคลื่อนออกไปทางด้านหน้า การสบกัดกันของฟันหน้าดีขึ้น ความสูงของใบหน้าส่วนหน้ามีค่าเพิ่มขึ้น ไม่มีการเปลี่ยนแปลงของตำแหน่งของหัวคอนค้ายล์และแอ่งกลืนอยด์ โดยสรุปเครื่องมือแอกทิเวเตอร์และทวินบล็อกมีผลทำให้แนวนำปลายฟันหน้ามีความชันมากขึ้น แต่แนวนำคอนค้ายล์ไม่เปลี่ยนแปลง และช่วยทำให้สองแนวนำนี้มีความสัมพันธ์ดีขึ้น

167 หน้า ISBN 974-04-7177-3

CONTENTS

	Page
ACKNOWLEDGEMENT	iii
ABSTRACT	iv
LIST OF TABLES	vii
LIST OF FIGURES	viii
CHAPTER	
I INTRODUCTION	1
II OBJECTIVES	3
III LITERATURE REVIEW	4
IV MATERIALS AND METHODS	36
V RESULTS	53
VI DISCUSSION	99
VII CONCLUSION	148
REFERENCES	150
BIOGRAPHY	167

LIST OF TABLES

Table	Page
1. Comparison of the various mean values of condyle path inclinations in relation to various skull reference lines	12
2. Distribution of dental and skeletal responses of functional appliances	32
3. Sample size description	40
4. Comparison of pre-treatment form of Activator, Twinblock and control groups	54
5. Comparison of post-treatment form of Activator and Twinblock groups	56
6. Comparison of pre-treatment forms of male and female groups	58
7. Comparison of post-treatment forms of male and female groups in treatment groups	60
8. The reproducibility and the method error of the measurement	62
9. Common characteristic of the samples	71
10. Comparison of the difference in mean changes over treatment period between treatment and control group (pre- to post-treatment)	92
11. Correlation between anterior guidance, condylar guidance and skeletal-dento-alveolar variables	97

LIST OF FIGURES

Figure	Page
1. Protruded occlusion (by anterior guidance)	5
2. Disclusion of posterior teeth during protruded mandible movement	7
3. The three controls are two condylar guidances of the articulator, which present the two TMJ, and the incisal guidance form by the incisal guide pin of the articulator	8
4. Likeness of angles, contours, and slideways provided by the articular eminence and the lingual surface of upper anterior teeth	11
5. Diagram of anterior guidance, condylar guidance, and difference of anterior guidance	13
6. Bone involved in the temporomandibular articulation and sagittal section	20
7. Section through the articular eminence in the adult temporomandibular joint and section through growing condylar cartilage of 13-year-old child	21
8. Lateral views of the region of the TMJ in human at 4-year, 8-year, and adult. Development of articular eminence increased with advancing age	23
9. Change in articular eminence inclination during the craniofacial growth period	24
10. Activator appliance has a modest vertical opening and the mandible is advanced so that the incisors are in an edge-to-edge relationship for Class II correction.	27
11. Twin block appliance consists of individual maxillary and mandibular plates with ramps the guide the mandible forward when the patient close down.	28

LIST OF FIGURES (cont.)

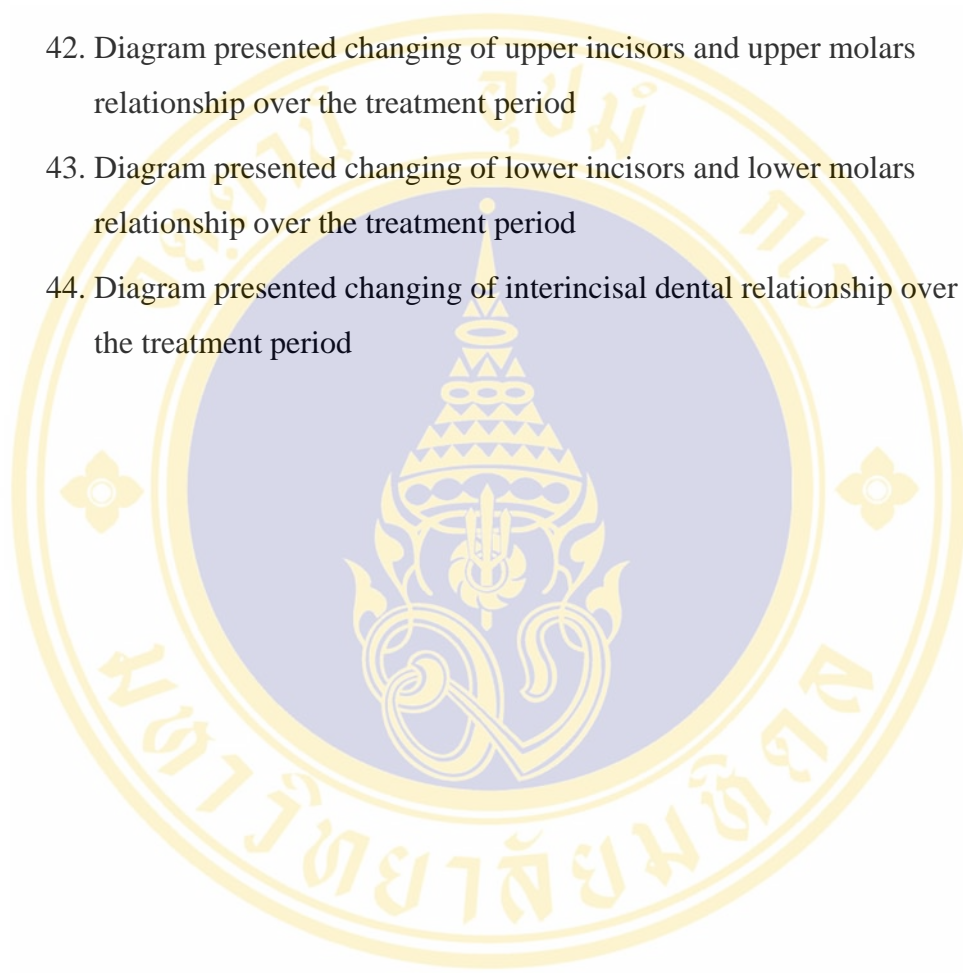
Figure	Page
12. General effects of the functional appliance therapy for the correction of Class II skeletal malocclusions. Thick and thin, solid arrows show major and minor effects respectively	29
13. Adaptive changes in the glenoid fossa and articular eminence	33
14. Lateral cephalograms of before and after treatment, on the right side. Show the decreasing of articular eminence inclination after treatment	35
15. Class II division 1 malocclusions, mandibular retrognathism, maxillary incisors proclination, large overjet and overbite. Hand-wrist radiograph showed MP3-F stage, cervical vertebrae maturation indices showed CVMI-2 stage	38
16. Upper, Twin block appliance. Lower, Activator appliance	39
17. Left, mask film. Right, traced lateral cephalometric radiograph	42
18. Reference points	46
19. Reference planes and lines used in study	47
20. Right, angle measurements. Left, vertical linear measurements	51
21. Horizontal linear measurements	51
22. Treatment results, reduced overbite and overjet, Class I or Class III dental arch relationships established and the soft tissue was acceptable orthodontics profile	64
23. Graph presented Anterior and Condylar guidance measurement	73
24. Graphs presented sagittal skeletal relationship measurement	75
25. Graph presented vertical skeletal relationship measurement	77
26. Graph presented Condylar and Glenoid fossa relationship measurement	79
27. Graph presented dento-alveolar relationship measurement	82
28. Treatment group superimposition. Black lines = pre-treatment, Red lines = post-treatment	84
29. Control group superimposition. Black lines = pre-control, Red lines = post-control	84

LIST OF FIGURES (cont.)

Figure	Page
30. During the appliance was in the mouth, the condyle move along the inclined into the top of articular eminence	107
31. Diagram of anterior guidance (AG-FH), condylar guidance (CG-FH) and the difference of anterior-condylar guidance (AG-CG) between pre- and post-treatment in treatment and control group	109
32. Diagram the comparison of anterior guidance (AG-FH), condylar guidance (CG-FH) and the difference of anterior-condylar guidance (AG-CG) between the treatment and control group in pre- and post-treatment	110
33. Diagram presented changing of anterior guidance, condylar guidance and the difference of anterior-condylar guidance over the treatment period	111
34. Upper and lower posterior teeth interfere with incisive action of anterior teeth if inclination of anterior guidance is flatter than that of condylar guidance	115
35. Diagram presented changing of maxillary sagittal relationship over the treatment period	117
36. Diagram presented changing of mandibular sagittal relationship over the treatment period	124
37. Diagram presented changing of mandibular-maxillary sagittal relationship over the treatment period	127
38. Diagram presented changing of vertical relationship over the treatment period	127
39. Diagram presented changing of facial height over the treatment period	129
40. Illustration of orthopedic treatment. Solid line show forward and downward growth due to treatment. Natural growth (dot line) was backward and downward direction	132

LIST OF FIGURES (cont.)

Figure	Page
41. Diagram presented changing of glenoid fossa and condyle displacement over the treatment period	133
42. Diagram presented changing of upper incisors and upper molars relationship over the treatment period	135
43. Diagram presented changing of lower incisors and lower molars relationship over the treatment period	137
44. Diagram presented changing of interincisal dental relationship over the treatment period	139



CHAPTER I

INTRODUCTION

Orthodontic treatment goals are optimum functional occlusion and oral health (1). The mandible should move harmoniously in three dimensions, rotation, lateral movement, and protrusive movement. In ideal occlusion, when the mandible protrudes, the mandibular incisors should disclude on the maxillary incisors only enough downward vertically to separate posterior teeth in order to prevent excessive wear on posterior teeth and alveolar bone loss due to traumatic occlusion, promote a healthy periodontium and temporomandibular joint (TMJ), and maintain a quite neuromuscular (proprioceptive) mechanism (2).

The mandible can be compared to a tripod configuration. The posterior legs are represented by right and left condyles whose shape helps to generate condylar path, and the anterior leg is determined by incisal point that influences anterior guidance. The three dimensional position of the mandible is determined by these three elements. If the condylar path alone is measured without consideration of anterior guidance, then mandibular movement is not accurately reproduced. Because condylar path and anterior guidance are elements of one anatomic unit, the mandible, they both affect total mandibular movement (3). Therefore the anterior guidance should conform to the condylar guidance to provide disclusive movement.

The articular eminence in humans develops almost exclusively postnatally. Therefore, it not only follows the facial growth plan, but also presents adaptive capabilities (4). When a mandibular protrusive appliance (Activator, Twinblock) is inserted into the mouth, it displaces the mandible forward and downward into a position determined during bite registration. As long as the appliance is in the mouth, the condyles are displaced and kept over the top of the articular eminence. In this position, homeostatic TMJ mechanisms can be triggered. Because of the articular eminence is susceptible to adaptations, one can hypothesize that morphological change will be induced by mandibular protrusive appliances, and that the articular eminence should trend toward reduction of inclination, denoting a decrement of steepness (5).

The articular eminence of TMJ dictates path and type of condylar disk complex movement. It has been suggested that a steep condylar path may predispose to TMJ dysfunction. When using functional appliances, the bite registration is greatly affected by articular eminence inclination. Furthermore, the condylar path relates to anterior guidance. Knowledge of how the articular eminence inclination behaves during the functional appliance therapy period will help establish more biological treatment modalities.

Activator and Twin-block are orthopedic functional appliance, base on the same principle of 'jumping the bite', are always used in treatment of Class II division 1 patients with a skeletal relationship discrepancy, a retrognathic mandible. Activator and Twin-block are designed to alter functions and position of the mandible in order to change in orthodontic (tooth movement) and orthopedic effects (bone remodeling) (6). There are only few previous studies reported the effect of functional therapy in glenoid fossa and articular eminence remodeling, furthermore there are still not clarify in treatment effects. In animal studies (7) found that the glenoid fossa move forward and flattening of articular eminence, however in some human studies (5, 8, 9) reported there are no significant difference in position and morphology of articular eminence (condylar guidance) after treatment. In contrast to anterior guidance alternation that typically it can be changed by orthodontic treatment. Many studies of Activator and Twin-block treatment effects (10-21) have been reported that they always produced retraction of upper incisor lingually. In addition there is no previous study has considered treatment effects and the relation between anterior guidance and condylar guidance before and after Activator and Twinblock therapy.

Therefore the purposes of this retrospective clinical cephalometric investigation are to evaluate: 1) anterior guidance, 2) condylar guidance, 3) relationship of anterior guidance to condylar guidance, and 4) dento-alveolar and skeletal changes which are produced by Activator and Twinblock appliances in the treatment of Class II division 1 malocclusions as compared with a match untreated control sample by using lateral cephalograms.

CHAPTER II

OBJECTIVES

Objectives

1. To investigate anterior guidance, condylar guidance and the difference of anterior guidance and condylar guidance in Class II division 1 malocclusions before and after Activator and Twin-block appliances therapy.
2. To investigate treatment affects on anterior guidance, condylar guidance, skeletal and dento-alveolar in Class II division 1 malocclusions Activator and Twin-block appliances therapy.
3. To find the correlations among anterior guidance, condylar guidance and other craniofacial morphology in Class II division 1 malocclusions treated with Activator and Twin-block appliances.

Expected Benefits

The results from this study will elucidate anterior guidance and condylar guidance in pre- and post-treatment with Activator and Twinblock appliances in class II division1 malocclusions. If both anterior guidance and condylar guidance can be changed by Activator and Twinblock therapy, then anterior guidance and condylar guidance should be altered to conform together to provide harmonious protrusive movement. Orthodontists may use this data to evaluate the position of the maxillary incisors during orthodontic diagnosis, treatment plan and Activator and Twinblock appliances therapy.

The information from the lateral cephalometric radiographs that are routinely taken pre- and post- treatment are always used in diagnosis and treatment plan, furthermore it can also be helpful in providing a rather simple method to find out some functional parameters (anterior guidance, condylar guidance) for treatment planning and evaluating treatment results.

CHAPTER III

LITERATURE REVIEW

Anterior Guidance and Condylar Guidance

Definitions

Anterior guidance

In general, anterior guidance is the part of incisal edge of mandibular incisor that is determined by lingual surface of maxillary incisors, or anterior guidance slope (22). Anterior guidance is the plane that anterior tooth contacts and provide guidance of mandible (23). Anterior guidance have been described by many investigators, such as, Bell (24) stated that anterior guidance was the line tangent to palatal slope of upper central incisors. Huffer (25) used the lingual surface of maxillary central incisors from a point where the lower incisors contacting lingual surface in centric occlusion to lingual anterior tip of upper central incisors as an anterior discluding path or incisal path. Thomson (26) suggested that incisal guidance was the angle which lingual surfaces of maxillary incisor teeth making with the axis-orbital plane influenced the protrusive articular movement. Hobo (27) defined that incisal guidance as the influence of the contacting surface of mandibular and maxillary anterior teeth on mandibular movement (Fig.1).

Anterior guidance can also be called incisal guidance, incisal path, anterior path, anterior controlling factor, anterior lingual inclined plane, maxillary incisal palatal angle etc. depending on investigators.

Condylar guidance

Condylar guidance can be referred to the part that transcranial rotation axes of condyles travel during mandibular opening (28). Okeson (23) stated that condylar guidance angle was the angle at which condyle moved away from a horizontal reference. Huffer (25) used the straight line through the eminence which best approximated its downward slope as a condylar guidance. Bell (24) stated that condylar guidance was the line tangent to posterior slope of articular eminence.

Thomson (26) suggested that condylar guidance was inclination of the paths which condyles followed when making protrusive or lateral protrusive movements. Condylar guidance presented the angle of downward and forward movement of condyle relative to axis-orbital plane. Hobo (27) defined the condylar path as the path traveled by mandibular movement influenced of the contacting surface of mandibular and maxillary anterior teeth on mandibular movement (Fig.1).

Condylar guidance can also be called condylar path, articular eminence inclination, posterior controlling factor, etc. depending on the investigators.

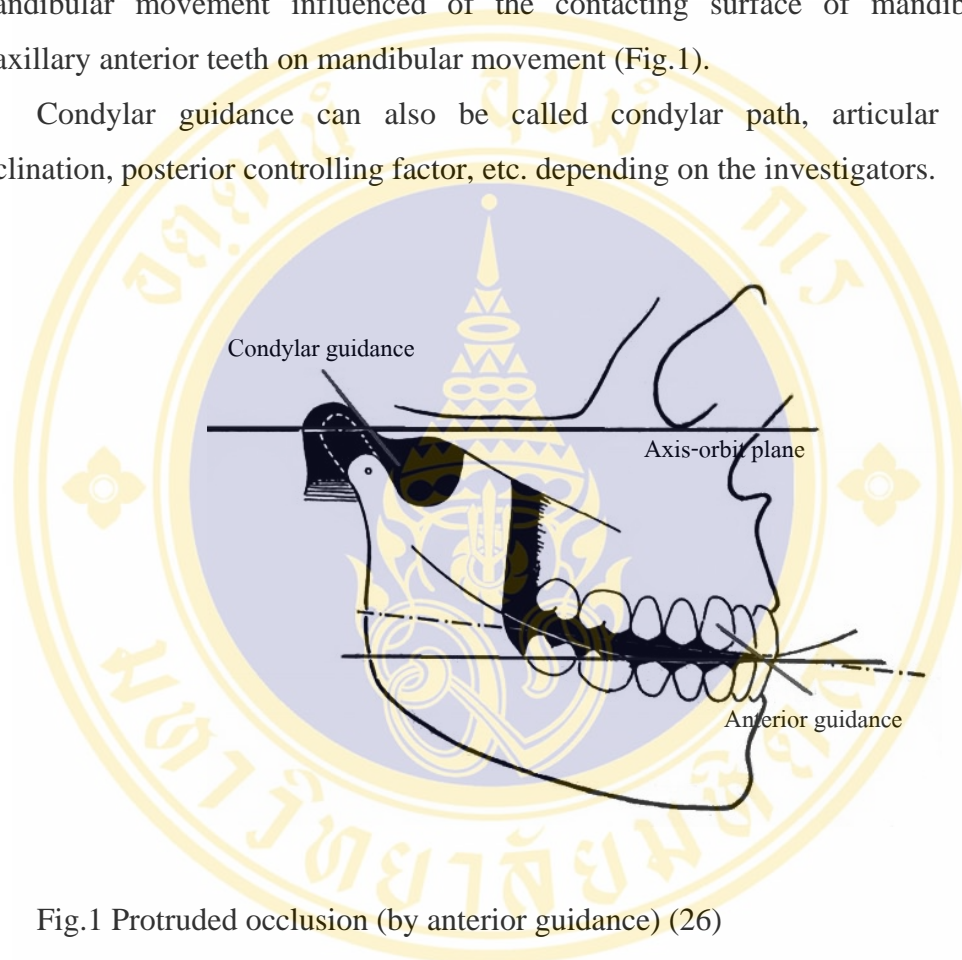


Fig.1 Protruded occlusion (by anterior guidance) (26)

Relationship between Anterior Guidance and Condylar Guidance

In healthy occlusal anatomy, teeth functions should be in harmony with the structures that controlling the movement patterns of the mandible. The structures that determine these patterns are TMJ and anterior teeth. To maintain harmony of the occlusal condition, the posterior teeth must pass close to, but must not contact their opposing teeth during mandibular movement. The structures that control mandibular movement are divided into two types: 1) TMJ are the posterior controlling factors (condylar guidance) that influence the movement of posterior portion of mandible, 2) anterior teeth are the anterior controlling factors (anterior guidance) that influence the movement of anterior portion of mandible (Fig.3) (23).

Posterior controlling factors (condylar guidance) (23)

As the condyles move out of centric relation position, they descend along articular eminence of mandibular fossa. The rates at which they move inferiorly while mandible is being protruded depend on the steepness of articular eminence. If the surface is very steep, the condyles will take a steep, vertically inclined path. If it is flatter, the condyles will take a path that is less vertically inclined. The angle at which the condyles move away from a horizontal reference plane is referred to as the condylar guidance angle.

The two TMJ provide the guidance for posterior portion of mandible and are largely responsible for determining the character of mandibular movement posteriorly.

Anterior controlling factors (anterior guidance) (23)

The anterior teeth determine how the anterior moves. As the mandibular protrudes or moves laterally, the incisal edge of mandibular teeth occlude with lingual surfaces of maxillary anterior teeth. The steepness of these lingual surfaces determines amount of vertical movement of mandible. If the surfaces are very steep, the anterior aspect of mandible will take a steep incline path. If the anterior teeth have little overlap, they will provide little vertical guidance during mandibular movement.

In normal occlusion, the lingual inclines (surfaces) of the six upper anterior teeth may be considered as incisal guide factor. The muscles of mastication and TMJ control movements of mandible while the teeth are out of functional contact. From the

time that the first tooth contact is made until all teeth are in full functional contact, the teeth play a progressively greater role in directing movements of mandible (29).

In the intercuspal position, which is reached with maximal jaw closure, the anterior teeth should make either very light or no actual contact. The lingual surfaces of maxillary incisor teeth provide incisal guidance for mandibular teeth opening protruding movements.

Incisal positions as the key to successful orthodontic treatment and many rules have been developed, in relation to cephalometric, but are unpredictable stable result. Analysis of the coordination of incisor position with dynamics of mandibular movements has to be considered. Inclination and position of incisor are assumed that upper incisal palatal guiding area is reached during function by forward movement; lower incisors should touch the tangent of the palatal curvature of upper incisor perpendicularly at the base point (30).

Improper anterior guidance may lead to excessive posterior and anterior tooth wear, alveolar bone loss, and tooth mobility due to traumatic occlusion, lingual pockets and TMJ dysfunction (2, 31).

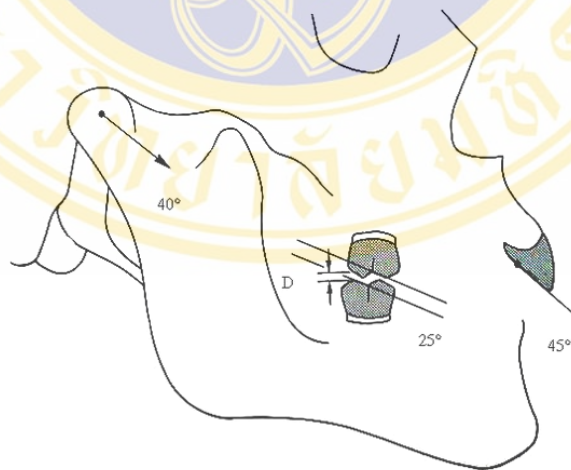


Fig.2 Disclusion of posterior teeth during protruded mandible movement

In an occlusion of natural dentition, there are three factors which have influenced upon or established the occlusal contour of posterior teeth. They are two posterior controls or TMJ, and anterior control or anterior guidance. When an articulating instrument is being used, the three controls are two condylar guidances of the

articulator, which present two TMJ and the anterior guidance form by the incisal guide pin of the articulator and the surface upon which it function. This mechanical incisal guidance represents the incisal guidance provided in mouth by anterior teeth.

These three controls function should be efficiency and harmony of functional occlusion, all intermediate occlusal contours will be influenced by them and must function in harmony with them. There are right lateral, left lateral and protrusive guide factors in incisal guidance which have their respective influences upon eccentric functional occlusion. We must visualize the tripod influence of these three factors (the incisal guidance and two TMJ) operating in all eccentric functional movements of the mandible (Fig.3).

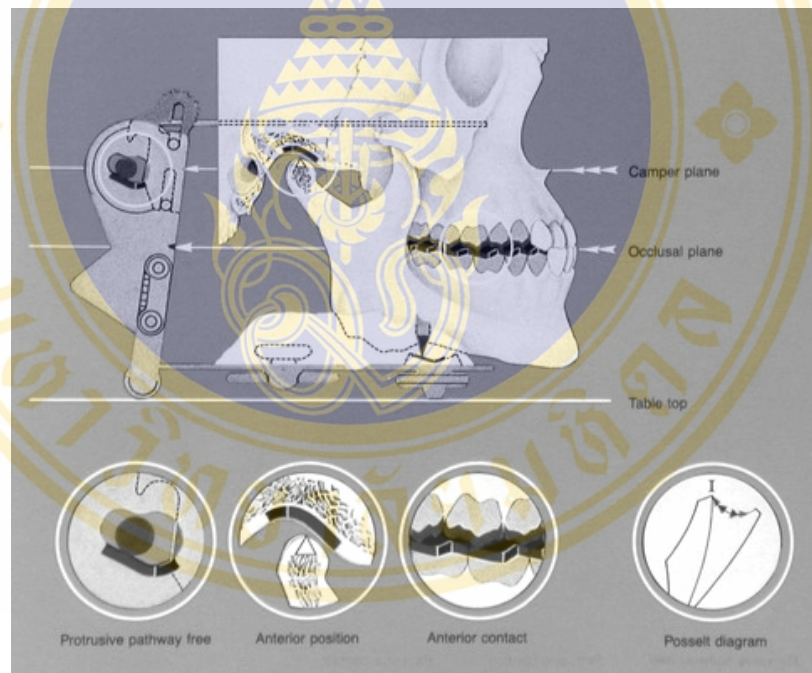


Fig.3 The three controls are two condylar guidances of the articulator, which present the two TMJ, and the incisal guidance form by the incisal guide pin of the articulator (27)

Function and Importance of Condylar Guidance and Anterior guidance

Much has been written about the importance of condylar guidances and anterior guidance. It is of the primary importance and should be so recognized in the planning of all treatment. The paths of movement of the condyle have little or no influence upon the anterior guidance. Through the years of development growth, the anterior guidance may have a definite influence upon the glenoid fossa and the pattern of the movements of the condyles when the teeth are in function. Okeson (23) sited that the condylar guidance is considered to be a fixed factor, because it is unalterable in the healthy patient. It can be altered, however, under certain conditions (e.g. trauma, pathosis, and surgical procedure). The anterior guidance is considered to be a variable rather than a fixed factor. It can be altered by dental procedures, such as restoration, orthodontia, and extractions. Hobo (27) agreed that the condylar path is unchangeable in living body but the anterior guidance can be changed freely by the dentist.

The harmony of anterior guidance and condylar guidance provides harmony movement of mandible (32). In ideal occlusion, when the mandible protrudes, the mandibular incisors should disclude on the maxillary incisors in order to prevent excessive wear on posterior teeth, alveolar bone loss due to traumatic occlusion, and TMJ. If the path of the lingual surfaces of maxillary incisors approximates the path of the condyles down the eminence, the posterior would be released from occlusion rapidly with less change of occlusal interference. If the anterior guidance is much flatter than the condylar guidance, the posterior teeth will increase the chance to wear occlusal, trauma, or TMJ discomfort. If the anterior guidance is much steeper than the condylar guidance, can create unfavorable leverage on the anterior teeth or result in uncomfortable mastication (24, 25, 27). Unfavorable anterior guidance may tend to produce abnormal function movement of the condyles. It may contribute to abnormal stress and movements which are potentially pathologic. A change or modification of unfavorable incisal guidance will have a favorable influence upon the pattern of movement of condyles (33). When anterior guidance is not in harmony with condylar guidance, disadvantage in mandibular function is contribute to TMJ dysfunction (22, 25).

Many investigators have studied the values and relationship of incisal guidance and condylar guidance in difference techniques such as, Huffer et. al. (25) used a

cephalometric technique and SN plane as reference plane to determine the slope of the articular eminence in ideal occlusion subjects and no TMJ symptoms subjects. They found that, SN-anterior discluding path angle (mean 102.3°) was steeper than SN-eminence angle (mean 111.1°) about 5-10 degrees. Bell and Harris (24) investigated the angular relationship between the posterior and anterior disclusive paths, using occlusal plane as reference plane (OP). Two disparate samples, skull and living subject with ideal occlusal were used. They found that, in skull, the angle of the maxillary central incisors (LSA) (mean 125.2°) was steeper than the angle of the articular eminence (AEA) (mean 131.7°). The difference was 6.1° and had a strong positive correlation (coefficient of correlation 0.83). In living series LSA (mean 127.4°) was steeper than AEA (mean 132.2°). The difference was 4.8° and had a strong positive correlation (coefficient of correlation 0.91). They concluded that, there was a strong positive correlation between the angle of the articular eminence and the lingual surface of the maxillary central incisor in individuals with good occlusion and angulations of the articular eminence relative to the occlusal plane may be useful in establishing angulations for the maxillary central incisor.

McHarris (32) suggested that a good condyle and anterior teeth disclusion assured protection for the posterior teeth in all eccentric position. Harmonious and smoothness of the mandible movement through disclusive positions were the likeness of angles, contours, and slideways between eminence and front tooth. Steep eminence slideways allowed steep front tooth slideways and the shallow eminence slideways required shallow front tooth slideways. He recommended that incisal path should be steeper than condylar path for 5° (Fig. 4).

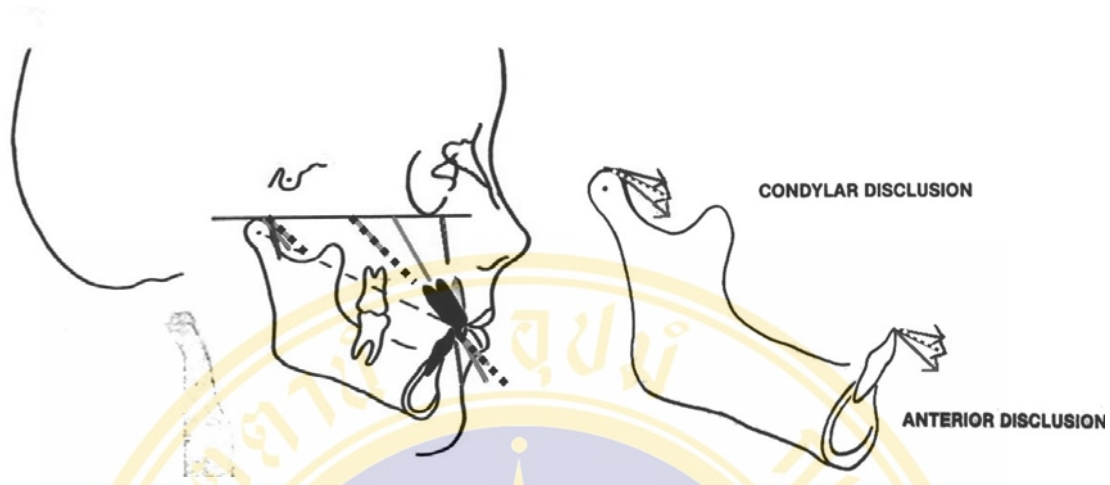

Fig.4 Likeness of angles, contours, and slideways provided by the articular eminence and the lingual surface of upper anterior teeth (32)

Thomson (26) advised that when using articulator for complete denture should increase the condylar guidance by 5° over the protrusive guidance. Hobo (27) suggested adjustment values for generating disocclusion, the anterior guidance should be established to generate the standard amount of disocclusion (1.0 mm. for protrusive movement) and the condylar path and incisal path should be adjusted for 40° and 45° respectively. Kohno (34) measured condylar angle and incisal angle in asymptomatic subjects, he concluded that the incisal path should be steeper than condylar path but should not be more than 25° steeper and the incisal path should not much fatter than the condylar path.

On the contrary, Servadio et. al. (35) examined the condylar angle and the maxillary incisal palatal angle in skulls by using craniographic registrations and using FH plane as a reference plane. He did not find any correlation between the condylar guidance angle (mean 38.8°) and the maxillary incisal palatal angle (mean 39.3°).

Mean of Anterior Guidance and Condylar Guidance

Condylar guidance values have been reported by many investigators and showing great dispersion. Katsavias (5) measured mean of articular eminence inclination in Class II patients by using lateral tomograms. He found that when the articular eminence inclination was measured as the best-fitting line, in reference to the FH plane, it was 47.01° for the left side and 48.34° for the right side. While in reference to the occlusal plane, it was 46.07° and 45.18° for the left and right sides, respectively. Nickel et. al. (36) reported an adult value of 45°. Ichikawa and Laskin (37) reported adult values of 65.9° ($\pm 7.7^\circ$) for steep eminences, 54.8° ($\pm 10.4^\circ$) for moderate eminences, and 47.4° ($\pm 10.4^\circ$) for flat eminences. Panmekiate et. al. (38) reported a value of 36.4° ($\pm 10.4^\circ$). Kersten et. al. (39) reported a value of 49.4° ($\pm 21.7^\circ$).

Olsson and Posselt (40) cited the various mean values of condyle path inclinations in relation to various skull reference lines by various authors in their article that (Table 1):

Table 1 Comparison of the various mean values of condyle path inclinations in relation to various skull reference lines

Author (year)	N	Means (degrees) of condyle path inclination to various reference lines			
		Occlusal plane	Frankfort line	Camper line	Nasion-Sella line
Gysi (1929)	18	31	42	24	46
Gysi (1958)	219	33	44	26	48
Nevakari (1958)	40	34	45	28	49
Isaacson (1959)	36	25	36	29	40
Lindblom (1960)	18	40	50	33	54
Posselt (1961)	101	29	40	23	44

In Thai samples, Wattanatchariya (41) studied anterior guidance, condylar guidance, the difference between anterior guidance and condylar guidance, and relationship in normal and skeletal type I, II, and III by using lateral cephalometric radiographic. She found that the anterior guidance was steeper than the condylar guidance in all group and they correlated positively together. Furthermore, condylar guidance correlated positively with ANB, overbite and Wits, but correlated negatively with SNB and open skeletal configuration. There was a difference in condylar

guidance among normal occlusion and three skeletal patterns. Trend of the steepness of the condylar guidance range from steep to shallow was type II, I, and III respectively. In normal occlusion, means of anterior guidance and condylar guidance were 58.03° and 51.39° respectively. In skeletal type I, means of anterior guidance and condylar guidance were 53.84° and 49.35° respectively. In skeletal type II, means of anterior guidance and condylar guidance were 59.28° and 51.63° respectively. In skeletal type III, means of anterior guidance and condylar guidance were 53.64° and 47.31° respectively (Fig. 5).

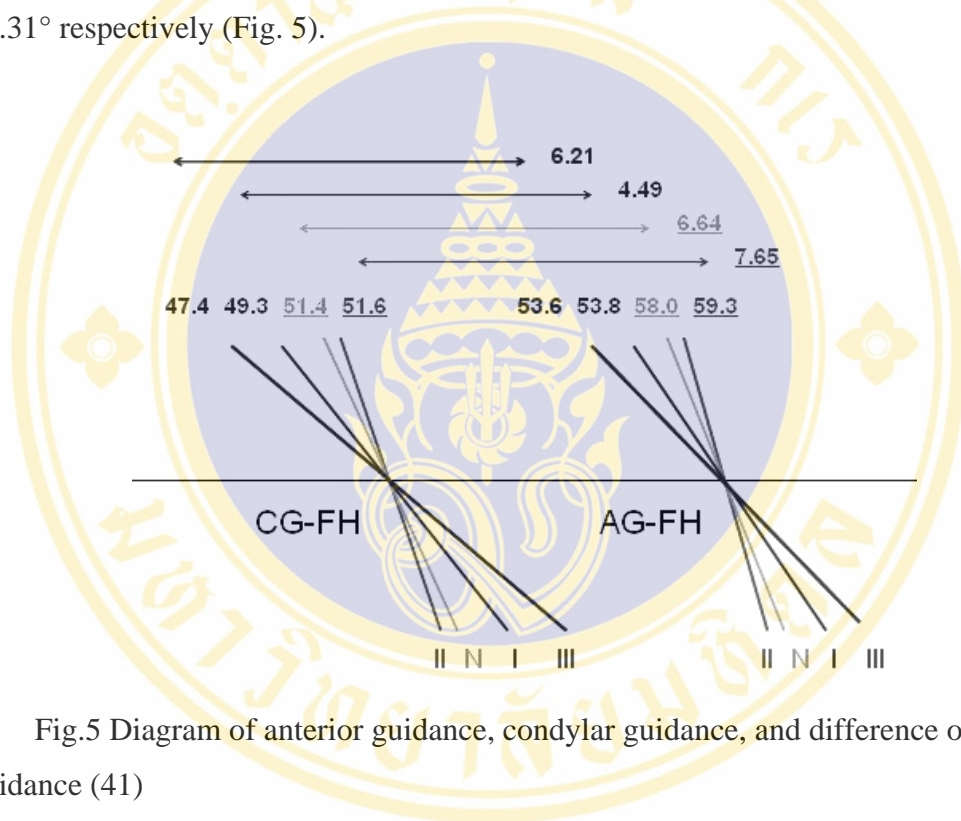


Fig.5 Diagram of anterior guidance, condylar guidance, and difference of anterior guidance (41)

In conclusion, the normal value of condylar guidance angle in adult has been reported to be 30° to 60°, inclination values smaller than 30° have been characterized as flat, whereas values greater than 60° have been characterized as steep. Anterior guidance should be steeper than condylar guidance for 5°. These factors must be carefully evaluated and favorable incisal guidance planned in the initial treatment planning.

Anterior Guidance and Condylar Guidance Investigation Methods

Many methods have been used in measuring the articular eminence inclination and condylar guidance. These methods include impressions done with modeling clay (42), direct measurements, arthograms (38), panoramic radiographs (39), tomographic radiographs (5, 8, 43, 44), MRI of TMJ (45, 46), cephalometric radiograph (25, 41, 47-50), wax recorded of protrusive movement, transcranial radiograph and axiographic records (51).

The method used is a very important factor, as it influences the results. Wax has been criticized as being vulnerable to distortion and shrinkage. Panoramic radiographs of the joint are distorted, making it difficult to accurately and reliably interpret its morphology. The protrusive condylar path is an indirect method of measuring the steepness of the eminence. However, whether the protrusive condylar path tracing can accurately reveal the articular eminence inclination is questionable.

When the mandible moves in protrusive movement, the condylar head will move forward and downward along the anatomical form of the posterior slope articular eminence (22, 25, 32). Inclination of the condylar path measuring with a face bow jaw tracking instrument, has been reported to be correlated with the steepness of the eminence as measuring in lateral cephalometric radiographs (51). Therefore, the cephalometric radiograph method can also be used to estimate condylar guidance angle.

Vary reference planes have been used in anterior guidance and condylar guidance studies, such as, Frankfort horizontal plane, S-N plane, occlusal plane, implant line and Camper line depending on objectives of their studies. Many investigators used lateral cephalometric radiographs and Frankfort horizontal plane as a reference plane to investigate condylar guidance (41, 47, 49) because the Frankfort horizontal plane related closely to the natural horizontal plane when human hold on erect position, that was capable of imaging the articular eminence at the sagittal plane. Furthermore pre-treatment lateral cephalometric radiograph was conventional pre-treatment record and treatment plan accessory.

In addition, there is no significant difference condylar guidance between left and the right side, supported by Ichikawa's study (37) that comparing articular eminence of skull from radiograph and direct measurement and Reungrongrat's finding (52) in

Thai samples by using wax register record. Therefore, the left or the right condylar guidance from lateral cephalograms can represent the condylar guidance of the subjects.

Relation of Anterior Guidance, Condylar Guidance and Others Factors

The anterior guidance and condylar guidance have been studied in relation to its height, facial morphology, tooth inclination, anterior guidance, occlusal morphology, TMJ derangement, and loss of posterior teeth

Condylar guidance and TMJ disorder

The steepness of the articular eminence in the TMJ has been proposed to be an etiologic factor in development of disk displacement, internal derangement and TMJ dysfunction of the TMJ. The flatness or steepness of the condylar guidance dictates the path of condylar movement, as well as the degree of rotation of the disk over the condyle. The steeper of articular eminence, the more that condyle is forced to move inferiorly as its shifts anteriorly. This results in greater vertical movement of the condyle, mandible, and mandibular arch upon opening. It has been reported that during mouth opening, the posterior disk rotation is more prominent in joints with a steep articular eminence than joints with a less steep eminence. The condylar guidance dictates the path and type of condylar disk complex movement. So, the steeper condylar guidance inclination may predispose to TMJ dysfunction (4).

Some investigators suggested that articular eminence inclination had relation to TMJ dysfunction. Kerstens et. al. (53) measured the steepness of articular eminence; they found that the eminence as a predicted in these radiographs was significantly steeper in patients with anterior disk displacement than in control persons without TMJ dysfunction. Sülün et. al. (54) evaluated TMJ morphology of anterior disc displacement patients comparing with symptom-free volunteers. It was proposed that a steeper posterior slope and higher articular eminence are predisposing factors for the development of disc displacement with reduction. Flattening of the eminence may progress in time, leading to the onset of disc displacement without reduction. Kurita et. al. (55, 56) found that disc displacement was less likely to be found in joint with a shallow articular eminence as a result of remodeling or degenerative changes

secondary to internal derangement of the TMJ. Hall et. al. (57) used pantographic tracings to compare the condylar path angle in 29 joints with TMJ clicking and in 326 subjects with asymptomatic TMJ. The result showed that clicking group had more pronounced condylar path angle than normal joints.

On the contrary, Galante et. al. (44) and Ren et. al. (43), studied the comparing of structural variations of articular fossa (slope of articular eminence, condylar inclination, depth of articular fossa) between symptomatic and asymptomatic with TMD. They found no significant differences. Gökalp et. al. (58) found that no correlation between the steepness of the articular eminence in the disc displacement with reduction but correlated with the disc displacement without reduction.

If anterior guidance is so steep the closing muscles would be lengthened beyond their resting length during functional tooth contacting movements, as when steep incisal guidance causes hinge-opening rotation of the mandible during protrusion, a conflict will exist between the muscles and the incisor teeth. The directing incisor teeth cause abnormal movements in the TMJ (59).

However, to the best of our knowledge, there are no available data in the literature with respect to the steepness of the articular eminence in healthy TMJ that are radiographically verified to be free of signs of internal derangement and osseous changes. Because the normal steepness of the eminence in the healthy TMJ is still unknown, any conclusion about the association between a steep eminence and TMJ internal derangement becomes uncertain.

Condylar guidance and mandibular morphology

The fact that congenital absence of condyle is accompanied by articular eminence underdevelopment or absent, denotes strong function dependence and articular eminence development is affected more by function than by skull base characteristics (48). Pirttiniemi et. al.(48) studied the relation of the glenoid fossa to craniofacial morphology on dried skull. They found that a shallow fossa was related to large gonial angle, whereas a steeper condylar guidance angle and the gonial angle were smaller. He also suggested that the location of the glenoid fossa was related to morphologic factors, whereas the articular eminence development was more under function influence.

Kantomaa (60) investigated the role of the glenoid fossa in morphogenesis of the mandible in rats, found that inclination of articular eminence was strongly correlated with the height of the mandible as steeper inclination directed the growth of the condylar process vertically.

The relationships between condylar guidance, condylar growth direction and the shape of glenoid fossa have been studied. Kantomaa reported that a steep inclination of the posterior slope of the articular eminence related to a vertical condylar growth and anterior rotation of mandible. Flat condylar guidance related to posterior condylar growth and posterior rotation of mandible (61).

Condylar guidance and occlusion

Assuming functional dependence, the articular eminence development is related to the present of overjet and overbite in the human dentition. Human mastication requires both incising and grinding functions. Incision requires separate of posterior teeth, whereas grinding requires lateral mandibular movements that are free of incisor or canine interference. These actions can only be achieved by permitting the condyle to slide forward and downward, and this requirement is fulfilled by the articular eminence.

Granados (42) studied correlation between changed in the dentition with tooth loss or extreme wear and changes in the angulations of the articular eminence, concluded that an attrition produced flattening of the articular eminence. Loss of cusp height and anterior guidance was accompanied by resorption of the articular eminence and shallower or completely flat. Loss of cuspal inclination in posterior teeth will produce loss of articular eminence inclination.

The steepness of the eminence may be influenced by the position of the teeth in the arches and skeletal relationships. In skeletal Class III often have shallow angles of eminence, while Class II divisions 2 with lock-in anterior teeth and deep overbite often have steep eminence slope angle and excessive amount of side shift, so early treatment to modify neuromuscular, bone, and growth development should be considered to establish good tooth-guiding relationships (62).

Anterior guidance and skeletal pattern

In facial dimension discrepancy, compensatory or balance property exists in dento-facial complex to preserve the overall harmony and proportions of the facial pattern. Different incisor relationships exist in similar facial types while similar incisor relationships found in different skeletal facial patterns (63). Such as in skeletal Class II, compensatory mechanism allows a good occlusion achieved by the relative tipping of upper and lower incisors.

Incisal inclination is different in different skeletal relationship. In sagittal skeletal relationship, Class II skeletal has relative retroclined upper incisor, while Class III skeletal relative proclined (Class I = 110.18° , Class II = 105.16° , Class III = 114.01°) (63). In vertical skeletal patterns, brachyfacial type has more proclination of incisor than mesofacial type. However, in Class II division 1 malocclusions, the incisal inclination was proclined than Class II division 2 or Class 1 malocclusions.

Anterior guidance correlated with the incisal inclination (41), different incisal inclination in different skeletal pattern, so different anterior guidance in different skeletal pattern too.

Condylar guidance and craniofacial morphology

Ingervall (64) and Widman (49) found that inclination of condylar path was negative correlated with inclination of mandibular plane and vertical jaw relation. A large inclination of condylar path was found in rectangular facial form (brachycephalic facial type), while small inclination of condylar path was found in triangular facial profile (dolicocephalic facial type). The correlation was the same in children as in adults. Cohlmiä (65) found the similar result that shallower condylar guidance associated with openbite and vertical growth pattern patient, while no significant differences in articular slope angle between orthognathic and retrognathic groups.

Ikai et. al. measured dry skulls and reported a negative correlation between the angle of the eminence and ANB angle (66). Akahane et. al. (67) studied in a dry-skull, they found a smaller eminence to FH angle in the Class III group compared with a Class II and Class I groups. Cohlmiä et. al. studied 232 patients with various malocclusions, showed that the group with reduced overjet had smaller vertical height of the articular fossa. Katsavrias and Halazonetis study condyle and fossa shape in

Class II and Class III skeletal pattern, that the Class III group had a wider and shallower fossa than Class II (68).

Agronin et. al. studied the displacement of the glenoid fossa growth during treatment, they concluded the glenoid fossa is displaced posteriorly and inferiorly relative to sphenoid bone during craniofacial development and the amount of displacement can affect mandibular position. Mean spatial relocation of glenoid fossa inferiorly was 1 to 4 mm. and relocation posteriorly was 1 to 3 mm.. It seemed inconceivable that this amount of change could result merely from resorption of the posterior wall of the fossa and deposition of bone on the anterior wall (69).

Condylar guidance and gender

Many studies (41, 43, 47, 52, 64, 70) found no significant difference condylar guidance between male and female, while some found that steeper condylar guidance in male than female (37, 41), however, it still be controversial.

Temporomandibular Joint

The TMJ is one of the most complex joints in the body and is the area in which the mandible (condyle) articulates with the cranium (glenoid fossa). It provides for hinging movement in one plane. At the same time it also provides for gliding movement. Separating these two bones from direct articulation is the articular disc.

Glenoid fossa is the base of cranium, the squamous portion of the temporal bone, which the mandibular condyle articulates. Posterior to the mandibular fossa is the tympanic fissure. Immediately anterior to the fossa is a convex bony prominence, the articular eminence. The degree of convexity of the articular eminence is highly variable but important because the steepness of this surface dictates the pathway of the condyle when the mandible is positioned anteriorly (Fig.6) (23).

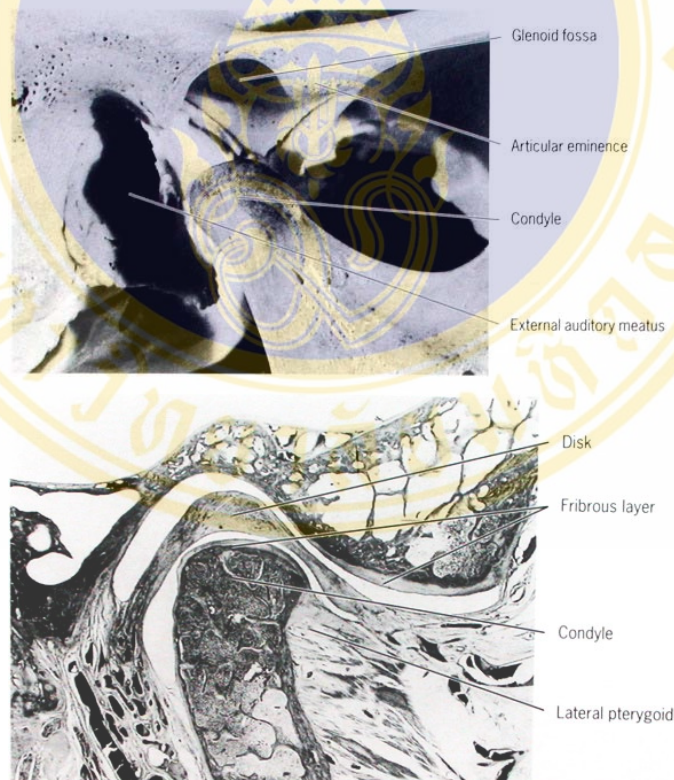


Fig.6 Bone involved in the temporomandibular articulation and sagittal section
(71)

Cartilage Associate with TMJ (71)

A secondary growth of cartilage develops within the blastema associated with the condyle and articular eminence cartilage. The cartilage consists of a proliferative layer of replicating cells functioning as progenitor cells supplying cells to the growth cartilage. Such cells become chondroblasts and elaborate an extracellular matrix and increase in the size of chondroblasts (hypertrophy). Production of cartilages, endochondral ossification occur mineralization of the cartilage, vascular invasion, loss of chondrocyte and the differentiation of osteoblasts to produce bone on the mineralized cartilaginous framework.

The eminence cartilage has a shorter time life span than the condylar cartilage, which exists until the end of second decade. The proliferative activity of the proliferative cells ceases, but the cells persist. It seems quite certain that the cells of the formative proliferative layer may, if the occasion demands, resume their proliferative activity (Fig.7).




Fig.7 Section through the articular eminence in the adult TMJ and section through growing condylar cartilage of 13-year-old child (71)

Mandibular Condyle

Mandibular condyle grows in a constant posterior, superior, and lateral direction. It does not attain its mature contour until the late mixed dentition age. Condylar growth cartilage is approximately 1.5 mm. thick at birth but it thins down in short time to about 0.5 mm.. During the first 2-year of life the growth cartilage is penetrated by vascularized connective tissue septa whose function appears to be nourishment of the

cartilage. The growth cartilage does not show the columnar arrangement of chondrocytes seen in epiphyses, nor are isogenous groups observed. At 16-17 years, the growth cartilage becomes thinner and closing plate of bone is beginning to coalesce below it (Fig.7) (72).

The mandibular condyle changes its shape and length by subarticular proliferation of connective tissue cells that differentiate into fibrocartilage. The fibrocartilage is eroded by osteoclasts at the metaphyseal surface and replaced by lamellar trabecular bone. This process is similar to the ossification that occurs beneath the articulating cartilage of the epiphysis of long bones (73).

Both articulating surfaces of TMJ can adapt but it is by different mechanisms. In the temporal fossa, the subarticular proliferative zone is the cambium layer of the periosteum. It can support both anabolic and catabolic bone modeling to change the shape and position of the temporal fossa in response to environment demands. On the other hand, subarticular proliferation of the mandibular condyle produces fibrocartilage, which is eroded at the endosteal surface and replaced with lamellar trabecular bone (73).

Development of Mandibular Fossa and Articular Eminence

The first evidence of joint development is seen at 3 months of embryonic development when two condensations, the temporal and condylar blastema, form in the mesenchyme lateral to the primary jaw joint. A membranous ossification center next appears in the middle of the temporal blastema and this is followed by the appearance of cleft which is the inferior and upper joint cavity. Cartilage appears in the condylar blastema.

At birth no eminence is evidenced and its development is associated with a slender strip of growth cartilage along the slope of the eminence. In neonatal period, medially along the articular eminence, the chondroid bone becomes progressively less apparent and normal endochondral ossification is seen. Bone is present beneath the articular tissue along the roof of the mandibular fossa. By 8 months of age, the articular surface of age, the articular eminence and postglenoid region enlarge. By 2.5 years of age, the articular eminence increase in size as a result of mineralization of chondroid bone and direct bone deposition anteriorly and posteriorly, and resorption

of bone in the roof of the mandibular fossa. The TMJ has adopted a mature S-shaped curved. This process continues by 6-7 years of age, compact osseous tissue and secondary osteons present within the articular eminence and postglenoid process. The growth continues through the period of late mixed dentition, 7-12 years of age.

The mandibular fossa is flat at birth and becomes progressively more S-shaped during postnatal development, with the mandibular becoming concave and the articular eminence becoming convex (Fig.8) (71).

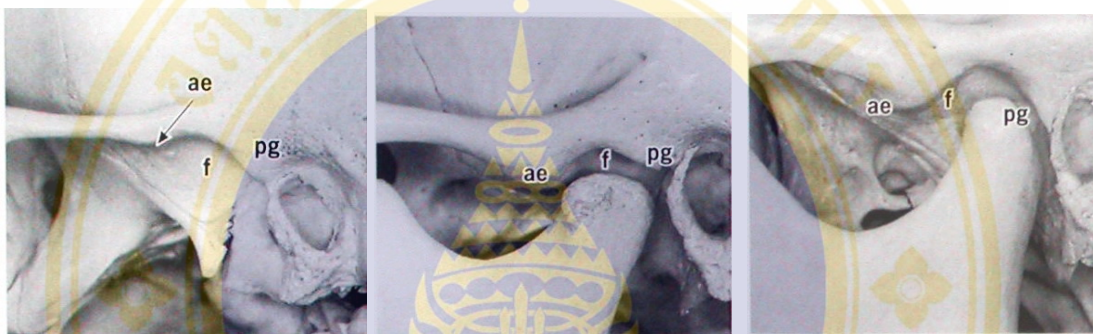


Fig.8 Lateral views of the region of the TMJ in human at 4-year, 8-year, and adult. Development of articular eminence increased with advancing age (71)

In the second and third decade, the morphologic changes progressive slow. In adult, the articular eminence present of chondroid bone and very occasional cartilage cells islands. Up to the fifth decade, the mandibular fossa becomes even deeper as the articular eminence growth inferiorly. After that time the articular eminence tends to become flatter, especially in individual who have become partially or completely edentulous and have reduced loading force on the eminence (71).

Development of Articular Eminence Inclination

The early development of the eminence was dependent on the stimulation of bone growth by appropriate position and timing of loading of the immature condyle on the TMJ eminence (36). Katsavrias (4) studied change in articular eminence inclination during the craniofacial growth period, in dried skulls. The results shown that mean articular eminence inclination measured as the best fit line on its posterior surface to FH plane was 26° at age 2 (dental age), 42° at age 10, 56° at age 20, and 59° at age 30. Inclination had attained 40% of it final size by age 2, 70% by age 10, 94.5%

by age 20, and gained the remaining 5.5% by the age of 30. There were 10 degrees increasing between the edge of 7-15 years or 1.25 degrees increased per year. He concluded that the articular eminence inclination had a period of very rapid changing during development of the deciduous dentition and then slows. The eminence inclination developed almost exclusively postnatally, denoted a strong functional dependence (Fig.9).

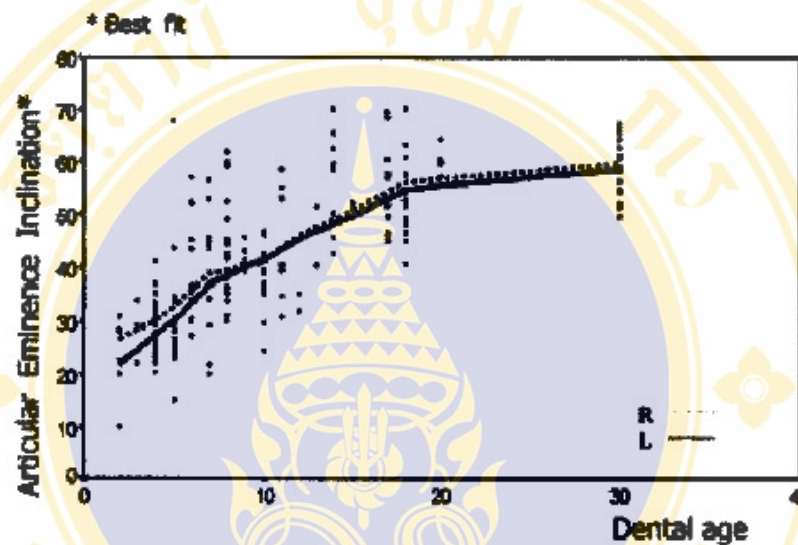


Fig.9 Change in articular eminence inclination during the craniofacial growth period

In Katsavrias's article (4), he cited Ricketts' finding, that from 200-joint of individual Class I and II malocclusions. The eminence inclination was 46° at age 7.5-year (77.9% of its mature form), 52° (88%), 57° (96.9%), and 59° at age 12.5, 18.5, 22-year respectively.

Nickel et. al. (36) studied a eminence development of postnatal human TMJ in dried skulls. The results shown that the average articular eminence inclination measured as the intersection of a tangent line through the posterior slope of the eminence and the occlusal plane acquired more than 50% of its mature form by 3-year of age. Between the ages of birth and 3-year, the articular eminence inclination changed from 12° to 25° . After 3-year of age, development continued at a reduce rate into the late adolescent years. At age 18-year, the eminence angle was 45° . They concluded that: 1) the TMJ eminence reached more than 50% of mature size, and

exhibited mature morphology, by the time of completion of the primary dentition; 2) the maximum velocity of eminence development was before 3-year of age and reduced velocity at 5-year of age, and slowly diminished to zero by the middle to late teens.

Under normal conditions the articular eminence inclination has a symmetrical pattern of growth. No significant differences of articular eminence inclination angle between the left and the right sides of the male and female (70).

Knowledge of the way in which the articular eminence grows is very important, as such knowledge will help to establish and apply more biological therapeutic orthodontic modalities, especially in case Class II are characterized by steep and high articular eminences. However, it is not know which factors influence this development such as, if the lingual inclination of the upper incisors has any participation.

TMJ Remodeling

Joint growth stops at about 18-20 years of age (earlier in men than in women). After that time soft and hard tissues undergo continuous change, i.e. they are continuously remodeled. Articular remodeling is considered as normal adaptation of soft and hard tissues to load changes within the joint. Progressive and regressive remodeling is described. Progressive remodeling is characterized by tissue proliferation, i.e. by an increase in the volume of the remodeled tissue with either higher cell density and/or higher number of cells of a certain phenotype. Regressive remodeling is a decrease in tissue volume and in cell number as well as other signs of tissue degeneration. Joint remodeling leads to change in the shape of the condyle and fossa which may disturb normal joint biomechanics (74).

Functional Appliances

Definition and Purpose

The common denominator of all so-called functional appliances is the forward and downward movement of the mandible to a position determined during bite registration. Depending on type of appliances used, the mandible is kept in this position part of the time, usually for 12-14 hours per day, or full time and stays and functions in this new position as long as the appliance remains in the mouth.

The functional appliances are designed to alter the neuromuscular environment of the oro-facial region to improve occlusal development and/or craniofacial skeletal growth in order to (75): 1) provide a more favorable environment for the developing dentition, 2) optimize the growth of the craniofacial skeletal, 3) change the directions of craniofacial growth, 4) inhibit skeletal growth selection, 5) guide erupting teeth into more favorable positions. Functional jaw orthopedic appliances are used in much more frequent in the mixed dentition during growth spurt.

Case Selection

Functional appliances have been found to be most successful in correcting Class II division 1 malocclusions presenting features: 1) a potential for forward mandibular growth must present, during the circumpubertal growth spurt. 2) The lower face appears to be shorter than average, the chin retrusive and the mandible apparently tucked up and locked by this relation to the maxilla (76).

Types of Functional Appliances

There are many types of functional appliance design available for using in the correction of Class II division 1 malocclusions. In Orthodontic department, faculty of Dentistry, Mahidol University, popular functional appliances are Activator and Twin-block appliances.

Activators appliance

The original mono-block designed by Robin in 1902 was a one-piece removable appliance. Andresen and Häupl, who introduced the use of the Activator, believed that the repetition of the new mandibular closure pattern induced a musculoskeletal

adaptation and resulted in the reeducation of the orofacial musculature (6). The Activator consists of a loose plastic device fitted on the lingual side of both upper and lower dentitions and constructed to a bite which has altered the mandible's function position. A labial bow contains the maxillary incisors, while the lower incisors are capped with acrylic (75). The current design, flutes are replaced by a plastics shelf to impede eruption of lower posterior teeth, and lower incisors are capped to control forward displacement of the lower arch (Fig.10) (77).



Fig.10 Activator appliance has a modest vertical opening and the mandible is advanced so that the incisors are in an edge-to-edge relationship for Class II correction

Twinblock appliance

Twinblock was developed by Clark in 1977 (16), consists of two units, upper and lower units, which position the mandible forwards through the use of interlocking occlusal bite blocks. The dependent units facilitate speech and eating with the appliance in place, and improve patient compliance and consequently increase treatment success (78).

Twinblock is constructed to a protrusive bite that effectively modified the occlusal inclined plane by means of acrylic inclined planes on occlusal bite blocks. The purpose is to promote protrusive mandibular function for correction of the skeletal Class II malocclusions. The occlusal inclined plane act as a guiding mechanism caused the mandible to be displaced downward and forward (16). Twinblock is designed to be worn 24 hours per day to take full advantage of all functional forces applied to the dentition including the force of mastication (Fig.11) (16).

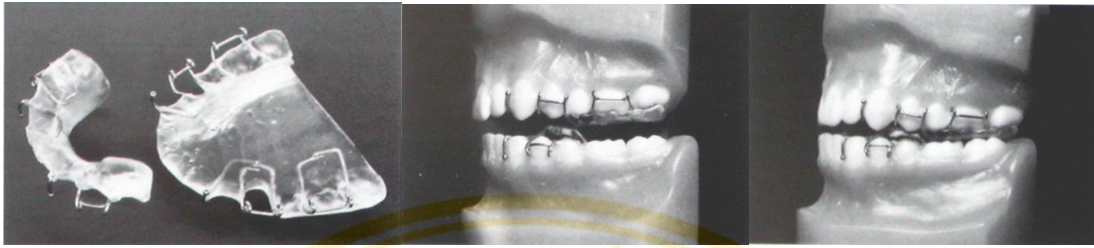

Fig.11 Twinblock appliance consists of individual maxillary and mandibular plates with ramps the guide the mandible forward when the patient close down

Construction Bite

The construction bite determines the sagittal and vertical displacements of the mandible and the degree and direction of appliance activation. Numerous differences in construction bite design have been used by many authors. Andresen (79) increased the vertical dimension between the molars by 3-4 mm. and end-to-end incisor relationship in horizontal dimension. Harvold (80) increased the vertical dimension 5-6 mm. beyond the rest position and Class I molar relationship. Katsavrias (5) suggested a bite registration with the incisors brought to edge-to-edge relationship and a 3-mm. vertical separate brings the condyle to the top of the eminence. Other authors increased in vertical dimension range from 5-10 mm., advanced in antero-posterior dimension to Class I molar and end-to-end incisor relationship (9, 12, 14, 16).

Mode of Action

Some authors suggested that the skeletal responses to functional jaw orthopedic appliances can be summarized as follow, stimulation or enhancement of mandibular growth, no change in the amount of mandibular growth, but creation of more favorable direction of growth. The responses have important changes in amount, timing, and/or direction of condylar growth, adaptive alterations within the basilar portion of the temporomandibular articulation. The responses are changed in the muscle-bone interface (i.e., the attachment sites of muscle to bone) and shape in bone and/or region of bones. The appliances also immobilize repositioning of the mandible (denied masticatory function), immediate and profound effect on the morphology of the condylar cartilage and a dynamic diminution in growth changes of the region (75).

The mode of Activator and Twin block appliances involve reflex forward posturing of the mandible, which is followed by second growth adaptation of the condylar cartilage and subsequent remodeling of the glenoid fossa. If this correction is retained for a sufficient length of time, then differential tooth eruption and remodeling of bone and muscle attachments will occur (45).

Others suggested that the mandible does not increase in length but instead that the glenoid fossa remodels in a more forward position. In the treatment of the Class II division 1 malocclusions, functional appliances create an intermaxillary attempt to return the condyles to their unstrained position in the glenoid fossa. All appliances have a labial bow across the maxillary anterior teeth. The distally directed intermaxillary force tends to tip the upper incisors lingually and restrains forward movement of the maxillary arch. Simultaneously, there is reactive force that tends to move the lower incisors labially (Fig.12) (76).

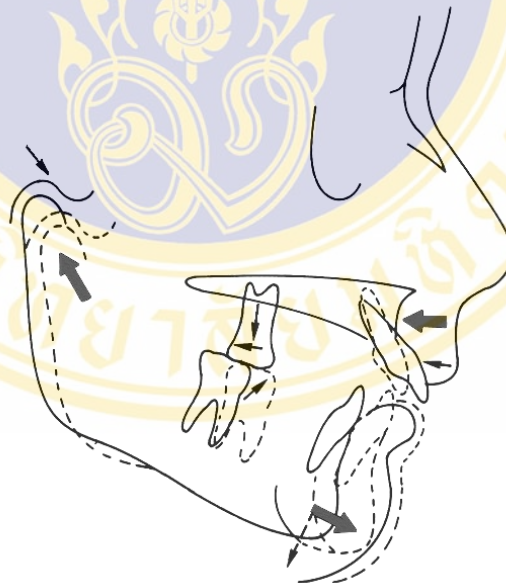


Fig.12 General effects of the functional appliance therapy for the correction of a Class II skeletal malocclusions. Thick and thin, solid arrows show major and minor effects respectively (76)

Skeletal and Dental Changes Contributing to Class II Correction

Effects of Activator and Twinblock treatment in correction of Class II malocclusions can be achieved by (Fig.12) (14)

1. Inhibition of forward growth of the maxilla
2. Inhibition of mesial migration of maxillary teeth
3. Inhibition of maxillary alveolar height increment and extrusion of mandibular molars
4. Increased growth of the mandible
5. Anterior relocation of the glenoid fossa
6. Mesial movement of the mandibular teeth
7. Combination of these effects

Effect on mandible, maxilla, and dentition

Many investigators have reported that functional appliances can increase mandibular growth in size, inhibit forward growth of the maxilla and maxillary dentition, increase mesial movement of lower dentition, and also forward remodel of glenoid fossa.

Birke et. al. (9) suggested that the major effect of Activator treatment were an increased amount of condylar growth and remodeling of the articular fossa. Condylar growth during the 10-month period was increased 1.1 mm. and slightly forward displaced of glenoid fossa. Vardimon et. al. (81) found that the overjet correction was achieved by retroclination of the upper incisor (43.5%), lower incisor proclination (22%), maxillary skeletal growth constraint (21%) and mandibular advancement (13.5%).

O'Brien et. al. (18) used a modified Twinblock and found that the overjet correction was due to the dental changes (73%), which included retroclination of the upper incisors (44%) and proclination of the lower incisors (29%). Skeletal changes (27%) consisted of a slight maxillary retraction (13%) and mandibular advancement (14%). Vargervik and Harvold (14) found that the Activator inhibited the horizontal growth of the maxilla by 2 mm., the appliance also caused 1.4 mm. of maxillary incisor lingual tipping and 0.5 mm. of mandibular incisor labial tipping.

Cozza et. al. (11) studied the effectiveness of Activator therapy, separately the dental and skeletal response and comparing with untreated control group. They found that the overjet was reduced 6.67 mm. by maxillary incisor palatal tipping 8% (0.55 mm.) and mandibular labial tipping 26% (1.72 mm.), maxilla move backward 19% (1.26 mm.), and mandible move forward 47% (3.14 mm.).

However, some investigators did not agree with the orthopedic effect correction. The Class II malocclusions were improved by orthodontic effect only. Pancherz found that mandibular growth increased by 0.3 mm. per year compared with the control group, but this was not statistically significant. The overjet correction (5 mm.) was mainly due to a retroclination of the upper incisor (2.5 mm.) and to the mandibular advancement (4.7 mm.), whereas the lower incisor did not change its position significantly (0.1 mm.). More than 70% of overjet was corrected by incisor tipping, 50% (2.5 mm.) by lingual movement of the maxillary incisor, while 22% (1.1 mm.) by mandibular incisor flaring. He concluded that the magnitude of mandibular growth was not affected by Activator treatment (12). Closed to Nelson et. al. studies, they could not find the evidence to support the view that either appliances were capable of altering the size of the mandible (82).

The distribution of dental and skeletal responses to functional appliances can be summarized in the following table. Both Activator and Twinblock can also give similarly effects in correction of Class II malocclusions (Table. 2).

Table.2 Distribution of dental and skeletal responses of functional appliances (10-12, 17-19, 81)

	Maxillary			Mandibular		
	Skeletal	Incisor	Molar	Skeletal	Incisor	Molar
Jakobsson et. al., 1967*		-2.0			+1.2	
Wielander et. al., 1979*		-3.33			Non-sig	
Pancherz, 1984*	-2.3	-2.5	+0.4	+4.7	+0.1	+2.3
Weiland et. al., 1997*		-1.10		+2.02	+1.01	
Illing et. al., 1998**	-0.5	-3.3		+3.2	+2.1	
Mills et. al., 2000**	+0.6	-0.6	-1.6	+3.8	+1.8	+1.4
Vardimon et. al., 2001*		-43.5%		+13.5%	+22%	
O'Brien et. al., 2003**	-13%	-44%		+14%	+29%	
Basciftci et. al., 2003*	+0.73	-1.81		+6.66	+0.58	
Cozza et. al., 2004*	-1.26	-0.55	+0.37	+3.14	+1.72	-1.17

* Activator appliance, ** Twin block appliance

(-) backward direction, (+) forward direction

The influence on glenoid fossa and articular eminence remodeling

The influence on glenoid fossa and articular eminence have been studied by many investigators by difference methods, such as, histological study, MRI, tomograms, lateral cephalograms and laminagraphy methods. Most of them were studied in animal subjects. They have been suggested by many investigators that the glenoid fossa and articular eminence can be remodeled by functional appliances. The glenoid fossa may be moved forward to correct Class II skeletal discrepancy. The articular eminence may be adapted in response to protrusive function, therefore articular eminence inclination or condylar guidance may be altered during or after functional therapy.

The influences of Activator and Twinblock appliances, firstly involves reflex forward posturing of the mandible, which is followed by secondary growth adaptation of the condylar cartilage and subsequent remodeling of glenoid fossa. If this correction is retained for a sufficient length of time, then differential and remodeling of bone, cartilage, and muscle attachments will be occur (45).

Woodside et. al. (7) investigated remodeling changes in condyle and glenoid fossa following a period of progressively activated and continuously maintained mandibular advancement using Herbst appliance. They concluded that, in primates, continuous and progressive mandibular protrusion produced extensive anterior remodeling of glenoid fossa. This glenoid fossa remodeling contributed to anterior mandibular positioning and altered jaw relationships. In all experimental animals, a large volume of new bone had formed in glenoid fossa, especially along the anterior border of postglenoid spine. With this bone formation, and the resorption along the posterior border of postglenoid spine, glenoid fossa appeared to remodeling anteriorly (Fig.13).

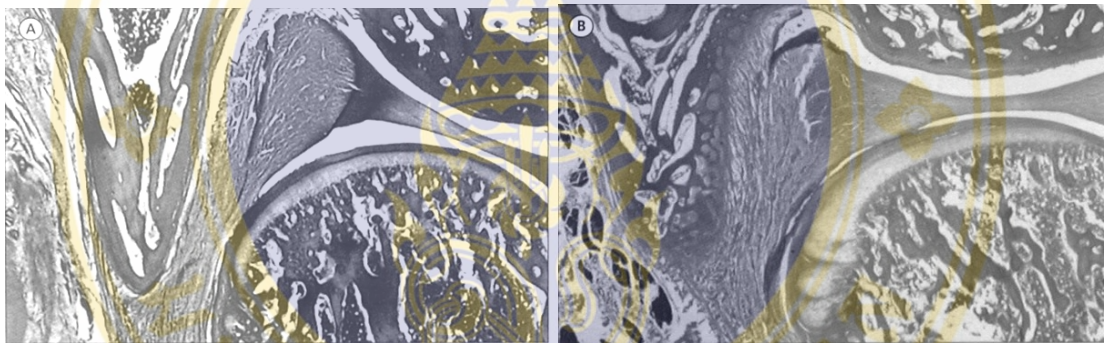


Fig.13 Adaptive changes in the glenoid fossa and articular eminence (7)

Hinton et. al. (83) studied temporal bone adaptation in response to protrusive function in monkeys. They found that the most pronounced of these involved deposition of new bone in the posterior region of the mandibular fossa (fossa roof and postglenoid spine), paralleled in time that condylar cartilage response to protrusion. It was suggested that the osteogenic response may be triggered by periosteal tension transmitted by fibers of the posterior portion of the articular disc.

Ruf and Panherz (45) investigated adaptation of TMJ growth to increase mandibular prognathism by Herbst appliance in condylar remodeling, glenoid fossa remodeling, and condyle-fossa relationship changes for average treatment period of 7 months. They found that MRI-signs of glenoid fossa remodeled at the anterior surface of the postglenoid spine. Condylar remodeling seemed to precede fossa remodeling.

The direction of condylar growth was changed relatively more horizontal in the treated cases.

Rabie et. al. (84) studied replicating mesenchymal cells in the condyle and the glenoid fossa during mandibular forward positioning in rats to identify and quantify the temporal sequence of replicating mesenchymal cells during natural growth and mandibular advancement in the glenoid fossa. The result showed that the numbers of replicating mesenchymal cells during natural growth were highest in the posterior region of the condyle and the anterior region of glenoid fossa. In the experimental groups, the posterior region had the highest number of replicating cells for both the condyle and glenoid fossa. The condyle had 2 to 3 times more replicating cells than the glenoid fossa. Mandibular protrusion led to an increasing in the number of replicating cells in the TMJ. In conclusion, the results showed that functional appliances can enhance growth of condyle and bone adaptation of glenoid fossa.

However, Katsavrias and Voudouris (8) studied the treatment effects of mandibular protrusive appliances on glenoid fossa in treated patients with skeletal Class II malocclusions by using lateral tomograms. They concluded that the glenoid fossa did not show any change in morphology radiographically, contrary to the animal research and magnetic resonance findings (85), the glenoid fossa did not appear radiographically to contribute positive growth modification to the Class II correction by active bone remodeling.

The influence on anterior guidance and condylar guidance

It has been reported that the functional appliances could effect on maxillary incisors inclination and articular eminence morphology. Therefore, anterior guidance should be changed when the incisors were retraced and condylar guidance might be altered by functional appliances treatment.

Katsavrias (5) studied the effect of mandibular protrusive (Activator) appliances on articular eminence morphology in treated patients with skeletal Class II malocclusions by using lateral tomograms for the 0.72-2 years (mean 1.33 years) of treatment period. He found that the eminence height was unchanged after treated and the eminence inclination was trend decreased toward 2-4 degrees comparing with dried skull study. There was a 10 degrees reduction between the edge of 7 and 15

years, i.e. or 1.25 degrees increased per year. He concluded that the height of the articular eminence was not affected by using of mandibular protrusion appliances and inclination of the articular eminence changed slightly as a result of using mandibular protrusion appliances (Fig.14).

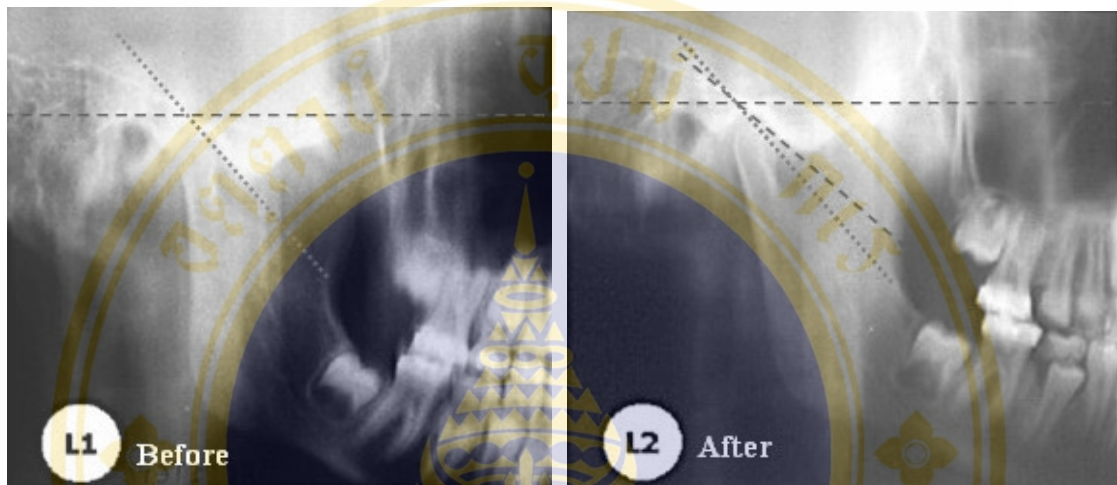


Fig.14 Lateral cephalograms of before and after treatment, on the right side, showing the decreasing of articular eminence inclination after treatment

Brikebæk et. al. (9) studied effects of Activator in TMJ alteration by laminagraphy method. They inserted metallic implant in upper and lower jaws in 23 children, 15 boys and 8 girls. They found that a major path of Activator effects could be attributed to an anterior displacement of mandible caused by an increase in the amount and direction of condylar growth as well as to a remodeling of articular fossa. The articular fossa and tuber were displaced slightly forward and vertical (0.6 mm.). The anterior slope was unchanged.

CHAPTER IV

MATERIALS AND METHODS

Materials

This study was analytical retrospective study by document review.

The subjects were from the Orthodontic department, faculty of Dentistry, Mahidol University. The chronologic ages at pre-treatment ranged from 8 to 14 years. Hand-wrist radiograph showed stages ranged from MP3-F stage to MP3-G stage or the cervical vertebrae maturation indices (CMVI) showed stages ranged from CVMI-1 to CVMI-3 (Fig.15) indicated that were in the acceleration or peak phase of the pubertal growth spurt and represented appropriate stage to begin functional jaw orthopedics (86-90).

All of them were Class II division 1 malocclusions. The samples showed Class II skeletal pattern ($ANB \geq 4^\circ$, $AO-BO \geq -1$ mm.) (91) with retrognathic mandible ($SNB \leq 78^\circ$) (92), hypodivergent or normodivergent ($SN-MP$ angle $< 38^\circ$) (93), Class II molar relationship with at least half a cusp width distal molar relationship on pre-treatment, proclination of the upper incisors ($U1axis-NA > 20^\circ$), overjet greater than 5 mm. and overbite greater than 3 mm., no major space discrepancies, no sign of TMJ disorder symptoms, no history of previous orthodontic treatment and no significant or adverse medical history (Fig.15).

The duration of treatment time ranged from 6-14 months or until the overjet was reduced, Class I or Class III dental arch relationships established and the soft tissue profile became orthodontically acceptable (Fig.22). The control group satisfied the above criteria.

Studied subjects were treated with Activator or Twinblock appliances (Fig.16) that had a moderate construction bite thickness of 5-8 mm. vertically with 5-10 mm. of mandibular advancement. Patients were instructed to wear the appliances for at least 12-24 hours a day (77), during sleep as well as during daytime.

The materials comprised of lateral cephalometric radiographs. The radiographs were taken before treatment and 6-12 months in functional appliances treatment period.

They were good quality radiographs and sufficient to allow landmark identification, especially the slope of the articular eminence and the lingual surface of maxillary central incisors. The x-ray machines that produced the cephalometric radiographs were set according to the followings. Distance from the x-ray focus tube to the film was 60 inches (5 feet) and distance from mid sagittal plane of head to the film was 15 cm.. Each subject's head was fixed in the upright position with the cephalostat during x-ray exposure.





Fig.15 Class II division 1 malocclusions, mandibular retrognathism, maxillary incisors proclination, large overjet and overbite. Hand-wrist radiograph showed MP3-FG stage, cervical vertebrae maturation indices showed CVMI-2 stage

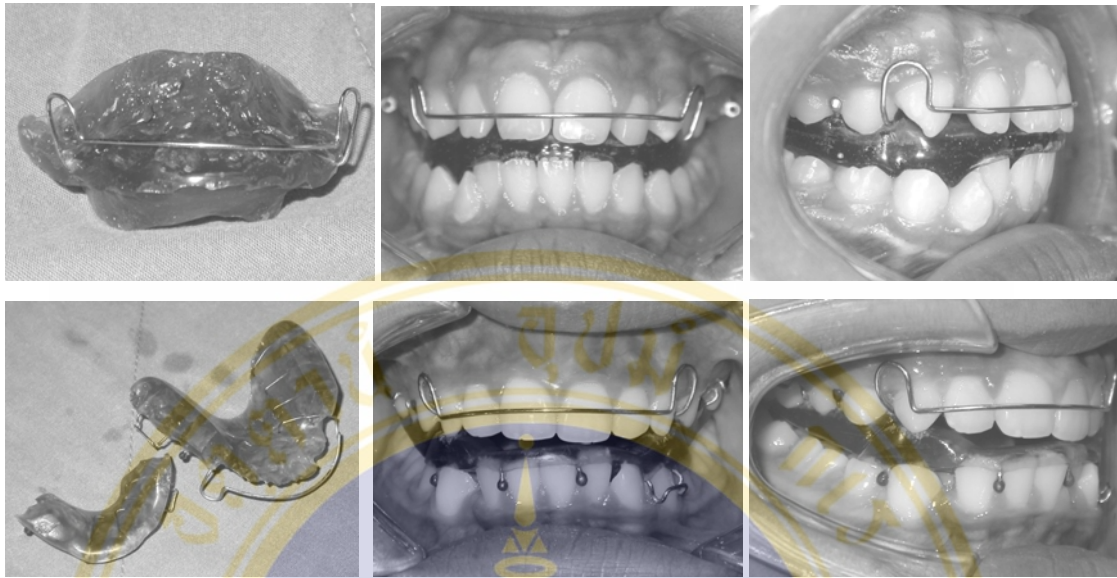


Fig.16 Upper, Activator appliance. Lower, Twin block appliance


Sample size

For assessment of the sample sizes, the following formula was used for the calculation (94): $\{(Z_{\alpha} + Z_{\beta})^2 \times \sigma^2\} / d^2$, d was the expected difference value condylar guidance angle between pre- and post-treatment from previous studied ($d \approx 3$) (5), α was the acceptable risk of a false positive finding ($\alpha = 0.05$, $Z_{\alpha} = 1.96$), β was the acceptable risk of a false negative finding ($\beta = 0.2$, $Z_{\beta} = 0.84$), σ was the standard deviation of the condylar guidance angle in Class II skeletal from previous studied ($\sigma = 6.42$) (41). From this calculation the samples should be approximate 40 subjects.

Of the original 75 patients in the parent samples, 12 patients were excluded. Five patients had insufficient treatment time (< 6 months) and the treatment outcomes were not in criteria (Class I molar), 7 patients had inadequately quality of radiographs such as landmark not clearly identified. Consequently, the final samples comprised of 63 subjects, divided to the treatment group (51 subjects) and control group (12 subjects) (Table 3). All of subgroups were matched in the criteria of this study.

Table 3 Sample size description

Group	n	Male	Female
Activator	38	15	23
Twinblock	13	6	7
Controls	12	4	8
	<u>63</u>	<u>25</u>	<u>38</u>



Methods

A hundred and twenty six lateral cephalometric radiographs were traced on a 0.003 inch acetate paper with a 0.3 mm. black pencil. A clear smooth light viewing box in dim environment was used. A black surround was placed on the radiograph to cut down background illumination (mask film) to facilitate landmark identification (95, 96). The location of each landmark was indicated by a single fine pencil dot (Fig.17).

All radiographs were traced and measured by one investigator (95). The accuracy of landmark anatomy identification and references point identification were checked by second and third investigators (97) (Professor Chainut Chongruk and Associate Professor Jiraporn Chaiwat, respectively). The tracing were digitized and analyzed using Dentofacial Planner version 5.3.2 (Dentofacial Software Inc, Toronto, Canada).

Post-treatment cephalograms were superimposed on pre-treatment films, using sella-nasion as a reference line. A linear measurement analysis was based on a reference system consisting of a horizontal plane (HP plane) and a vertical reference plane (Ptv plane) (98, 99). Both horizontal and vertical planes created a coordinate system into which all cephalometric landmarks located as X and Y values. In addition, palatal and mandibular planes were used to measure a vertical eruption of molars and incisors.

Tracing Method of Condylar Guidance and Anterior Guidance

Articular fossa region was traced backward from zygomatic arch though articular eminence and upper path of mandibular fossa (100). When bilateral structures gave rise to double images, average outline was used. As angulations of the left and right articular eminence was not significant difference (37). The clearer side was selected for tracing in order to minimize error from averaging. It must be noted that the slope and form of the tubercle at the root of the zygoma could be easily mistaken for the articular eminence. In all of the cases studied, the slope of the articular eminences were more horizontal and gentle in form than the more vertical and abrupt forms of the tubercle.

The curvature of the articular eminence was traced twice for each patient at separate times. Condylar guidance was a line drawn tangent to the long posterior slope of the articular eminence. These tracings were often the same, but where an unsolved

difference between the two tracings existed, an average of the two curvatures was used. In 5 cases angle of the articular eminence slope varied between tracings, but never by more than 3 degrees.

Palatal slope of the upper central incisor was traced on the more palatal tooth, which provided anterior guidance for the lower anterior teeth (Fig.17) (41).

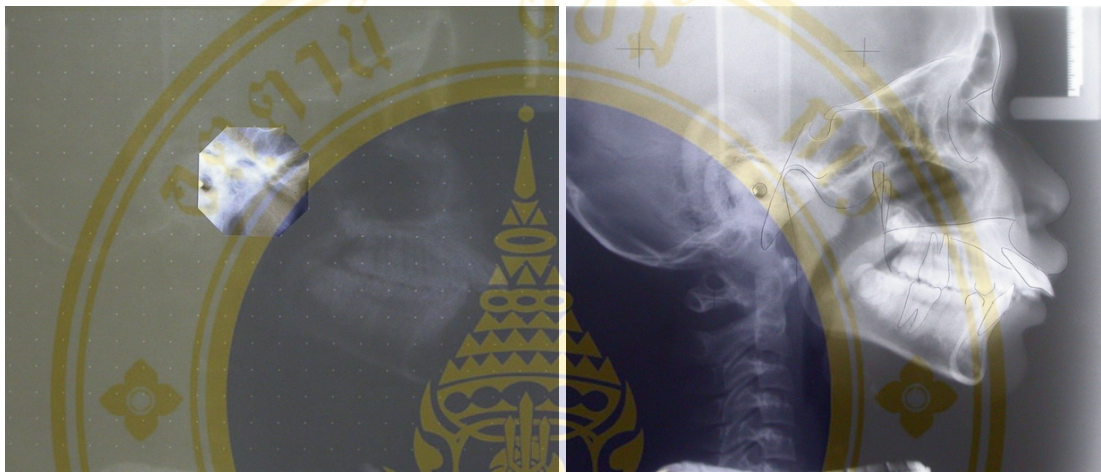

Fig.17 Left, mask film. Right, traced lateral cephalometric radiograph

Magnification of Lateral Cephalometric Radiographs

All radiographs used in this study were taken by x-ray machines in faculty of dentistry, Mahidol University. Which were set in the same conditions (distance between the machine, film and subject). There were no significant differences of the magnification between the x-ray machines. Because the magnification were controlled by using the same distance from the x-ray focus tube to the film and the same distance from mid-sagittal plane of head to the film (101).

Pilot study showed average linear magnification measurement produced by 3 x-ray machines in faculty of dentistry Mahidol University was 11.30% in the median plane (Asahi 11.24%, Trophy 11.33%, Planmeca 11.33%). To convert life size, these measurements were multiplied by correction factors (0.885).

Error of Method

Prior to actual recording of the measurements, reliability of measurements were determined. To assess the error of reference points locating and digitizing procedure, 20 randomly selected cephalograms were re-traced and re-measured after 1 month by same examiner. To control the systematic error, the radiographs from same patients (pre and pos-treatment) were randomly selected for tracing (blind experimental) in the same occasion (95).

Paired t-test was used for calculating systematic error and Dahlberg's formula (102) was used for calculating method error (ME): $ME^2 = \sum d^2 / 2n$ (d, the difference between two measurements of a pair and n, the number of subjects) (95, 97). The results showed that casual errors of method did not exceed 0.8° or 0.6 mm.. Paired t-tests demonstrated no significant systematic error differences for all measurements (Table 8).

Reference Points, Planes, Lines and Measurements

Reference Point Used in Study (Fig.18) (96, 100):

1. Sella (S), center of the fossa of sphenoid bone as seen in lateral cephalometric radiograph.
2. Construction sella (S'), point locate at the horizontal coordinate of sella 7° from the line S to N.
3. Nasion (N), the most anterior point of the frontonasal suture in the midsagittal plane.
4. Porion (Po), the most superiorly positioned point of external auditory meatus.
5. Orbitale (Or), the lowest point on the inferior rim of orbit.
6. Basion (Ba), the most inferior point on anterior margin of foramen magnum.
7. Anterior nasal spine (ANS), the anterior tip of sharp bony process of maxilla at the lower margin of the anterior nasal opening.
8. Posterior nasal spine (PNS), the posterior spine of palatine bone constituting hard palate.
9. Pterygoid point (Pt), the junction of ptergomaxillary fissure and foramen rotundum or at eleven o'clock position of mid-planed contour of ptergo-maxillary fissure (98).
10. Point A (A), the deepest midline point in the curve body outline from base to alveolar process of maxilla.
11. Point B (B), the most posterior point in the outer contour of mandibular alveolar process, in median plane.
12. Point Pm (Pm), a point on chin contour between point B and Pg.
13. Pogonion (Pg), the most anterior point on bony chin.
14. Gnathion (Gn), the most antero-inferior point on bony chin, located by bisecting mandibular and facial planes.
15. Menton (Me), the lowest point of symphysis of mandible in the midsagittal plane.
16. Gonion (Go), a mid-planed point at gonial angle of mandible located by bisecting the posterior and inferior borders of mandible.
17. Articulare (Ar), the point at the junction of posterior border of ramus and inferior border of posterior cranial base.

18. Condylion (Co), the most posterior-superior point of mid-planed contour of mandibular condyle.

19. Sigmoid, a landmark at the depth of the concavity of mandibular sigmoid notch.

20. Anterior ramus, a landmark located in the depth of the concavity of anterior border of the ramus of mandible.

21. Posterior ramus, a mid-planed point on the posterior border of ramus, approximately halfway between Go and Ar.

22. Inferior gonion, a mid-planed point at the tangent to inferior border of mandible near Go.

23. DC point (DC), the point in the center of neck of condyle where N-Ba plane crosses (98).

24. Xi point (Xi), the geometric center of the ramus of mandible (98).

25. Upper incision tip (U1tip), the midpoint of incisal edge of the more palatal maxillary central incisor

26. Lower incision tip (L1tip), the midpoint of incisal edge of the most protruded mandibular central incisor.

27. Upper incision apex (U1apex), the most apical point on root of the more palatal maxillary central incisor.

28. Lower incision apex (L1apex), the most apical point on root of the most protruded mandibular central incisor.

29. Mesiobuccal cusp of the upper first molar (U6), a point on tip of the mesiobuccal cusp of upper first permanent molar.

30. Mesiobuccal cusp of the lower first molar (L6), a point on the tip of the mesiobuccal cusp of lower first permanent molar.

31. Premolar average (Avg4), a constructed landmark which represents the average of upper first premolar cusp tip and lower first premolar cusp tip.

32. Mf point (Mf), the highest point of mandibular fossa (8).

33. Ae point (Ae), the most inferior point of articular eminence (9).

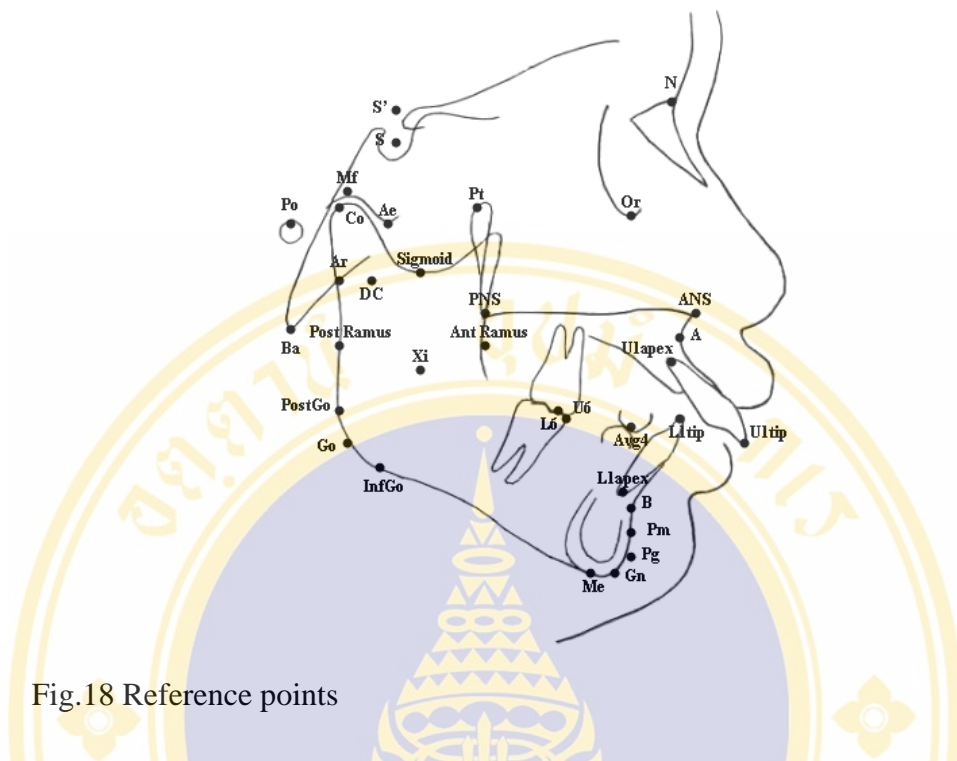


Fig.18 Reference points

Reference Planes and Lines Used in Study (Fig.19) (96):

1. Sella-nasion plane (S-N), plane extending from S to N (103, 104).
2. Horizontal plane (HP), which is surrogate Frankfort horizontal plane, constructed by drawing a line 7° from S to N line. Most measurements will be made from projections either parallel to HP or perpendicular to HP (99). Plane extending from S' to N.
3. Frankfort horizontal plane (FH), plane extending from Po to Or (98, 105).
4. Palatal plane (PP), plane extending from ANS to PNS.
5. Function occlusal plane (OP), plane extending from average point of U6 and L6 to Avg4.
6. Mandibular plane (MP), plane extending from Me to Go.
7. N-A plane (N-A), plane extending from Na to A.
8. N-B plane (N-B), plane extending from N to B.
9. N-Pg plane (N-Pg), plane extending from N to Pg.
10. Pterygoid vertical (Ptv), A vertical line drawn through Pt and perpendicular to HP (98, 106, 107).
11. S-Gn plane, plane extending from S to Gn.
12. Ramus plane, plane extending from Ar to Go.

13. Condylar axis (Cd-axis), line extending from DC to Xi.

14. Long axis of the maxillary central incisor (U1axis), line extending from U1tip to U1apex.

15. Long axis of the mandibular central incisor (L1axis), line extending from L1tip to L1apex.

16. Condylar guidance (CG), the line tangent and best fit to slope of articular eminence (25, 41, 44).

17. Anterior guidance (AG), the line tangent to palatal slope of upper central incisor (24, 41).




Fig.19 Reference planes and lines used in study

Anterior Guidance and Condylar Guidance Measurements

Angle measurements (in degrees) (Fig.20)

1. Anterior guidance angle (AG-FH), anteriorly angle between slope of anterior guidance to FH plane.

2. Condylar guidance angle (CG-FH), anteriorly angle between condylar guidance to FH plane.

3. AG-CG difference (AG-CG), the different angle between anterior guidance angle and condylar guidance angles.

Skeletal Measurements

Horizontal angle measurements (in degrees) (Fig.20)

1. Anteroposterior maxilla position to anterior cranial base (SNA), posteriorly angle between S-N plane and N-A plane (104).
2. Anteroposterior mandible position to anterior cranial base (SNB), posteriorly angle between S-N plane and N-B plane (104).
3. Anteroposterior chin position to anterior cranial base (SNPg), posteriorly angle between S-N plane and N-Pg plane (104).
4. Anteroposterior relation of maxilla and mandible (ANB), the different angle between N-A plane and N-B plane (104).
5. Cd axis-FH, angle between Frankfort horizontal plane and condylar axis, anteriorly.
6. Y-axis, acute angle formed by the intersection of S-Gn line and S-N plane (105).
7. Gonial angle, angle between ramus plane and mandibular plane.

Horizontal linear measurements (in millimeters) (Fig.21)

1. Wits appraisal, distance from perpendicular lines dropped from point A and point B onto OP plane (108).
2. A-Ptv, distance from point A to Ptv plane parallel to FH plane.
3. B-Ptv, distance from point B to Ptv plane parallel to FH plane.
4. Pg-Ptv, distance from point Pg to Ptv plane parallel to FH plane.
5. Mandibular length (Co-Gn), distance from Co to Gn (109).
6. Maxillary length (Co-A), distance from Co to point A (109).

Vertical angle measurements (in degrees) (Fig.20)

1. SN-FH, angle between S-N plane and FH plane.
2. SN-PP, angle between S-N plane and PP plane.
3. SN-MP, angle between S-N plane and MP plane.
4. MP-PP, angle between MP plane and PP plane.
5. SN-OP, angle between S-N plane and OP plane.

Vertical linear measurements (in millimeters) (Fig.20)

1. Posterior facial height (Go-S), distance from point S to point Go
2. Total anterior facial height (Me-HP), distance from point Me to HP plane.
3. Upper anterior facial height (ANS-HP), distance from point ANS to HP plane.
4. Lower anterior facial height (ANS-Me), distance from point ANS to Me perpendicular to FH plane.
5. PFH/AFH, the ratio between posterior facial height and anterior facial height.
6. LAFH/AFH, the ratio between lower anterior facial height and total anterior facial height.

Condyle and Glenoid Fossa Position Measurements

Horizontal linear measurements (in millimeters) (Fig.21)

1. Mf-Ptv, distance from point Mf to Ptv plane parallel to FH plane.
2. Ae-Ptv, distance from point Ae to Ptv plane parallel to FH plane.
3. Co-Ptv, distance from point Co to Ptv plane parallel to FH plane.
4. Ar-Ptv, distance from point Ar to Ptv plane parallel to FH plane.
5. DC-Ptv, distance from point DC to Ptv plane parallel to FH plane.

Vertical linear measurements (in millimeters) (Fig.20)

1. Mf-HP, distance from point Mf to HP plane perpendicular to FH plane.
2. Ae-HP, distance from point Ae to HP plane perpendicular to FH plane.
3. Co-HP, distance from point Co to HP plane perpendicular to FH plane.
4. Ar-HP, distance from point Ar to HP plane perpendicular to FH plane.
5. DC-HP, distance from point DC to HP plane perpendicular to FH plane.

Dento-alveolar Measurements

Angle measurements (in degrees) (Fig.20)

1. U1axis-FH, angle between U1axis to FH plane.
2. U1axis-PP, angle between U1axis to palatal plane.
3. U1axis-NA, angle between U1axis to N-A plane.
4. U1axis-AG, angle between U1axis to anterior guidance plane.
5. L1axis-MP, angle between L1axis to MP plane.

6. Interincisal angle (U1-L1), angle between U1axis and L1axis.

Horizontal linear measurements (in millimeters) (Fig.21)

1. U1-Ptv, distance from U1tip to Ptv plane parallel to FH plane.
2. U6-Ptv, distance from U6 to Ptv plane parallel to FH plane.
3. L1-Ptv, distance from L1tip to Ptv plane parallel to FH plane.
4. L6-Ptv, distance from L6 to Ptv plane parallel to FH plane.
5. Overjet, distance of perpendicular lines dropped from point U1tip and point L1tip onto FH plane.

Vertical linear measurements (in millimeters) (Fig.20)

1. U1- PP, distance from point U1tip to HP plane perpendicular to PP plane.
2. U6- PP, distance from point U6 to HP plane perpendicular to PP plane.
3. L1- MP, distance from point L1tip to HP plane perpendicular to MP plane.
4. L6- MP, distance from point L6 to HP plane perpendicular to MP plane.
5. Overbite, distance from point U1tip and point L1tip perpendicular to FH plane.

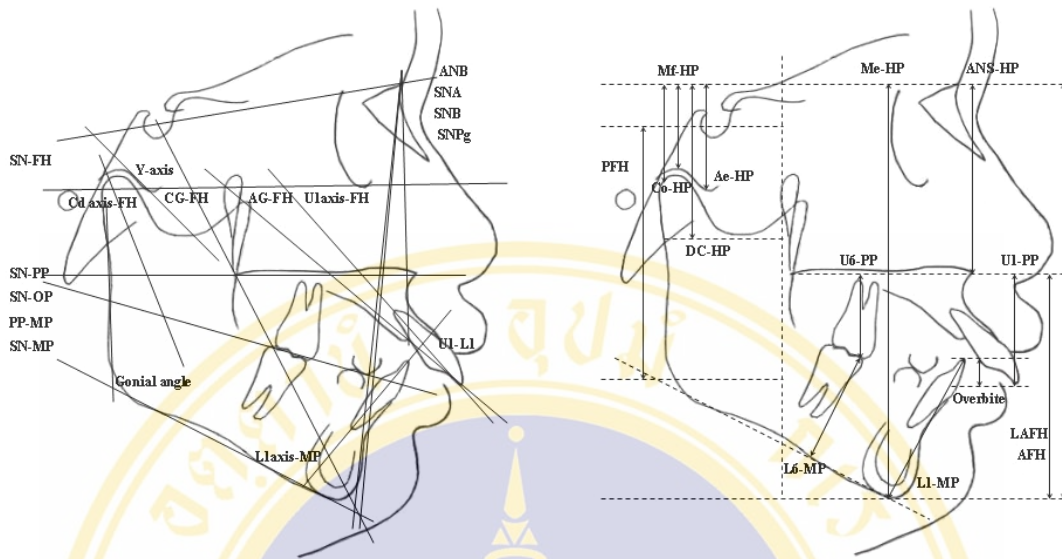


Fig.20 Right, angle measurements. Left, vertical linear measurements




Fig.21 Horizontal linear measurements

Null Hypothesis

1. There is no statistical difference of anterior guidance and condylar guidance between pre- and post- Activator and Twinblock therapy.
2. There is no statistical difference of craniofacial morphology between pre- and post- Activator and Twinblock therapy.
3. There is no statistical correlation between anterior guidance and condylar guidance in pre- and post- Activator and Twinblock therapy.

Statistical Analysis

All statistical analyses were performed with the SPSS version 11.5 (SPSS Science, Chicago). Means and standard deviations in each measurement were calculated. The groups were found to conform to a normal distribution. The differences of sexual dimorphism and post-treatment cephalometric measurements between 2 groups (Activator, Twinblock) were compared by using independent sample t-test. Pre-treatment cephalometric measurements of 3 groups (Activator, Twin block and control) were compared by using one-way analysis of variance (one-way ANOVA). Scheffe test was used to identify which groups were different. The changes over treatment and observation period were compared by using paired t-test. The relationships of anterior guidance, condylar guidance and other variables were found out by using Pearson's product moment correlation analysis.

CHAPTER V

RESULTS

Overall comparison of the pre-treatment forms of the 3 groups (Activator, Twin block and control) showed a high level of similarity, with only 1 of 53 variables showing statistical differences (Table 4). The comparison of the post-treatment forms of the treatment groups (Activator, Twin block) showed only 6 of 53 variables statistical differences (Table 5), according to type of appliances. In addition, mean cephalometric values for the 3 groups (Activator, Twin block and control) at pre-treatment and post-treatment also showed only 8 of 53 variables statistical differences according to sex (Table 6, 7). All of the differences variables were not the main important objectives of this study, so the appliances and the sex were combined and evaluated together.

For evaluation of the errors of the reference points locating and digitizing procedure, the result showed that the method error of the measurement less than 1 mm. ranged from 0.30-0.64 mm. for linear measurements and less than 1° (0.30°-0.44°) for angular measurements. Paired t-tests demonstrated no statistically significant systematic error differences for all measurements. Correlation analysis showed high significant correlation of the first and second measurements, r-value ranged form 0.89-0.99 (Table 8).

The results were divided into 3 parts, 1) common characteristic and all measurements of samples, 2) change from pre-treatment to post-treatment, 3) correlation between anterior guidance, condylar guidance and skeleto-dental relationship, respectively.

Table 4 Comparison of pre-treatment form of Activator, Twinblock and control groups

Measures		Activator (n=38)		Twinblock (n=13)		Control (n=12)		ANOVA Sig.
		Mean	SD	Mean	SD	Mean	SD	
Age	(years)	10.34	1.51	11.24	1.25	10.65	1.23	NS
Treatment time	(months)	10.58	2.60	9.85	6.20	10.58	2.35	NS
Anterior, condylar guidance								
AG-FH	(°)	51.53	4.55	51.85	5.97	52.05	5.63	NS
CG-FH	(°)	49.64	3.52	49.83	3.07	50.00	3.00	NS
AG-CG	(°)	1.89	5.17	2.02	4.89	2.05	5.08	NS
Skeletal horizontal								
SNA	(°)	82.40	3.40	83.40	3.24	83.68	2.22	NS
SNB	(°)	75.97	3.15	76.59	3.55	77.05	2.56	NS
SN-Pg	(°)	76.37	3.07	76.45	3.38	76.84	2.57	NS
ANB	(°)	6.43	1.54	6.82	1.55	6.66	1.07	NS
Cd axis-FH	(°)	64.25	3.01	64.02	2.65	63.91	1.74	NS
Y-axis	(°)	70.22	2.99	69.72	3.95	69.21	2.89	NS
Gonial angle	(°)	123.49	6.85	121.74	3.09	124.09	8.89	NS
Wits	(mm.)	0.51	3.13	0.31	2.38	0.93	2.91	NS
A-Ptv	(mm.)	49.13	3.03	51.75	3.71	49.83	2.66	NS
B-Ptv	(mm.)	38.29	4.57	40.99	6.19	39.44	4.28	NS
Pg-Ptv	(mm.)	37.67	5.06	39.58	6.40	37.82	4.99	NS
Co-Gn	(mm.)	107.79	5.08	109.94	5.39	106.62	4.41	NS
Co-A	(mm.)	87.11	4.17	89.28	4.34	86.79	4.26	NS
Skeletal Vertical								
SN-FH	(°)	7.33	0.66	7.44	0.64	7.01	0.32	NS
SN-PP	(°)	7.93	2.63	8.55	2.63	7.93	3.06	NS
SN-MP	(°)	35.93	5.14	35.18	4.52	36.58	6.41	NS
PP-MP	(°)	28.01	6.11	26.63	4.61	28.62	6.26	NS
SN-OP	(°)	22.84	4.24	22.61	4.88	21.31	6.03	NS
Go-S	(mm.)	71.38	5.07	72.98	4.92	69.93	4.80	NS
Me-HP	(mm.)	111.53	4.88	113.23	5.73	109.90	5.14	NS
ANS-HP	(mm.)	51.51	2.88	51.96	2.94	50.53	3.74	NS
ANS-Me	(mm.)	60.09	3.78	61.52	4.28	59.33	2.70	NS
PFH/AFH	(%)	63.99	3.55	64.44	2.49	63.67	4.05	NS
LAFH/AFH	(%)	53.86	2.06	54.08	1.70	54.02	1.88	NS

Table 4 Comparison of pre-treatment form of Activator, Twinblock and control groups (continued)

Measures		Activator (n=40)		Twinblock (n=13)		Control (n=12)		ANOVA Sig.
		Mean	SD	Mean	SD	Mean	SD	
Condyle, Glenoid fossa								
Mf-Ptv	(mm.)	30.09	2.31	30.18	2.01	28.97	2.28	NS
Ae-Ptv	(mm.)	21.62	2.27	21.65	1.99	20.51	2.30	NS
Co-Ptv	(mm.)	32.22	2.37	32.13	2.28	31.23	2.14	NS
Ar-Ptv	(mm.)	33.09	2.17	33.31	2.40	31.61	2.34	NS
DC-Ptv	(mm.)	26.66	2.14	26.95	2.72	25.29	2.13	NS
Mf-HP	(mm.)	24.14	2.31	24.22	2.50	23.28	2.45	NS
Ae-HP	(mm.)	28.92	2.22	29.05	2.34	28.04	2.39	NS
Co-HP	(mm.)	26.45	2.51	26.42	2.53	25.62	2.44	NS
Ar-HP	(mm.)	39.68	2.84	39.33	2.98	39.07	3.42	NS
Dc-HP	(mm.)	39.42	2.75	39.09	3.05	38.88	2.95	NS
Dento-alveolar								
U1axis-FH	(°)	57.44	4.73	57.42	6.37	58.09	5.47	NS
U1axis-PP	(°)	56.84	5.76	56.65	6.64	57.19	5.65	NS
U1axis-NA	(°)	38.83	5.41	31.75	5.40	31.22	5.33	NS
U1axis-AG	(°)	5.86	1.01	5.27	1.06	6.04	0.77	NS
L1axis-MP	(°)	96.58	6.65	100.08	7.37	96.82	6.24	NS
Interincisal	(°)	112.26	7.69	109.94	9.83	111.74	5.56	NS
U1-Ptv	(mm.)	56.24	4.38	59.68	6.35	57.26	3.86	NS
U6-Ptv	(mm.)	18.83	3.79	21.93	5.25	20.49	3.02	NS
L1-Ptv	(mm.)	47.72	4.66	51.86	5.77	49.24	3.52	0.029*
L6-Ptv	(mm.)	18.28	4.07	21.51	4.97	19.79	2.93	NS
Overjet	(mm.)	8.53	2.55	7.82	2.23	8.02	1.38	NS
U1-PP	(mm.)	28.38	2.84	29.35	2.56	27.83	2.04	NS
U6-PP	(mm.)	20.37	1.94	21.40	1.57	20.00	1.65	NS
L1-MP	(mm.)	41.28	2.72	42.35	2.73	41.85	2.45	NS
L6-MP	(mm.)	29.94	2.17	31.51	2.47	30.39	2.49	NS
Overbite	(mm.)	5.31	1.85	4.94	1.39	5.00	1.38	NS

Significant, * P<0.05; **P<0.01, NS = Non-significant

Table 5 Comparison of post-treatment form of Activator and Twinblock groups

Measures		Activator (n=38)		Twinblock (n=13)		T-test
		Mean	SD	Mean	SD	Sig.
Age	(years)	11.42	1.49	12.20	1.18	NS
Treatment time	(months)	10.58	2.60	9.85	2.30	NS
Anterior, condylar guidance						
AG-FH	(°)	57.80	4.13	57.10	6.09	NS
CG-FH	(°)	49.28	2.75	48.59	3.05	NS
AG-CG	(°)	8.52	4.27	8.51	4.81	NS
Skeletal horizontal						
SNA	(°)	81.84	3.33	83.35	2.93	NS
SNB	(°)	77.00	3.15	77.67	3.67	NS
SN-Pg	(°)	77.35	3.07	77.35	3.56	NS
ANB	(°)	4.84	1.57	5.69	2.06	NS
Cd axis-FH	(°)	64.61	2.85	64.45	2.92	NS
Y-axis	(°)	70.31	2.98	70.29	4.37	NS
Gonial angle	(°)	124.07	6.43	124.14	4.35	NS
Wits	(mm.)	-2.33	3.26	-3.93	2.95	NS
A-Ptv	(mm.)	49.32	3.20	52.27	3.56	NS
B-Ptv	(mm.)	40.26	4.96	42.79	6.98	NS
Pg-Ptv	(mm.)	39.72	5.50	41.24	7.24	NS
Co-Gn	(mm.)	112.15	5.47	115.02	5.52	NS
Co-A	(mm.)	87.72	4.15	90.01	4.15	NS
Skeletal Vertical						
SN-FH	(°)	7.21	0.66	7.46	0.67	NS
SN-PP	(°)	8.17	2.25	8.75	3.05	NS
SN-MP	(°)	35.93	5.11	36.48	4.81	NS
PP-MP	(°)	27.76	5.79	27.75	5.03	NS
SN-OP	(°)	23.40	4.44	25.36	5.53	NS
Go-S	(mm.)	74.74	5.15	76.26	5.65	NS
Me-HP	(mm.)	116.06	5.02	119.05	5.84	NS
ANS-HP	(mm.)	53.18	2.77	53.27	2.77	NS
ANS-Me	(mm.)	62.90	3.72	65.32	3.80	NS
PFH/AFH	(%)	64.40	3.43	64.03	2.80	NS
LAFH/AFH	(%)	54.17	1.81	55.01	1.76	NS

Table 5 Comparison of post-treatment form of Activator and Twinblock groups
(continued)

Measures	Activator (n=40)		Twinblock (n=13)		T-test
	Mean	SD	Mean	SD	Sig.
Condyle, Glenoid fossa					
Mf-Ptv (mm.)	30.30	2.40	30.18	2.41	NS
Ae-Ptv (mm.)	21.79	2.42	21.51	2.35	NS
Co-Ptv (mm.)	32.40	2.50	32.14	2.73	NS
Ar-Ptv (mm.)	33.41	2.30	33.35	2.89	NS
DC-Ptv (mm.)	27.07	2.37	26.79	3.17	NS
Mf-HP (mm.)	25.08	2.26	24.95	2.57	NS
Ae-HP (mm.)	29.76	2.26	29.48	2.51	NS
Co-HP (mm.)	27.28	2.41	27.15	2.60	NS
Ar-HP (mm.)	40.79	2.85	39.40	3.00	NS
Dc-HP (mm.)	40.23	2.58	39.38	3.12	NS
Dento-alveolar					
U1axis-FH (°)	63.38	4.53	62.78	6.45	NS
U1axis-PP (°)	62.44	5.28	61.78	7.14	NS
U1axis-NA (°)	27.56	4.61	26.42	5.18	NS
U1axis-AG (°)	5.64	0.83	5.38	1.08	NS
L1axis-MP (°)	99.54	7.28	102.51	7.63	NS
Interincisal (°)	115.13	8.04	111.55	9.29	NS
U1-Ptv (mm.)	54.90	4.58	58.38	6.00	0.034*
U6-Ptv (mm.)	19.26	4.34	22.16	4.74	0.047*
L1-Ptv (mm.)	50.83	4.77	54.84	6.20	0.019*
L6-Ptv (mm.)	22.08	4.63	26.14	5.46	0.012*
Overjet (mm.)	4.06	1.63	3.55	1.74	NS
U1-PP (mm.)	29.29	2.71	30.08	3.65	NS
U6-PP (mm.)	21.16	1.90	22.32	2.38	NS
L1-MP (mm.)	41.72	2.79	42.64	2.56	NS
L6-MP (mm.)	31.66	2.43	34.04	2.48	0.040*
Overbite (mm.)	3.19	1.38	2.18	1.15	0.022*

Significant, * P<0.05; **P<0.01, NS = Non-significant

Table 6 Comparison of pre-treatment forms of male and female groups

Measures	Male (n=25)		Female (n=38)		T-test Sig.
	Mean	SD	Mean	SD	
Age (years)	10.48	2.50	10.39	2.49	NS
Treatment time (months)	10.91	1.26	10.37	1.51	NS
Anterior, condylar guidance					NS
AG-FH (°)	51.46	4.21	51.86	5.49	NS
CG-FH (°)	49.56	2.92	49.87	3.55	NS
AG-CG (°)	1.90	4.30	1.98	5.50	NS
Skeletal horizontal					NS
SNA (°)	82.74	2.68	82.92	3.50	NS
SNB (°)	76.15	2.71	76.40	3.39	NS
SN-Pg (°)	76.28	2.71	76.61	3.21	NS
ANB (°)	6.60	1.45	6.52	1.48	NS
Cd axis-FH (°)	63.89	3.06	64.29	2.48	NS
Y-axis (°)	70.16	2.65	69.76	3.48	NS
Gonial angle (°)	124.68	6.17	122.30	6.90	NS
Wits (mm.)	0.63	2.86	0.49	2.99	NS
A-Ptv (mm.)	50.64	3.01	49.26	3.30	NS
B-Ptv (mm.)	39.59	4.58	38.72	5.18	NS
Pg-Ptv (mm.)	38.45	5.07	37.86	5.52	NS
Co-Gn (mm.)	110.68	4.77	106.26	4.50	0.000**
Co-A (mm.)	89.40	3.99	86.24	4.00	0.003**
Skeletal Vertical					
SN-FH (°)	7.41	0.60	7.22	0.62	NS
SN-PP (°)	7.81	2.73	8.21	2.67	NS
SN-MP (°)	36.54	5.05	35.47	5.35	NS
PP-MP (°)	28.73	5.74	27.26	5.86	NS
SN-OP (°)	22.48	4.64	22.51	4.81	NS
Go-S (mm.)	73.09	5.03	70.34	4.75	NS
Me-HP (mm.)	114.04	4.75	109.95	4.77	0.001**
ANS-HP (mm.)	51.99	2.81	51.04	3.18	NS
ANS-Me (mm.)	62.20	3.30	58.96	3.46	0.000**
PFH/AFH (%)	64.08	3.41	63.98	3.47	NS
LAFH/AFH (%)	54.41	1.59	53.62	2.09	NS

Table 6 Comparison of pre-treatment forms of male and female groups (continued)

Measures	Male (n=27)		Female (n=38)		T-test Sig.
	Mean	SD	Mean	SD	
Condyle, Glenoid fossa					
Mf-Ptv (mm.)	30.91	2.44	29.23	1.87	NS
Ae-Ptv (mm.)	22.50	2.29	20.69	1.90	NS
Co-Ptv (mm.)	33.06	2.57	31.32	1.85	NS
Ar-Ptv (mm.)	34.02	2.22	32.09	2.04	NS
DC-Ptv (mm.)	27.29	2.26	25.92	2.20	NS
Mf-HP (mm.)	24.08	2.35	23.93	2.40	NS
Ae-HP (mm.)	28.82	2.17	28.74	2.36	NS
Co-HP (mm.)	26.33	2.44	26.26	2.54	NS
Ar-HP (mm.)	39.97	3.05	39.18	2.87	NS
Dc-HP (mm.)	39.94	3.16	38.79	2.50	NS
Dento-alveolar					
U1axis-FH (°)	57.19	4.29	57.80	5.70	NS
U1axis-PP (°)	56.82	5.05	56.90	6.36	NS
U1axis-NA (°)	36.66	3.66	32.06	6.26	NS
U1axis-AG (°)	5.58	1.24	5.90	0.81	NS
L1axis-MP (°)	98.18	4.54	96.80	7.91	NS
Interincisal (°)	109.92	6.11	112.84	8.56	NS
U1-Ptv (mm.)	58.68	4.44	56.14	4.94	0.042*
U6-Ptv (mm.)	20.58	4.12	19.27	4.13	NS
L1-Ptv (mm.)	50.18	4.22	47.99	5.22	NS
L6-Ptv (mm.)	19.41	4.29	19.11	4.24	NS
Overjet (mm.)	8.50	2.29	8.14	2.33	NS
U1-PP (mm.)	29.51	2.21	27.79	2.73	0.011*
U6-PP (mm.)	21.44	1.78	19.90	1.66	0.001**
L1-MP (mm.)	42.84	2.33	40.80	2.58	0.002**
L6-MP (mm.)	31.05	2.00	29.89	2.46	NS
Overbite (mm.)	5.07	1.61	5.24	1.72	NS

Significant, * P<0.05; **P<0.01, NS = Non-significant

Table 7 Comparison of post-treatment forms of male and female groups in treatment groups

Measures	Male (n=21)		Female (n=30)		T-test
	Mean	SD	Mean	SD	Sig.
Age (years)	11.98	1.32	11.38	1.50	NS
Treatment time (months)	10.33	2.54	10.43	2.56	NS
Anterior, condylar guidance					NS
AG-FH (°)	57.78	3.82	57.51	5.22	NS
CG-FH (°)	49.49	2.03	48.84	3.27	NS
AG-CG (°)	8.30	3.90	8.67	4.73	NS
Skeletal horizontal					NS
SNA (°)	82.32	3.05	82.16	3.47	NS
SNB (°)	77.17	3.13	77.17	3.40	NS
SN-Pg (°)	77.34	3.05	77.36	3.29	NS
ANB (°)	5.14	1.23	5.00	2.03	NS
Cd axis-FH (°)	64.58	3.00	64.56	2.77	NS
Y-axis (°)	70.46	2.83	70.19	3.70	NS
Gonial angle (°)	124.08	3.61	124.09	7.19	NS
Wits (mm.)	-2.03	3.42	-3.23	3.05	NS
A-Ptv (mm.)	50.76	3.28	49.59	3.63	NS
B-Ptv (mm.)	41.46	5.08	40.51	5.96	NS
Pg-Ptv (mm.)	40.64	5.34	39.73	6.40	NS
Co-Gn (mm.)	115.41	5.56	111.11	4.94	0.005**
Co-A (mm.)	90.06	4.21	87.08	3.85	0.012*
Skeletal Vertical					
SN-FH (°)	7.42	0.58	7.17	0.71	NS
SN-PP (°)	8.01	2.47	8.53	2.47	NS
SN-MP (°)	35.95	3.53	36.15	5.87	NS
PP-MP (°)	27.94	4.67	27.63	6.18	NS
SN-OP (°)	22.84	5.13	24.64	4.42	NS
Go-S (mm.)	76.90	5.46	73.89	4.83	0.044*
Me-HP (mm.)	119.08	5.35	115.24	4.82	0.010*
ANS-HP (mm.)	53.65	2.88	52.89	2.65	NS
ANS-Me (mm.)	65.32	3.32	62.25	3.74	0.004**
PFH/AFH (%)	64.53	2.86	64.15	3.55	NS
LAFH/AFH (%)	54.92	1.51	54.01	1.93	NS

Table 7 Comparison of post-treatment forms of male and female groups in treatment group (continued)

Measures	Male (n=23)		Female (n=30)		T-test
	Mean	SD	Mean	SD	Sig.
Condyle, Glenoid fossa					
Mf-Ptv (mm.)	31.31	2.71	29.53	1.83	NS
Ae-Ptv (mm.)	22.90	2.60	20.88	1.84	NS
Co-Ptv (mm.)	33.46	2.97	31.55	1.85	NS
Ar-Ptv (mm.)	34.46	2.72	32.65	1.92	NS
DC-Ptv (mm.)	27.84	2.88	26.41	2.17	NS
Mf-HP (mm.)	25.19	2.50	24.94	2.22	NS
Ae-HP (mm.)	29.75	2.47	29.65	2.23	NS
Co-HP (mm.)	27.42	2.62	27.13	2.33	NS
Ar-HP (mm.)	41.12	3.19	39.96	2.67	NS
Dc-HP (mm.)	40.75	3.00	39.49	2.42	NS
Dento-alveolar					
U1axis-FH (°)	63.42	4.07	63.10	5.66	NS
U1axis-PP (°)	62.90	5.09	61.84	6.21	NS
U1axis-NA (°)	26.84	3.54	27.57	5.46	NS
U1axis-AG (°)	5.46	0.92	5.65	0.88	NS
L1axis-MP (°)	100.30	3.39	100.30	9.32	NS
Interincisal (°)	114.66	4.84	113.91	10.30	NS
U1-Ptv (mm.)	56.86	4.42	55.03	5.55	NS
U6-Ptv (mm.)	20.76	4.52	19.46	4.62	NS
L1-Ptv (mm.)	52.73	4.79	51.24	5.79	NS
L6-Ptv (mm.)	23.30	5.11	22.98	5.21	NS
Overjet (mm.)	4.13	1.54	3.79	1.75	NS
U1-PP (mm.)	30.65	2.63	28.68	2.94	0.018*
U6-PP (mm.)	22.72	2.02	20.56	1.61	0.000**
L1-MP (mm.)	43.14	2.06	41.12	2.88	0.008**
L6-MP (mm.)	32.77	2.17	31.92	2.90	NS
Overbite (mm.)	3.09	1.31	2.83	1.45	NS

Significant, * P<0.05; **P<0.01, NS = Non-significant

Table 8 The reproducibility and the method error of the measurement

Measures		Paired T-test Diff.		Sig. (T-test)	r-value	ME
		Diff	SD			
AG-FH	(°)	0.04	0.25	NS	0.98**	0.37
CG-FH	(°)	0.06	0.41	NS	0.96**	0.48
AG-CG	(°)	-0.05	0.32	NS	0.99**	0.42
SNA	(°)	-0.06	0.31	NS	0.93**	0.42
SNB	(°)	-0.06	0.25	NS	0.96**	0.37
SN-Pg	(°)	-0.04	0.17	NS	0.98**	0.32
ANB	(°)	-0.04	0.14	NS	0.97**	0.30
Cd axis-FH	(°)	0.06	0.26	NS	0.95**	0.38
Y-axis	(°)	0.06	0.18	NS	0.96**	0.33
Gonial angle	(°)	-0.14	0.35	NS	0.95**	0.46
Wits	(mm.)	-0.11	0.34	NS	0.95**	0.44
A-Ptv	(mm.)	-0.10	0.32	NS	0.95**	0.43
B-Ptv	(mm.)	0.10	0.27	NS	0.98**	0.40
Pg-Ptv	(mm.)	0.12	0.29	NS	0.98**	0.42
Co-Gn	(mm.)	-0.06	0.13	NS	0.99**	0.30
Co-A	(mm.)	-0.09	0.17	NS	0.99**	0.33
SN-FH	(°)	0.04	0.15	NS	0.95**	0.31
SN-PP	(°)	0.11	0.29	NS	0.91**	0.41
SN-MP	(°)	-0.06	0.25	NS	0.98**	0.38
PP-MP	(°)	-0.06	0.32	NS	0.98**	0.42
SN-OP	(°)	0.28	0.52	NS	0.90**	0.61
Go-S	(mm.)	-0.04	0.20	NS	0.99**	0.34
Me-HP	(mm.)	0.09	0.17	NS	0.99**	0.33
ANS-HP	(mm.)	0.07	0.18	NS	0.98**	0.33
ANS-Me	(mm.)	-0.05	0.18	NS	0.99**	0.33
PFH/AFH	(%)	-0.03	0.15	NS	0.99**	0.31
LAFH/AFH	(%)	-0.02	0.16	NS	0.98**	0.31
Mf-Ptv	(mm.)	-0.06	0.24	NS	0.96**	0.37
Ae-Ptv	(mm.)	-0.06	0.14	NS	0.93**	0.30
Co-Ptv	(mm.)	-0.09	0.19	NS	0.93**	0.34
Ar-Ptv	(mm.)	-0.06	0.20	NS	0.91**	0.35
DC-Ptv	(mm.)	-0.08	0.21	NS	0.92**	0.35
Mf-HP	(mm.)	0.05	0.27	NS	0.97**	0.39
Ae-HP	(mm.)	0.06	0.22	NS	0.98**	0.35

Table 8 The reproducibility and the method error of the measurements (continued)

Measures		Paired T-test Diff.		Sig. (T-test)	r-value	ME
		Diff	SD			
Co-HP	(mm.)	-0.06	0.28	NS	0.97**	0.39
Ar-HP	(mm.)	-0.06	0.24	NS	0.98**	0.37
DC-HP	(mm.)	-0.06	0.23	NS	0.97**	0.36
U1axis-FH	(°)	-0.11	0.34	NS	0.97**	0.34
U1axis-PP	(°)	-0.09	0.42	NS	0.96**	0.39
U1axis-NA	(°)	0.12	0.36	NS	0.94**	0.58
U1axis-AG	(°)	-0.13	0.35	NS	0.89**	0.45
L1axis-MP	(°)	0.11	0.48	NS	0.98**	0.53
Interincisal	(°)	-0.11	0.63	NS	0.95**	0.64
U1-Ptv	(mm.)	0.11	0.29	NS	0.97**	0.41
U6-Ptv	(mm.)	0.13	0.26	NS	0.98**	0.40
L1-Ptv	(mm.)	0.06	0.27	NS	0.99**	0.39
L6-Ptv	(mm.)	0.05	0.27	NS	0.99**	0.39
Overjet	(mm.)	0.05	0.20	NS	0.99**	0.34
U1-PP	(mm.)	-0.11	0.25	NS	0.94**	0.38
U6-PP	(mm.)	-0.04	0.17	NS	0.97**	0.32
L1-MP	(mm.)	-0.08	0.22	NS	0.97**	0.36
L6-MP	(mm.)	-0.05	0.18	NS	0.98**	0.33
Overbite	(mm.)	-0.04	0.24	NS	0.97**	0.36

Significant, * P<0.05; **P<0.01, $ME^2 = \sum d^2/2n$, NS= Non-significant

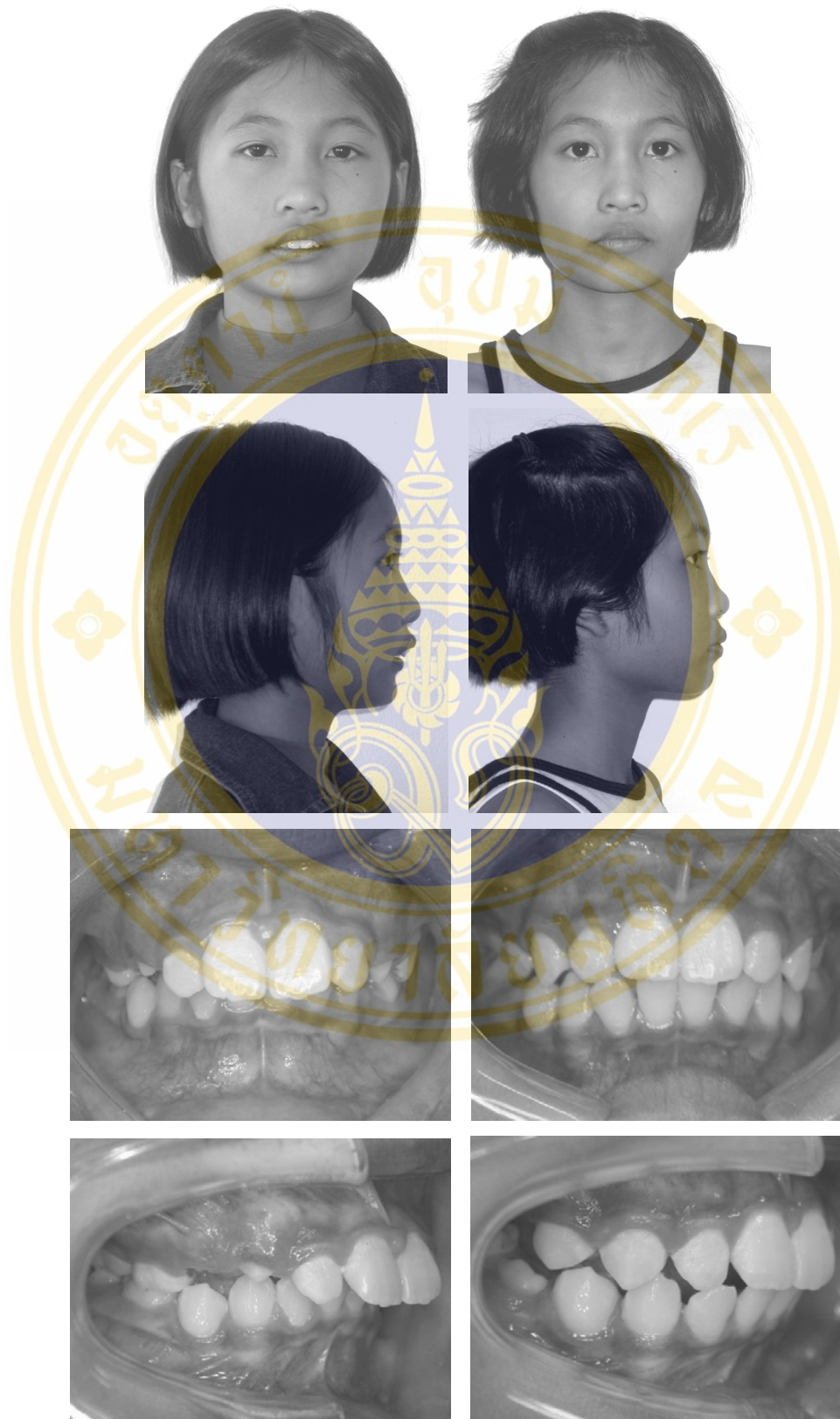


Fig.22 Treatment results, reduced overbite and overjet, Class I or Class III dental arch relationships established and the soft tissue was acceptable orthodontics profile

Common Characteristic of Samples

Common characteristic and all measurements of pooled samples presented in the table 9. Mean treatment time of the treatment group was 10.39 (SD= 2.52) months, and 10.58 (SD=2.35) months for the control group. Mean age of the treatment group was 10.57 years in pre-treatment, 11.62 years in post-treatment. While mean age of the control group was 10.65 and 11.55 years in pre- and post-treatment respectively.

Anterior Guidance and Condylar Guidance Characteristic (Fig.23)

Mean anterior guidance of the treatment group was 51.61° in pre-treatment, 57.62° in post-treatment, while mean anterior guidance of the control group was 52.05° and 50.82° in pre- and post-treatment respectively. Mean condylar guidance of the treatment group was 49.69° in pre-treatment, 49.11° in post-treatment, while mean anterior guidance of the control group was 50.00° and 50.49° in pre- and post-treatment respectively. Mean of the difference between anterior guidance and condylar guidance of the treatment group was 1.92° in pre-treatment, 8.51° in post-treatment, while mean of the difference between anterior guidance and condylar guidance of the control group was 2.05° and 0.33° in pre- and post-treatment respectively.

Sagittal Skeletal Relationship Characteristic (Fig.24)

Mean SNA of the treatment group was 82.65° in pre-treatment, 82.23° in post-treatment, while mean SNA of the control group was 83.68° and 83.58° in pre- and post-treatment respectively. Mean SNB of the treatment group was 76.13° in pre-treatment, 77.17° in post-treatment, while mean SNA of the control group was 77.05° and 77.15° in pre- and post-treatment respectively. Mean SN-Pg of the treatment group was 76.39° in pre-treatment, 77.35° in post-treatment, while mean SN-Pg of the control group was 76.84° and 77.10° in pre- and post-treatment respectively. Mean ANB of the treatment group was 6.53° in pre-treatment, 5.06° in post-treatment, while mean ANB of the control group was 6.66° and 6.45° in pre- and post-treatment respectively.

Mean Cd axis-FH of the treatment group was 64.19° in pre-treatment, 64.57° in post-treatment, while mean Cd axis-FH of the control group was 63.91° and 64.68° in pre- and post-treatment respectively. Mean Y-axis of the treatment group was 70.09°

in pre-treatment, 70.30° in post-treatment, while mean Y-axis of the control group was 69.21° and 69.36° in pre- and post-treatment respectively. Mean gonial angle of the treatment group was 123.05° in pre-treatment, 124.09° in post-treatment, while mean gonial angle of the control group was 124.09° and 123.91° in pre- and post-treatment respectively.

Mean Wits of the treatment group were 0.46 mm. in pre-treatment, -2.74 mm. in post-treatment, while mean Wits of the control group was 0.93 mm. and 1.32 mm. in pre- and post-treatment respectively. Mean distance from point A to Ptv plane (A-Ptv) of the treatment group was 49.80 mm. in pre-treatment, 50.07 mm. in post-treatment, while mean A-Ptv of the control group was 49.83 mm. and 50.43 mm. in pre- and post-treatment respectively. Mean distance from point B to Ptv plane (B-Ptv) of the treatment group was 38.98 mm. in pre-treatment, 40.90 mm. in post-treatment, while mean B-Ptv of the control group was 39.44 mm. and 40.03 mm. in pre- and post-treatment respectively. Mean distance from point Pg to Ptv plane (Pg-Ptv) of the treatment group was 38.16 mm. in pre-treatment, 40.10 mm. in post-treatment, while mean B-Ptv of the control group was 37.82 mm. and 38.68 mm. in pre- and post-treatment respectively. Mean of mandibular length (Co-Gn) of the treatment group was 108.34 mm. in pre-treatment, 112.88 mm. in post-treatment, while mean Co-Gn of the control group was 106.62 mm. and 108.92 mm. in pre- and post-treatment respectively. Mean of maxilla length (Co-A) of the treatment group was 87.66 mm. in pre-treatment, 88.30 mm. in post-treatment, while mean Co-A of the control group was 86.79 mm. and 87.93 mm. in pre- and post-treatment respectively.

Vertical Skeletal Relationship Characteristic (Fig.25)

Mean angle between Frankfort plane and SN plane (SN-FH) of the treatment group was 7.36° in pre-treatment, 7.28° in post-treatment, while mean SN-FH angle of the control group was 7.01° and 7.02° in pre- and post-treatment respectively. Mean angle between palatal plane and SN plane (SN-PP) of the treatment group was 8.08° in pre-treatment, 8.32° in post-treatment, while mean SN-PP angle of the control group was 7.93° and 8.12° in pre- and post-treatment respectively. Mean angle between mandibular plane and SN plane (SN-MP) of the treatment group was 35.74° in pre-treatment, 36.07° in post-treatment, while mean SN-MP angle of the control group

was 36.58° and 36.17° in pre- and post-treatment respectively. Mean angle between mandibular plane and Palatal plane (PP-MP) of the treatment group was 27.66° in pre-treatment, 27.76° in post-treatment, while mean PP-MP angle of the control group was 28.62° and 28.06° in pre- and post-treatment respectively. Mean angle between functional occlusal plane and SN plane (SN-OP) of the treatment group was 22.78° in pre-treatment, 23.90° in post-treatment, while mean SN-OP angle of the control group was 21.31° and 20.33° in pre- and post-treatment respectively.

Mean of posterior facial height (Go-S) of the treatment group was 71.79 mm. in pre-treatment, 75.13 mm. in post-treatment, while mean Go-S distance of the control group was 69.93 mm. and 72.33 mm. in pre- and post-treatment respectively. Mean of anterior facial height (Me-HP) of the treatment group was 111.97 mm. in pre-treatment, 116.82 mm. in post-treatment, while mean Me-HP distance of the control group was 109.90 mm. and 112.43 mm. in pre- and post-treatment respectively. Mean of upper anterior facial height (ANS-HP) of the treatment group was 51.63 mm. in pre-treatment, 53.20 mm. in post-treatment, while mean ANS-HP distance of the control group was 50.53 mm. and 51.93 mm. in pre- and post-treatment respectively. Mean of lower anterior facial height (ANS-Me) of the treatment group was 60.46 mm. in pre-treatment, 63.52 mm. in post-treatment, while mean ANS-Me distance of the control group was 59.33 mm. and 60.43 mm. in pre- and post-treatment respectively. Mean ratio between posterior facial height and anterior facial height (PFH/AFH) of the treatment group was 64.11% in pre-treatment, 64.31% in post-treatment, while mean PFH/AFH ratio of the control group was 63.67% and 64.42% in pre- and post-treatment respectively. Mean ratio between lower anterior facial height and anterior facial height (LAFH/AFH) of the treatment group was 53.92% in pre-treatment, 54.38% in post-treatment, while mean PFH/AFH ratio of the control group was 54.02% and 53.80% in pre- and post-treatment respectively.

Condyle and Glenoid Fossa Relationship Characteristic (Fig.26)

Mean distance from the highest point of mandibular fossa to Ptv plane (Mf-Ptv) of the treatment group was 30.12 mm. in pre-treatment, 30.27 mm. in post-treatment, while mean Mf-Ptv distance of the control group was 28.97 mm. and 29.29 mm. in pre- and post-treatment respectively. Mean distance from the most inferior point of articular eminence to Ptv plane (Ae-Ptv) of the treatment group was 21.26 mm. in pre-treatment, 21.72 mm. in post-treatment, while mean Ae-Ptv distance of the control group was 20.51 mm. and 20.71 mm. in pre- and post-treatment respectively. Mean distance from the most posterior-superior point of mandibular condyle to Ptv plane (Co-Ptv) of the treatment group was 32.20 mm. in pre-treatment, 32.33 mm. in post-treatment, while mean Co-Ptv distance of the control group was 31.23 mm. and 31.48 mm. in pre- and post-treatment respectively. Mean distance from the junction of the posterior ramus and the inferior cranial base to Ptv plane (Ar-Ptv) of the treatment group was 33.15 mm. in pre-treatment, 33.39 mm. in post-treatment, while mean Ar-Ptv distance of the control group was 31.61 mm. and 31.86 mm. in pre- and post-treatment respectively. Mean distance from the point in the center of the condyle to Ptv plane (DC-Ptv) of the treatment group was 26.74 mm. in pre-treatment, 27.00 mm. in post-treatment, while mean Ar-Ptv distance of the control group was 25.29 mm. and 25.47 mm. in pre- and post-treatment respectively.

Mean distance from the highest point of mandibular fossa to horizontal plane (Mf-HP) of the treatment group was 24.16 mm. in pre-treatment, 25.05 mm. in post-treatment, while mean Mf-HP distance of the control group was 23.28 mm. and 23.83 mm. in pre- and post-treatment respectively. Mean distance from the most inferior point of articular eminence to horizontal plane (Ae-HP) of the treatment group was 28.95 mm. in pre-treatment, 29.69 mm. in post-treatment, while mean Ae-HP distance of the control group was 28.04 mm. and 28.59 mm. in pre- and post-treatment respectively. Mean distance from the most posterior-superior point of the mandibular condyle to horizontal plane (Co-HP) of the treatment group was 26.44 mm. in pre-treatment, 27.25 mm. in post-treatment, while mean Co-HP distance of the control group was 25.62 mm. and 26.18 mm. in pre- and post-treatment respectively. Mean distance from the junction of the posterior ramus and the inferior cranial base to horizontal plane (Ar-HP) of the treatment group was 39.59 mm. in pre-treatment,

40.44 mm. in post-treatment, while mean Ar-HP distance of the control group was 39.07 mm. and 39.58 mm. in pre- and post-treatment respectively. Mean distance from the point in the center of the condyle to horizontal plane (Dc-HP) of the treatment group was 39.34 mm. in pre-treatment, 40.01 mm. in post-treatment, while mean Dc-HP distance of the control group was 38.88 mm. and 39.23 mm. in pre- and post-treatment respectively.

Dento-alveolar Relationship Characteristic (Fig.27)

Mean angle of upper central incisor axis related to Frankfort plane (U1axis-FH) of the treatment group was 57.43° in pre-treatment, 63.23° in post-treatment, while mean U1axis-FH angle of the control group was 58.09° and 57.04° in pre- and post-treatment respectively. Mean angle of upper central incisor axis related to palatal plane (U1axis-PP) of the treatment group was 56.79° in pre-treatment, 62.28° in post-treatment, while mean U1axis-PP angle of the control group was 57.19° and 55.93° in pre- and post-treatment respectively. Mean angle of upper central incisor axis related to N-A plane (U1axis-NA) of the treatment group was 32.55° in pre-treatment, 27.27° in post-treatment, while mean U1axis-NA angle of the control group was 31.22° and 32.36° in pre- and post-treatment respectively. Mean angle of upper central incisor axis related to anterior guidance plane (U1axis-AG) of the treatment group was 5.71° in pre-treatment, 5.57° in post-treatment, while mean U1axis-AG angle of the control group was 6.04° and 6.21° in pre- and post-treatment respectively. Mean angle of upper central incisor axis related to mandibular plane (U1axis-MP) of the treatment group was 97.47° in pre-treatment, 100.30° in post-treatment, while mean U1axis-AG angle of the control group was 96.82° and 97.55° in pre- and post-treatment respectively. Mean inter-incisal angle of the treatment group was 111.67° in pre-treatment, 114.22° in post-treatment, while mean inter-incisal angle of the control group was 111.74° and 110.33° in pre- and post-treatment respectively.

Mean distance from upper central incisor tip to Ptv plane (U1-Ptv) of the treatment group was 57.12 mm. in pre-treatment, 55.79 mm. in post-treatment, while mean U1-Ptv distance of the control group was 57.26 mm. and 58.75 mm. in pre- and post-treatment respectively. Mean distance from mesial cusp of upper first molar to Ptv plane (U6-Ptv) of the treatment group was 19.62 mm. in pre-treatment, 20.00 mm.

in post-treatment, while mean U6-Ptv distance of the control group was 20.49 mm. and 21.68 mm. in pre- and post-treatment respectively. Mean distance from lower central incisor tip to Ptv plane (L1-Ptv) of the treatment group was 48.77 mm. in pre-treatment, 51.85 mm. in post-treatment, while mean L1-Ptv distance of the control group was 49.24 mm. and 50.43 mm. in pre- and post-treatment respectively. Mean distance from mesial cusp of lower first molar to Ptv plane (L6-Ptv) of the treatment group was 19.10 mm. in pre-treatment, 23.11 mm. in post-treatment, while mean L6-Ptv distance of the control group was 19.79 mm. and 20.87 mm. in pre- and post-treatment respectively. Mean overjet of the treatment group was 8.35 mm. in pre-treatment, 3.93 mm. in post-treatment, while mean overjet of the control group was 8.02 mm. and 8.32 mm. in pre- and post-treatment respectively. Mean distance from upper central incisor tip to palatal plane (U1-PP) of the treatment group was 28.63 mm. in pre-treatment, 29.49 mm. in post-treatment, while mean U1-PP distance of the control group was 27.83 mm. and 28.05 mm. in pre- and post-treatment respectively. Mean distance from mesial cusp of upper first molar to palatal plane (U6-PP) of the treatment group was 20.63 mm. in pre-treatment, 21.45 mm. in post-treatment, while mean U6-PP distance of the control group was 20.00 mm. and 20.97 mm. in pre- and post-treatment respectively. Mean distance from lower central incisor tip to mandibular plane (L1-MP) of the treatment group was 41.56 mm. in pre-treatment, 41.95 mm. in post-treatment, while mean L1-MP distance of the control group was 41.85 mm. and 42.71 mm. in pre- and post-treatment respectively. Mean distance from mesial cusp of lower first molar to mandibular plane (L6-MP) of the treatment group was 30.34 mm. in pre-treatment, 32.37 mm. in post-treatment, while mean L6-MP distance of the control group was 30.39 mm. and 30.96 mm. in pre- and post-treatment respectively. . Mean overbite of the treatment group was 5.21 mm. in pre-treatment, 2.93 mm. in post-treatment, while mean overbite of the control group was 5.00 mm. and 4.97 mm. in pre- and post-treatment respectively.

Table 9 Common characteristic of the samples

Measures		Treatment (n=51)				Control (n=12)			
		Pre-treatment		Post-treatment		Pre-control		Post-treatment	
		Mean	SD	Mean	SD	Mean	SD	Mean	SD
Age	(years)	10.57	1.49	11.62	1.45	10.65	1.23	11.55	1.26
Anterior , condylar guidance									
AG-FH	(°)	51.61	4.89	57.62	4.65	52.05	5.63	50.82	5.56
CG-FH	(°)	49.69	3.38	49.11	2.82	50.00	3.00	50.49	3.21
AG-CG	(°)	1.92	5.05	8.51	4.37	2.05	5.08	0.33	5.28
Skeletal horizontal									
SNA	(°)	82.65	3.36	82.23	3.27	83.68	2.22	83.58	2.60
SNB	(°)	76.13	3.23	77.17	3.26	77.05	2.56	77.15	2.66
SN-Pg	(°)	76.39	3.12	77.35	3.16	76.84	2.57	77.10	2.75
ANB	(°)	6.53	1.54	5.06	1.73	6.66	1.07	6.45	1.11
Cd axis-FH	(°)	64.19	2.90	64.57	2.84	63.91	1.74	64.68	2.56
Y-axis	(°)	70.09	3.23	70.30	3.34	69.21	2.89	69.36	3.00
Gonial angle	(°)	123.05	6.13	124.09	5.93	124.09	8.89	123.91	8.90
Wits	(mm.)	0.46	2.94	-2.74	3.23	0.93	2.91	1.32	2.89
A-Ptv	(mm.)	49.80	3.38	50.07	3.51	49.83	2.66	50.43	2.99
B-Ptv	(mm.)	38.98	5.10	40.90	5.58	39.44	4.28	40.03	4.47
Pg-Ptv	(mm.)	38.16	5.43	40.10	5.95	37.82	4.99	38.68	5.20
Co-Gn	(mm.)	108.34	5.19	112.88	5.58	106.62	4.41	108.92	4.16
Co-A	(mm.)	87.66	4.28	88.30	4.23	86.79	4.26	87.93	4.02
Skeletal Vertical									
SN-FH	(°)	7.36	0.65	7.28	0.66	7.01	0.32	7.02	0.34
SN-PP	(°)	8.08	2.62	8.32	2.46	7.93	3.06	8.12	3.64
SN-MP	(°)	35.74	4.96	36.07	4.99	36.58	6.41	36.17	6.69
PP-MP	(°)	27.66	5.75	27.76	5.56	28.62	6.26	28.06	6.07
SN-OP	(°)	22.78	4.36	23.90	4.76	21.31	6.03	20.33	6.03
Go-S	(mm.)	71.79	5.03	75.13	5.26	69.93	4.80	72.33	4.81
Me-HP	(mm.)	111.97	5.11	116.82	5.35	109.90	5.14	112.43	5.44
ANS-HP	(mm.)	51.63	2.87	53.20	2.74	50.53	3.74	51.93	4.37
ANS-Me	(mm.)	60.46	3.92	63.52	3.85	59.33	2.70	60.43	2.66
PFH/AFH	(%)	64.11	3.29	64.31	3.26	63.67	4.05	64.42	4.37
LAFH/AFH	(%)	53.92	1.96	54.38	1.82	54.02	1.88	53.80	2.22

Table 9 Common characteristic of the samples (continued)

Measures		Treatment (n=51)				Control (n=12)			
		Pre-treatment		Post-treatment		Pre-control		Post-treatment	
		Mean	SD	Mean	SD	Mean	SD	Mean	SD
Condyle, Glenoid fossa									
Mf-Ptv	(mm.)	30.12	2.22	30.27	2.38	28.97	2.28	29.29	2.05
Ae-Ptv	(mm.)	21.63	2.18	21.72	2.38	20.51	2.30	20.71	2.12
Co-Ptv	(mm.)	32.20	2.33	32.33	2.53	31.23	2.14	31.48	1.73
Ar-Ptv	(mm.)	33.15	2.21	33.39	2.43	31.61	2.34	31.86	2.02
DC-Ptv	(mm.)	26.74	2.28	27.00	2.56	25.29	2.13	25.47	1.72
Mf-HP	(mm.)	24.16	2.33	25.05	2.32	23.28	2.45	23.83	2.40
Ae-HP	(mm.)	28.95	2.23	29.69	2.31	28.04	2.39	28.59	2.36
Co-HP	(mm.)	26.44	2.49	27.25	2.43	25.62	2.44	26.18	2.39
Ar-HP	(mm.)	39.59	2.85	40.44	2.92	39.07	3.42	39.58	3.48
DC-HP	(mm.)	39.34	2.80	40.01	2.72	38.88	2.95	39.23	2.83
Dento-alveolar									
U1axis-FH	(°)	57.43	5.13	63.23	5.02	58.09	5.47	57.04	5.21
U1axis-PP	(°)	56.79	5.93	62.28	5.74	57.19	5.65	55.93	5.88
U1axis-NA	(°)	32.55	5.38	27.27	4.74	31.22	5.33	32.36	5.19
U1axis-AG	(°)	5.71	1.05	5.57	0.89	6.04	0.77	6.21	0.83
L1axis-MP	(°)	97.47	6.94	100.30	7.41	96.82	6.24	97.55	6.64
Interincisal	(°)	111.67	8.24	114.22	8.43	111.74	5.56	110.33	6.07
U1-Ptv	(mm.)	57.12	5.12	55.79	5.15	57.26	3.86	58.75	3.76
U6-Ptv	(mm.)	19.62	4.37	20.00	4.58	20.49	3.02	21.68	2.59
L1-Ptv	(mm.)	48.77	5.23	51.85	5.40	49.24	3.52	50.43	3.36
L6-Ptv	(mm.)	19.10	4.50	23.11	5.12	19.79	2.93	20.87	2.76
Overjet	(mm.)	8.35	2.47	3.93	1.66	8.02	1.38	8.32	2.02
U1-PP	(mm.)	28.63	2.78	29.49	2.96	27.83	2.04	28.05	2.29
U6-PP	(mm.)	20.63	1.89	21.45	2.07	20.00	1.65	20.97	1.74
L1-MP	(mm.)	41.56	2.73	41.95	2.74	41.85	2.45	42.71	3.00
L6-MP	(mm.)	30.34	2.33	32.27	2.63	30.39	2.49	30.96	2.55
Overbite	(mm.)	5.21	1.74	2.93	1.38	5.00	1.38	4.97	1.61

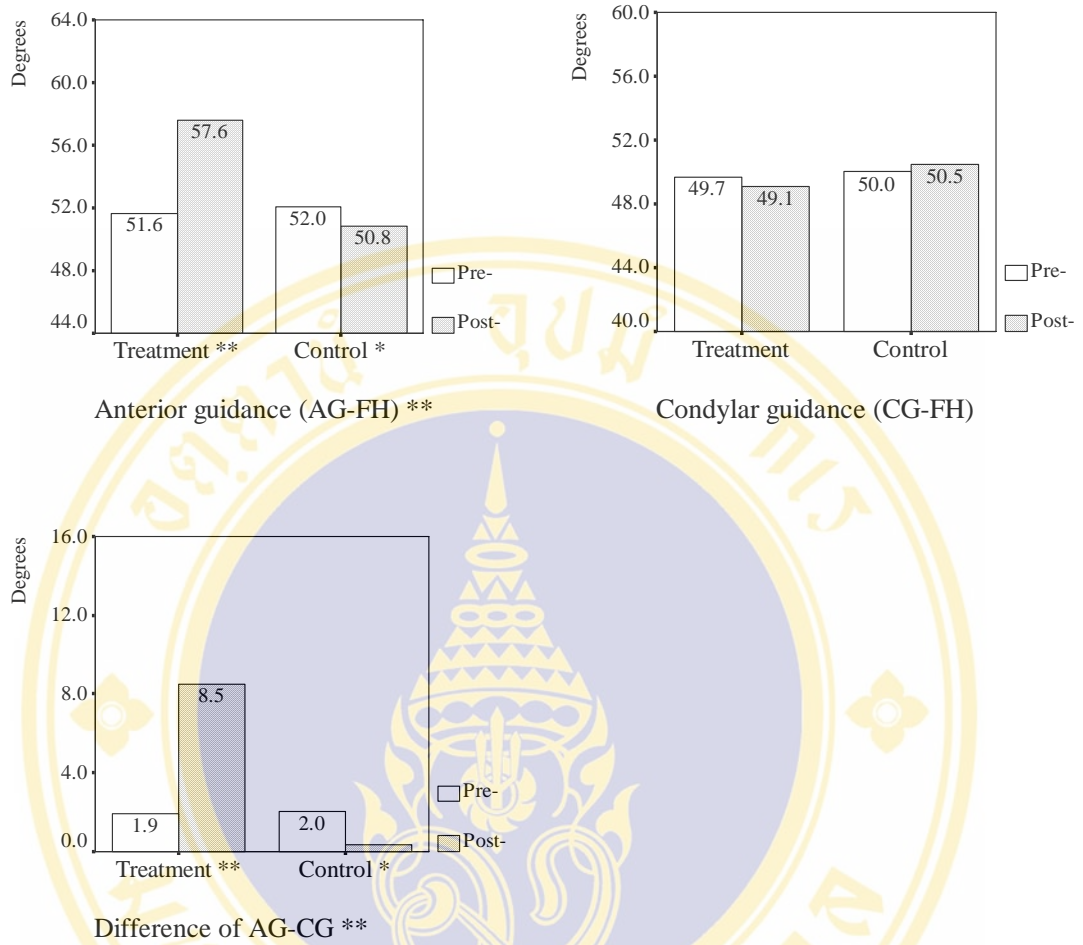
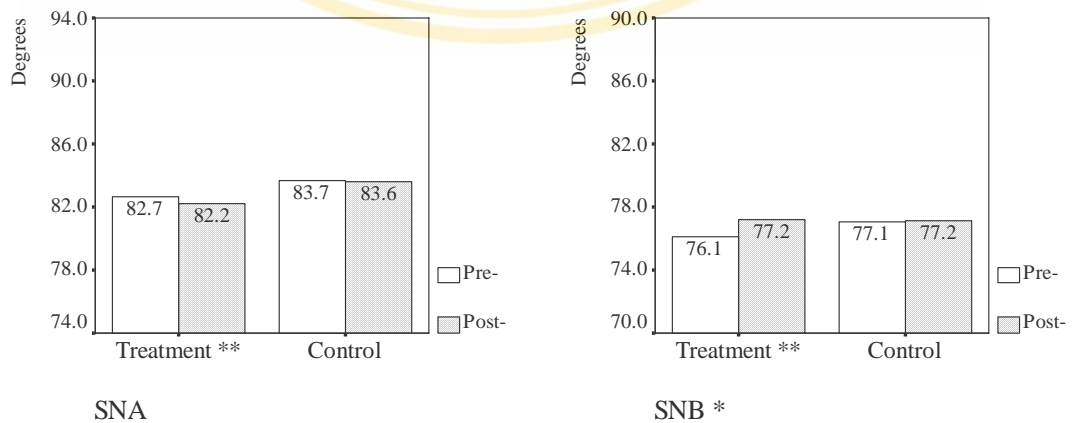
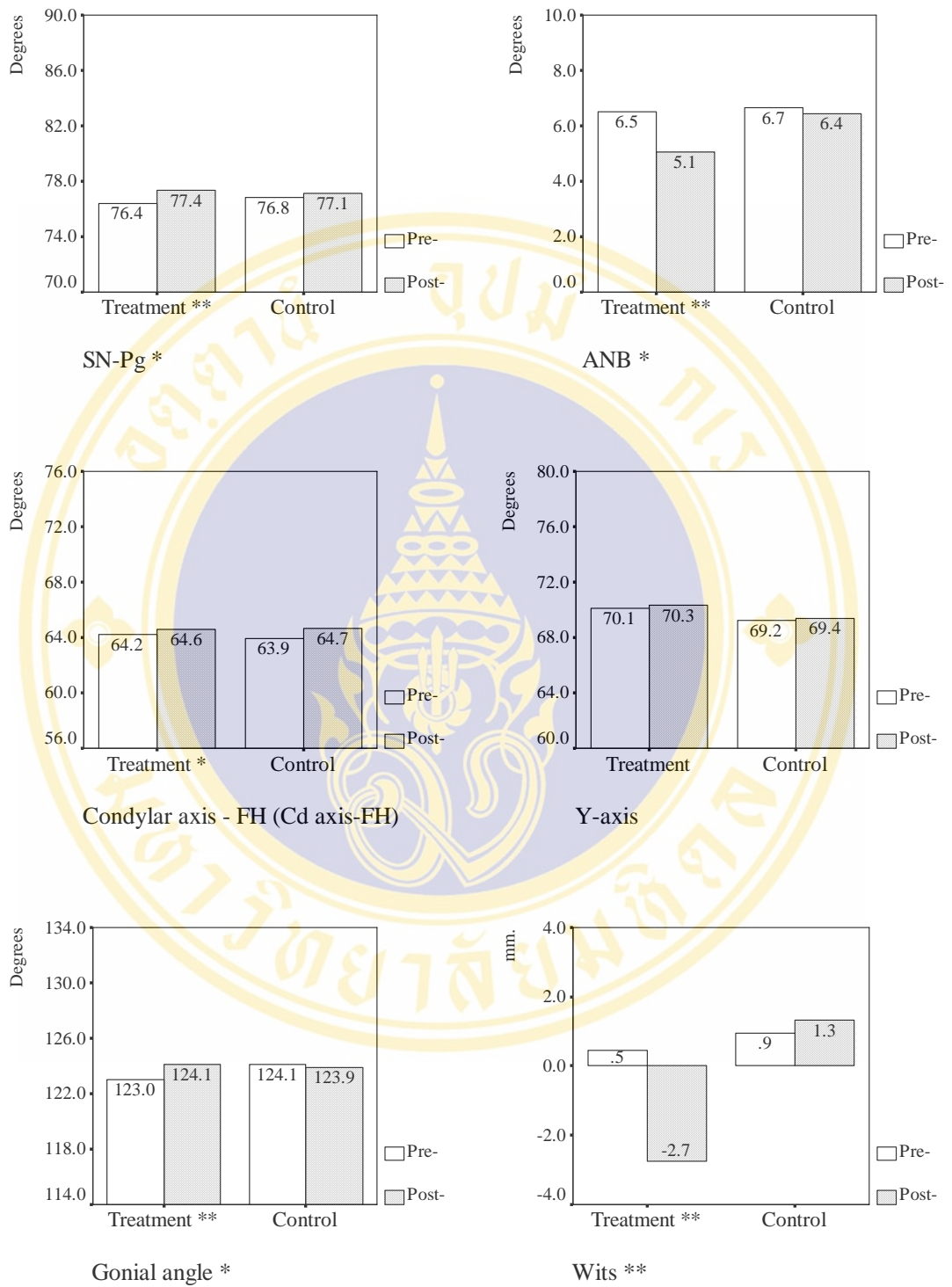


Fig.23 Graph presented Anterior and Condylar guidance measurement (*P<.05, **P<.01)





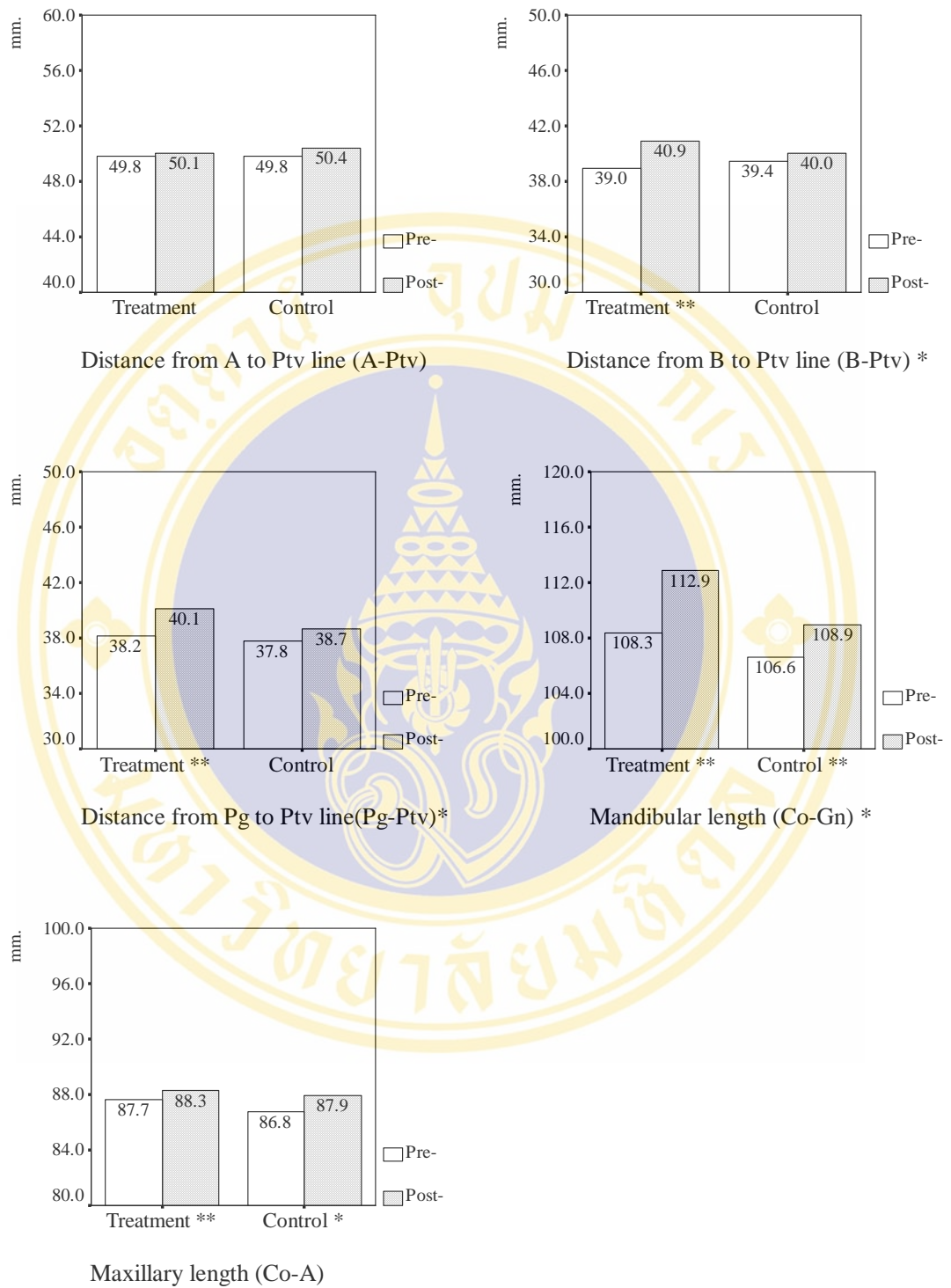
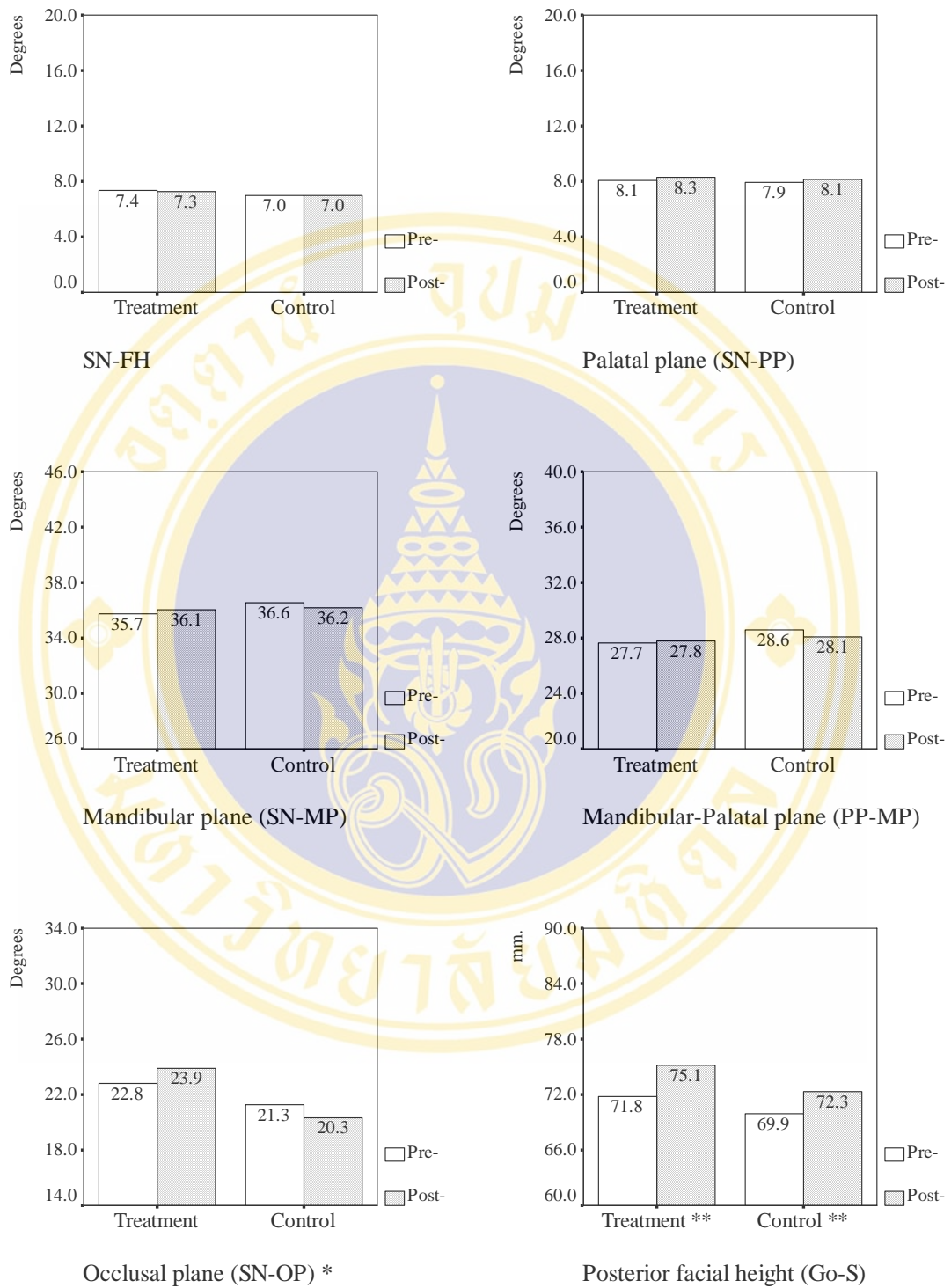


Fig.24 Graphs presented sagittal skeletal relationship measurement (*P<.05, **P<.01)



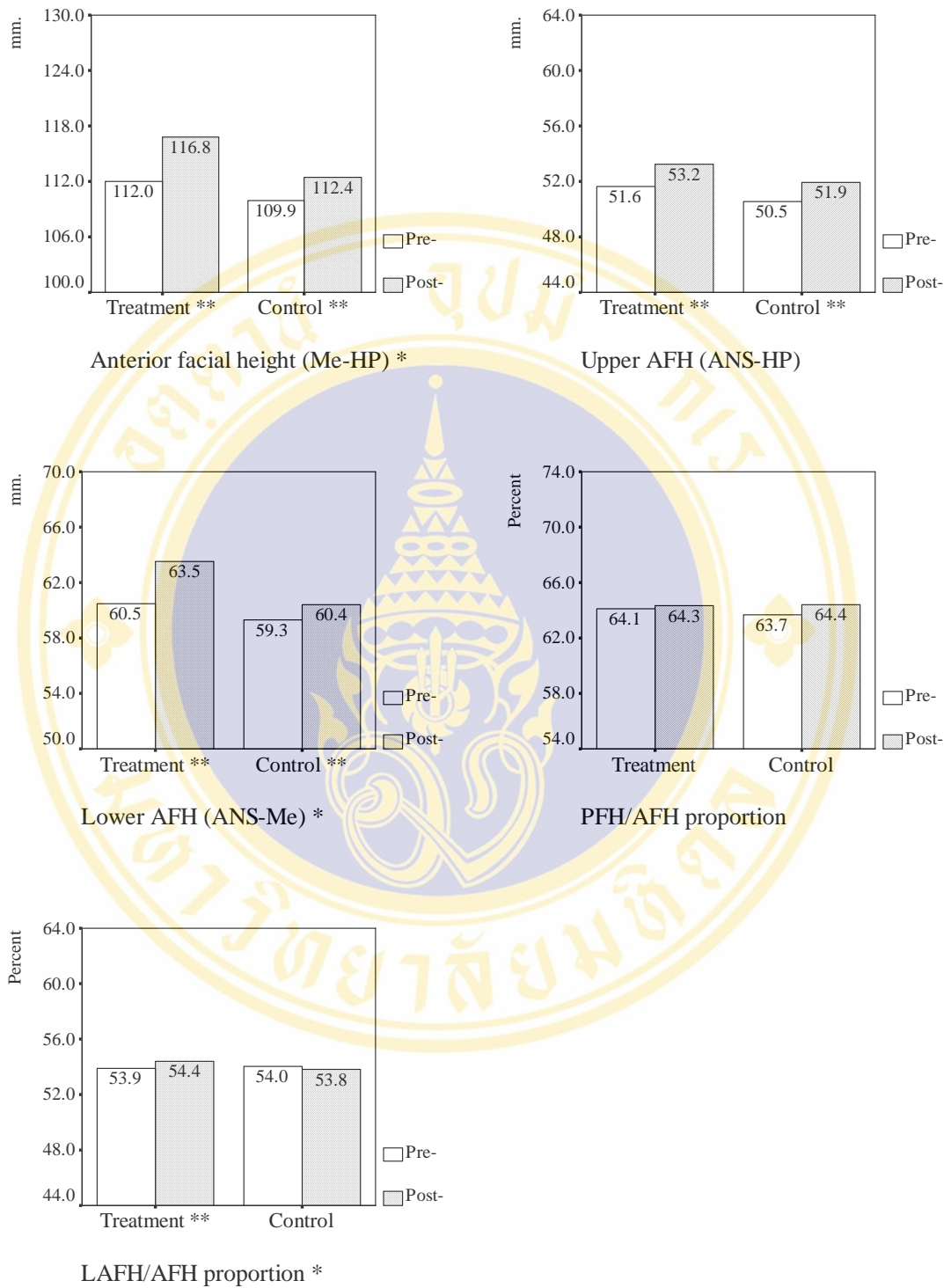
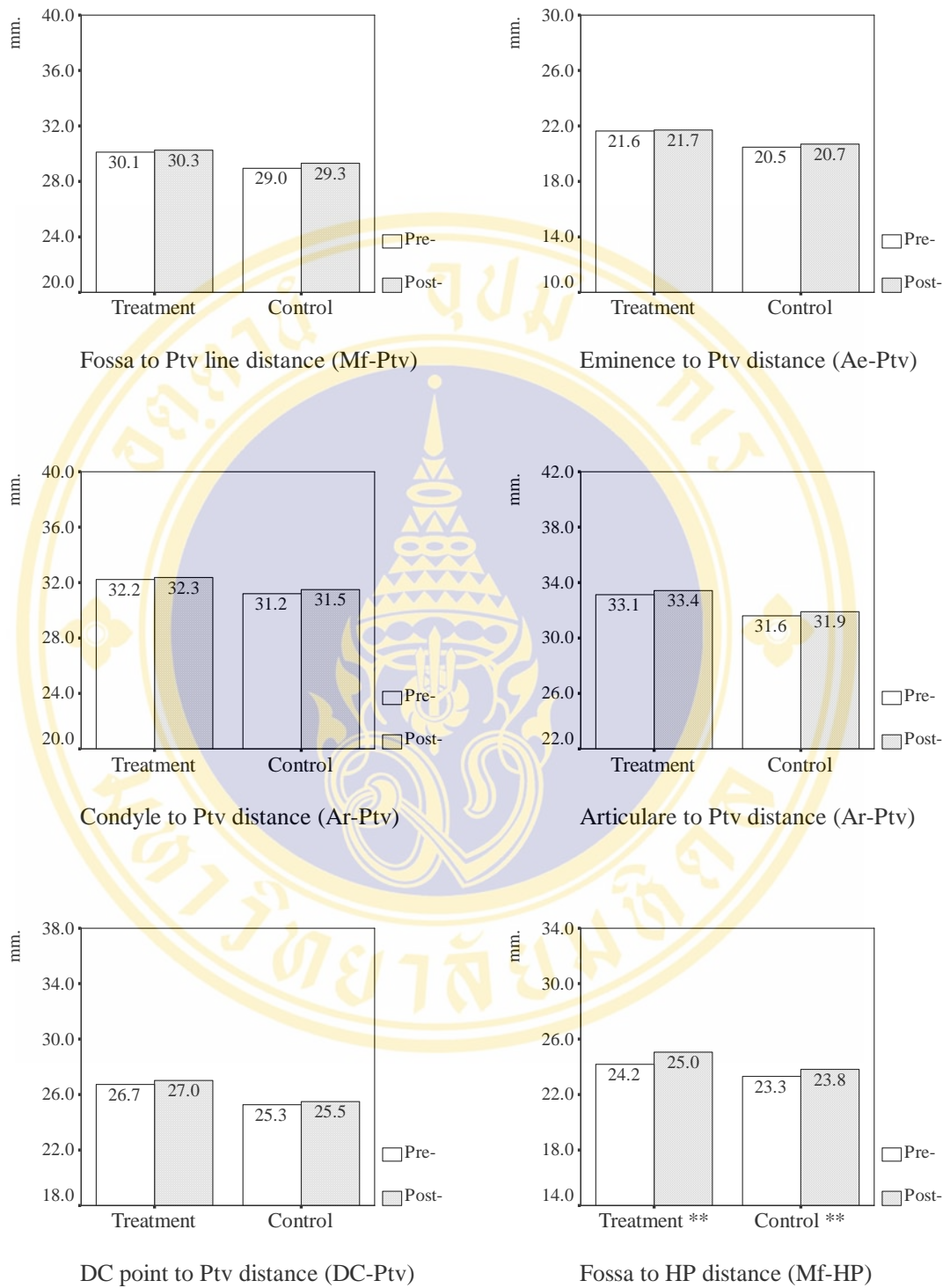


Fig.25 Graph presented vertical skeletal relationship measurement (*P<.05, **P<.01)



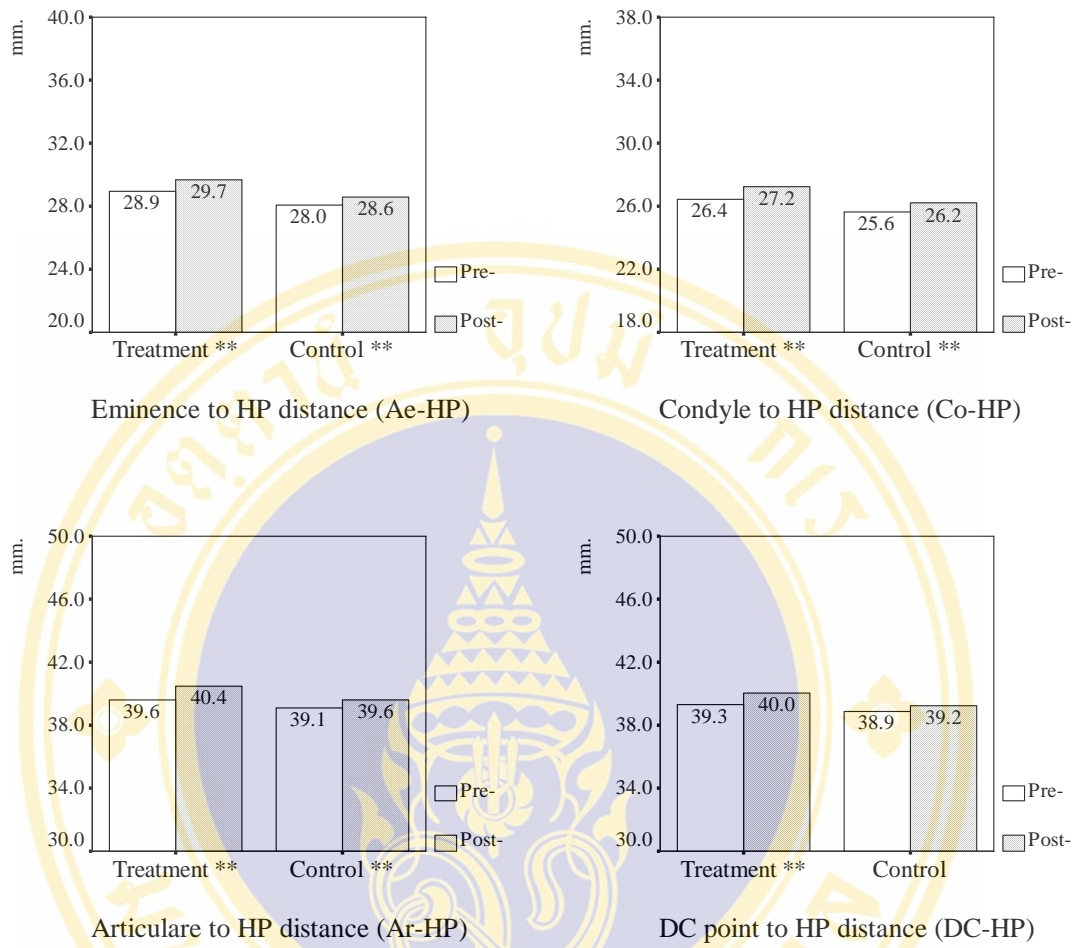
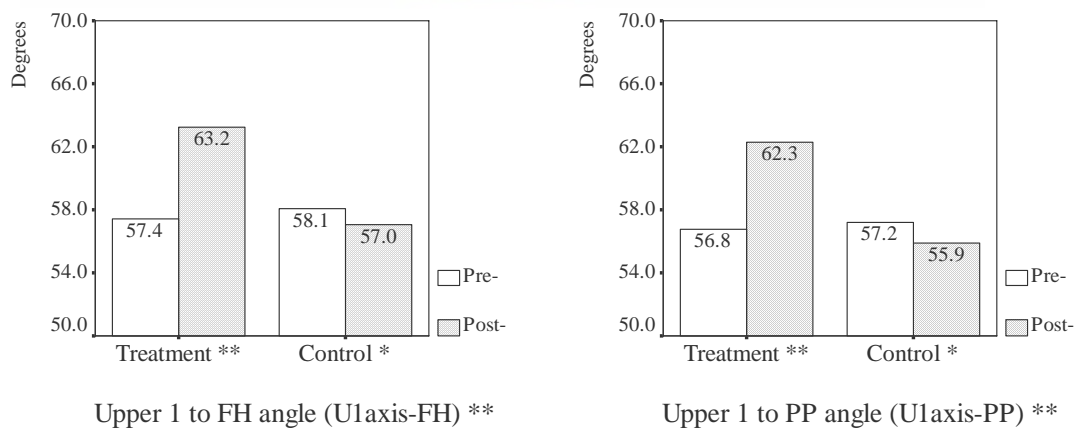
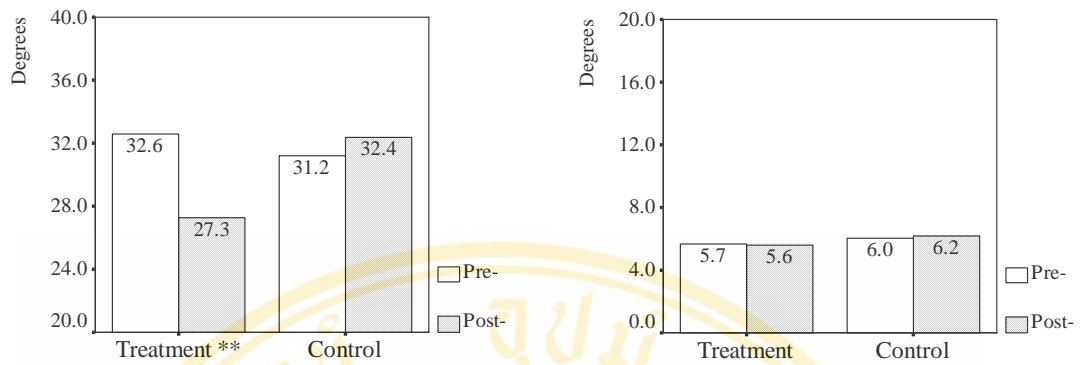


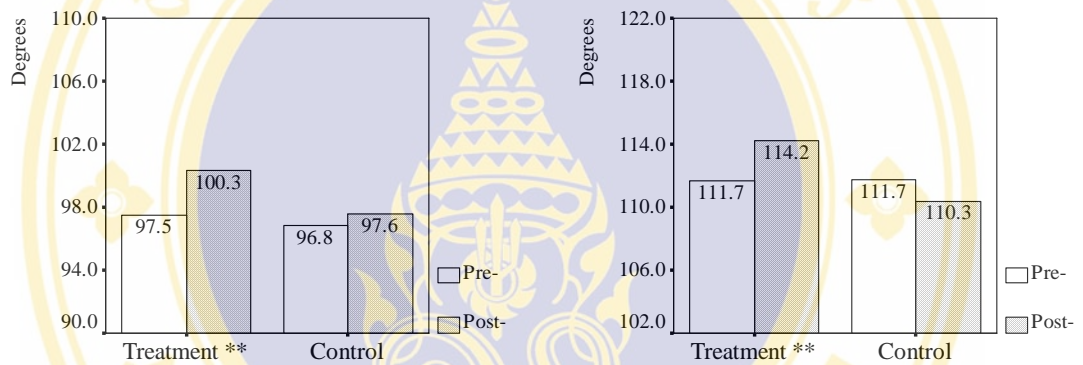
Fig.26 Graph presented Condylar and Glenoid fossa relationship measurement (*P<.05, **P<.01)





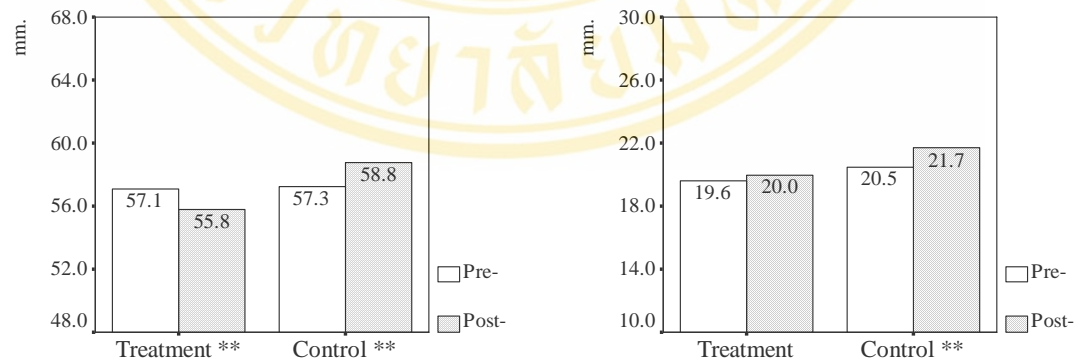
Upper 1 to NA angle (U1axis-NA) **

Upper 1 to AG angle (U1axis-AG)



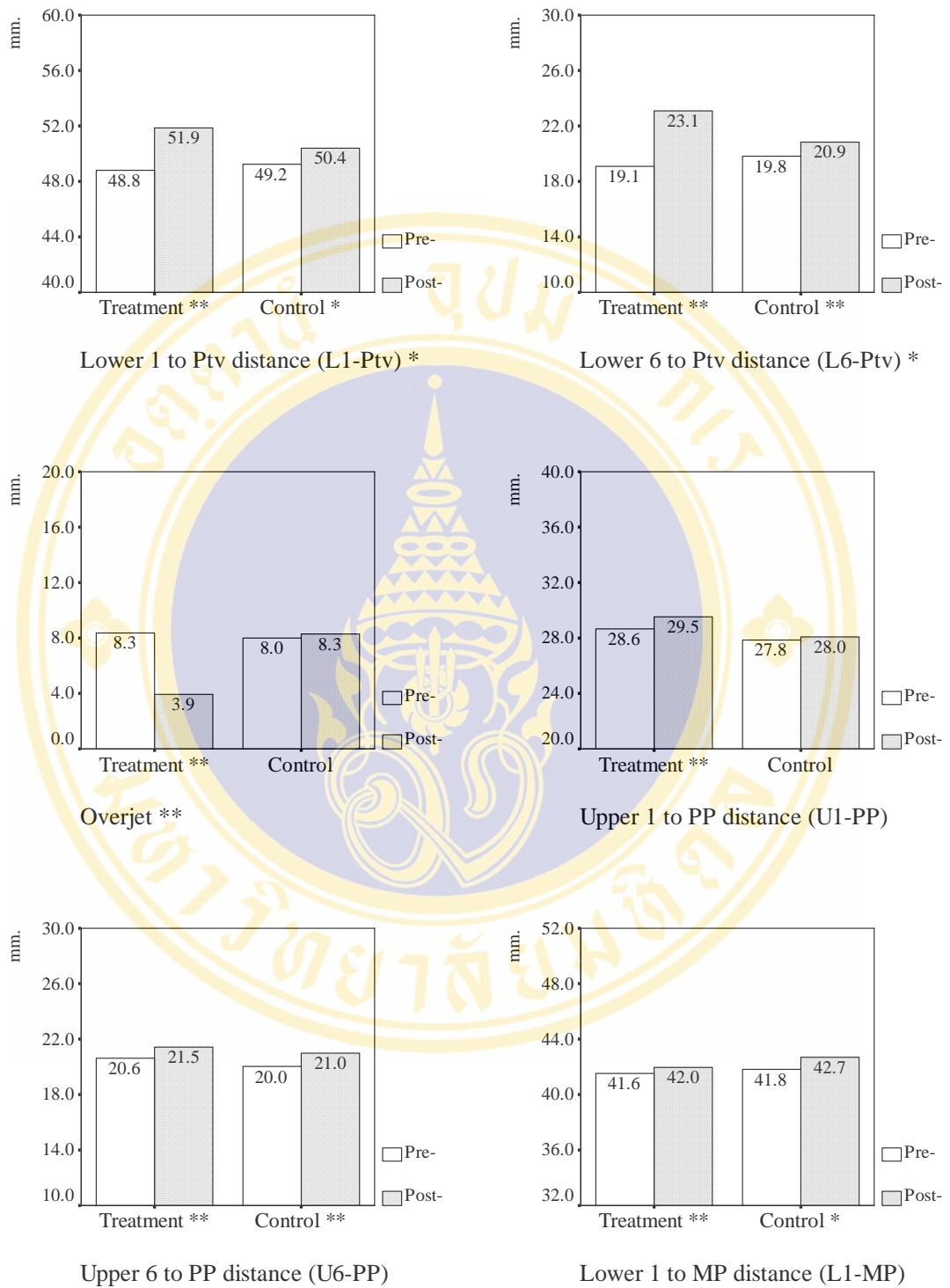
Lower 1 to MP angle (L1axis-MP) *

Interincisal angle *



Upper 1 to Ptv distance (U1-Ptv) *

Upper 6 to Ptv distance (U6-Ptv)



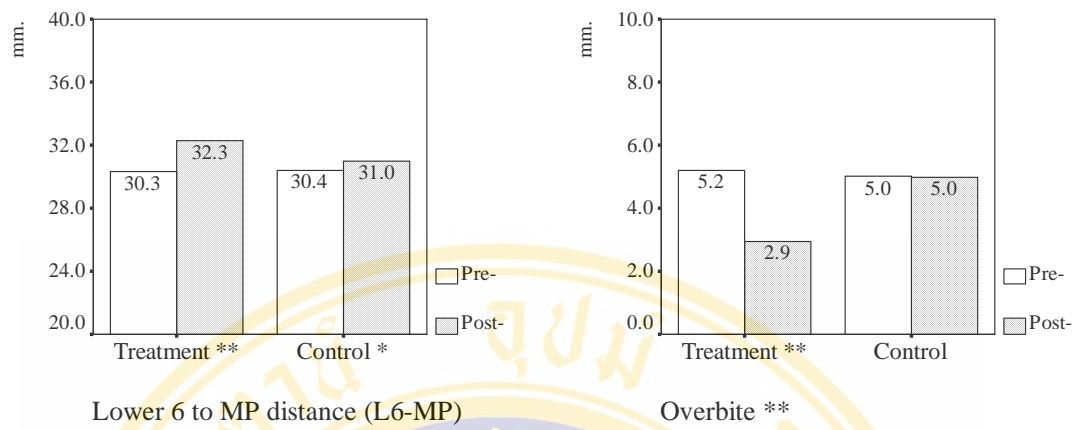


Fig.27 Graph presented dento-alveolar relationship measurement (* $P < .05$, ** $P < .01$)

Change from Pre-treatment to Post-treatment

Comparison of differences in mean changes due to treatment effects between the treatment group and the control group in pre- and post-treatment were summarized in table 10.

Graphical Presentation of Treatment and Observation Changes

Effects of treatment were presented graphically in Fig.28. Change of growth of the control group was presented in Fig.28. Black lines indicated mean at start of treatment. Red lines depicted mean at the end of treatment and observation. All changes were superimposed on S-N at sella.

The treatment group (Fig.28) showed steeper anterior guidance with retracted maxillary incisors, unchanged of condylar guidance inclination, downward movement of maxilla, forward and downward movement of point B with an increase in lower anterior facial height and posterior facial height. There was an increasing of mandibular length. Position of glenoid fossa and condyle were moved slightly downward. Forward movement and proclination of the lower incisors were seen. Point B appeared to have moved forward as a result of functional therapy in the treatment group and to a lesser extent in the control group.

Extrusion of incisors and molars were seen in maxillary and mandibular superimpositions. The treatment group depicted anterior rotation of occlusal plane, reduction of overjet and overbite, improvement of maxilla-mandibular relationship, retroclination of the upper incisors and steeper of anterior guidance.

The same effects were not seen in the control group, where minimal changes were seen. There were lesser forward reposition of the mandible, lesser increased of mandibular length and only slightly increased of lower anterior facial height (Fig.29).

In opposite to the treatment group, slightly increased proclination of upper incisors with reduction of anterior guidance was observed. Large overjet, large overbite and skeletal discrepancy remained the same. However, extrusion of incisors and molars were seen. TMJ was moved slightly downward as in the treatment group, but condylar guidance tended to steeper due to growth.




Fig.28 Treatment group superimposition. Black lines = pre-treatment, Red lines = post-treatment.



Fig.29 Control group superimposition. Black lines = pre-control, Red lines = post-treatment.

Condylar Guidance and Anterior Guidance (Table 10)

Treatment and control groups

The difference between means of pre- and post-treatment measurements of anterior guidance in the treatment group was increased ($6.01 \pm 2.86^\circ$, $P < .01$), while the control group decreased ($-1.23 \pm 1.52^\circ$, $P < .05$), condylar guidance was significantly unchanged in both groups, and the difference between anterior guidance and condylar guidance was greater increased in the treatment group ($6.59 \pm 3.17^\circ$, $P < .01$), while increased in the control group ($-1.73 \pm 2.67^\circ$, $P < .05$).

Intergroup comparisons

When compared mean differences of anterior guidance and condylar guidance in the treatment group with the control group, mean difference of anterior guidance in the treatment group was steeper than the control group ($6.80 \pm 1.55^\circ$, $P < .01$), the difference between anterior guidance and condylar guidance in the treatment group was larger than the control group ($8.19 \pm 1.46^\circ$, $P < .01$). Mean difference of the condylar guidance was no significant difference.

Skeletal Measurements (Table 10)

Maxilla-treatment group

The maxilla of the treatment group grew downward and slightly backward, as evident in the difference between means of pre- and post-treatment measurements. SNA was decreased ($-0.43 \pm 1.04^\circ$, $P < .01$). Upper anterior facial height (ANS-HP) was increased (1.58 ± 1.02 mm., $P < .01$). However, the effective maxillary length (Co-A) was increased (0.65 ± 1.41 mm., $P < .01$). Distance from A point to Ptv plane and the palatal plane related to SN plane were unchanged.

Maxilla-control group

The maxilla of the control group grew only downward. Upper anterior facial height (ANS-HP) was increased (1.40 ± 1.04 mm., $P < .01$). Backward or forward growth did not present significantly after treatment, however the effective maxillary length (Co-A) was increased (1.14 ± 1.48 mm., $P < .05$).

Maxilla-intergroup comparisons

When compared maxillary growth of the treatment group with the control group, there was no significant difference in the difference of sagittal growth (SNA, A-Ptv, Co-A) and vertical growth (SN-PP, ANS-HP).

Mandibular-treatment group

The mandible of the treatment group moved forward and downward, as evident in the difference between means of pre- and post-treatment measurements. SNB was increased ($1.04 \pm 1.29^\circ$, $P < .01$). SN-Pg was increased ($0.96 \pm 1.19^\circ$, $P < .01$). Distance from B point to Ptv plane (B-Ptv) was increased (1.92 ± 2.21 mm., $P < .01$). Distance from Pg point to Ptv plane (Pg-Ptv) was increased (1.95 ± 2.33 mm., $P < .01$). Effective mandibular length (Co-Gn) was great increased (4.55 ± 2.34 mm., $P < .01$). Lower anterior facial height (ANS-Me) was increased (3.06 ± 1.58 mm., $P < .01$). Anterior facial height (Me-HP) was increased (4.85 ± 2.13 mm., $P < .01$). Posterior facial height (Go-S) was increased (3.34 ± 1.91 mm., $P < .01$). Moreover, Cd axis related to FH plane (Cd axis-FH) was increased ($0.38 \pm 1.32^\circ$, $P < .05$). Gonial angle was increased ($1.04 \pm 2.52^\circ$, $P < .05$). However, Y-axis and mandibular plane related to SN plane (SN-MP) were significantly increased after treatment.

Mandibular-control group

The mandible of the control group moved only downward, while significantly forward growth did not present after treatment, as evident in the difference between means of pre- and post-treatment measurements. Go-S was increased (2.41 ± 1.43 mm., $P < .01$). Me-HP was increased (2.53 ± 1.43 mm., $P < .01$). ANS-Me was increased (1.11 ± 0.93 mm., $P < .01$). SNB, SN-Pg, Cd axis-FH, Y-axis, gonial angle, B-Ptv, Pg-Ptv and SN-MP were no significant difference. However, Co-Gn was increased (2.30 ± 1.79 mm., $P < .01$).

Mandibular-intergroup comparisons

When compared mean differences of mandibular growth in the treatment group with the control group. Mean difference of mandibular length (Co-Gn) in the treatment group was longer than the control group (2.97 ± 1.72 mm., $P < .05$). Mean difference of

anterior facial height (Me-HP) in the treatment group was larger than the control group (2.40 ± 1.72 mm., $P < .05$). Mean difference of lower anterior facial height (ANS-Me) in the treatment group was larger than the control group (2.08 ± 1.18 mm., $P < .05$). There was no significant difference in mean difference between the treatment and control group for SNB, SN-Pg, Cd axis-FH, Y-axis, gonial angle, B-Ptv, Pg-Ptv, SN-MP and Go-S.

Maxillary and mandibular relationship-treatment group

The relationship of maxilla and mandible in the treatment group was improved after treatment, as evident in the difference between means of pre- and post-treatment measurements. ANB was decreased ($-1.47 \pm 1.32^\circ$, $P < .01$). Wits was decreased (-3.20 ± 3.55 mm., $P < .01$). The ratio of lower anterior facial height to total anterior facial height (LAFH/AFH) was increased (0.47 ± 0.81 , $P < .01$). However, angle between palatal plane and mandibular plane (PP-MP), angle of occlusal plane to SN plane (SN-OP) and ratio of posterior to anterior facial height (PFH/AFH) were not significantly changed.

Maxillary and mandibular relationship-control group

All of the relationship of maxilla and mandible in the control group did not present any improvement significantly after treatment.

Maxillary and mandibular relationship-intergroup comparisons

When compared maxillary-mandibular relationship of the treatment group with the control group, mean difference of the ANB in the treatment group was smaller than the control group ($-1.39 \pm 0.52^\circ$, $P < .05$). Mean difference of Wits in the treatment group was smaller than the control group (-4.06 ± 1.02 mm., $P < .01$). Mean difference of SN-OP in the treatment group was larger than the control group ($3.57 \pm 1.61^\circ$, $P < .05$). PP-MP, PFH/AFH and LAFH/AFH in the treatment group were not significantly different from the control group.

Condyle and Glenoid Fossa Measurements (Table 10)*Treatment group*

Condyle and glenoid fossa of the treatment group were displaced only inferiorly, not in sagittal direction, as evident in the difference between means of pre- and post-treatment measurements of distance from the mandibular fossa to horizontal plane (Mf-HP) was increased (0.88 ± 0.53 mm., $P < .01$). Distance from articular eminence to horizontal plane (Ae-HP) was increased (0.74 ± 0.60 mm., $P < .01$). Distance from condyle to horizontal plane (Co-HP) was increased (0.81 ± 0.64 mm., $P < .01$). Distance from articular point to horizontal plane (Ar-HP) was increased (0.85 ± 0.89 mm., $P < .01$). Distance from DC point to horizontal plane (DC-HP) was increased (0.67 ± 0.80 mm., $P < .01$). But, distance from mandibular fossa to Ptv plane (Mf-Ptv), distance from articular eminence to Ptv plane (Ae-Ptv), distance from condyle to Ptv plane (Co-Ptv), distance from articular point to Ptv plane (Ar-Ptv) and distance from the DC point to Ptv plane (DC-Ptv) were unchanged significantly.

Control group

Condyle and glenoid fossa of the control group were changed only downward, not changed in sagittal direction as in the treatment group, as evident in the difference between means of pre- and post-treatment. Mean distance from mandibular fossa to horizontal plane (Mf-HP) was increased (0.54 ± 0.38 mm., $P < .01$). Distance from articular eminence to horizontal plane (Ae-HP) was increased (0.55 ± 0.39 mm., $P < .01$). Distance from condyle to horizontal plane (Co-HP) was increased (0.57 ± 0.33 mm., $P < .01$). Distance from articular point to horizontal plane (Ar-HP) was increased (0.52 ± 0.47 mm., $P < .01$). Distance from DC point to horizontal plane (DC-HP), distance from mandibular fossa to Ptv plane (Mf-Ptv), distance from articular eminence to Ptv plane (Ae-Ptv), distance from condyle to Ptv plane (Co-Ptv), distance from articular point to Ptv plane (Ar-Ptv) and distance from DC point to Ptv plane (DC-Ptv) were unchanged significantly.

Intergroup comparisons

When compared condyle and glenoid fossa of the treatment group with the control group, there was no significant difference in the difference in sagittal position (Mf-Ptv, Ae-Ptv, Co-Ptv, Ar-Ptv, DC-Ptv) and vertical position (Mf-HP, Ae-HP, Co-HP, Ar-HP, DC-HP) after treatment.

Dento-alveolar Measurements (Table 10)*Treatment group*

Inclination and position of upper central incisors of the treatment group were improved by they were retroclined, moved backward and extruded, as evident in the difference between means of pre- and post-treatment measurements. Inclination of upper incisor related to FH plane (U1axis-FH) was increased ($5.80 \pm 3.22^\circ$, $P < .01$). Inclination of upper incisor related to palatal plane (U1axis-PP) was increased ($5.48 \pm 3.33^\circ$, $P < .01$). Inclination of upper incisor related to N-A plane (U1axis-NA) was decreased ($-5.29 \pm 3.14^\circ$, $P < .01$). Distance from upper incisor to Ptv plane (U1-Ptv) was decreased (-1.34 ± 1.68 mm., $P < .01$). Distance from upper incisor to palatal plane (U1-PP) was increased (0.87 ± 1.19 mm., $P < .01$).

Inclination and position of lower central incisors of the treatment group were proclined, moved forward and extruded, as evident in the difference between means of pre- and post-treatment measurements. Inclination of lower incisor related to mandibular plane (L1axis-MP) was increased ($2.83 \pm 3.46^\circ$, $P < .01$). Distance from lower incisor to Ptv plane (L1-Ptv) was increased (3.08 ± 2.07 mm., $P < .01$). Distance from lower incisor to mandibular plane (L1-MP) was increased (0.40 ± 0.81 mm., $P < .01$).

Position of upper molar of the treatment group were only extrusion, not moved in sagittal direction significantly, as evident in the difference between means of pre- and post-treatment measurements. Distance from upper molar to palatal plane (U6-PP) was increased (0.82 ± 0.87 mm., $P < .01$). Distance from upper molar to Ptv plane (U6-Ptv) was not increased significantly.

Position of lower molar of the treatment group were moved forward and extruded, as evident in the difference between means of pre- and post-treatment measurements. Distance from lower molar to Ptv plane (L6-Ptv) was increased (4.01 ± 1.82 mm.,

$P<.01$). Distance from lower molar to mandibular plane (L6-MP) was increased (1.93 ± 1.01 mm., $P<.01$).

Relationship of upper and lower incisors in the treatment group was improved after treatment, as evident in the difference between means of pre- and post-treatment measurements. Interincisal angle was increased ($2.55\pm 4.76^\circ$, $P<.01$). Overjet was decreased (-4.42 ± 2.06 mm., $P<.01$) and overbite was decreased (-2.28 ± 1.74 mm., $P<.01$).

Control group

Inclination and position of the upper central incisors of the control group were conversely to the treatment group by they were proclined, moved forward and did not extrude, as evident in the difference between means of pre- and post-treatment measurements. Inclination of upper incisor related to FH plane (U1axis-FH) was decreased ($-1.05\pm 1.49^\circ$, $P<.05$). Inclination of upper incisor related to palatal plane (U1axis-PP) was decreased ($-1.27\pm 1.51^\circ$, $P<.05$). Distance from upper incisor to Ptv plane (U1-Ptv) was increased (1.49 ± 1.25 mm., $P<.01$). Inclination of upper incisor related to N-A plane (U1axis-NA) and distance from upper incisor to palatal plane (U1-PP) did not show significant increased after treatment.

Inclination and position of lower central incisors of the control group were moved forward and extruded as the treatment group but inclination did not significant change, as evident in the difference between means of pre- and post-treatment measurements. Inclination of lower incisor related to mandibular plane (L1axis-MP) was not significant increased. Whereas, distance from lower incisor to Ptv plane (U1-Ptv) was increased (1.19 ± 1.51 mm., $P<.05$). Distance from lower incisor to mandibular plane (L1-MP) was increased (0.86 ± 0.98 mm., $P<.05$).

Position of upper molar of the control group were moved forward and extruded significantly, as evident in the difference between means of pre- and post-treatment measurements. Distance from upper molar to Ptv plane (U6-Ptv) was increased (1.18 ± 0.91 mm., $P<.01$). Distance from upper molar to palatal plane (U6-PP) was increased (0.97 ± 0.69 mm., $P<.01$).

Position of lower molar of the control group were moved forward and extruded as the treatment group, as evident in the difference between means of pre- and post-

treatment measurements. Distance from lower molar to Ptv plane (L6-Ptv) was increased (1.08 ± 0.82 mm., $P < .05$). Distance from lower molar to mandibular plane (L6-MP) was increased (0.57 ± 0.82 mm., $P < .05$).

Relationship of upper and lower incisors in the control group was not improved after treatment, as evident in the difference between means of pre- and post-treatment measurements. There were no significant differences of the interincisal angle, overjet and overbite in post-treatment.

Intergroup comparisons

When compared inclination and position of upper central incisors of the treatment group with the control group, mean difference of U1axis-FH in the treatment group was steeper than the control group ($6.19 \pm 1.62^\circ$, $P < .01$). Mean difference of the U1axis-PP in the treatment group was steeper than the control group (6.35 ± 1.85 mm., $P < .01$). Mean difference of U1-Ptv in the treatment group was more backward than the control group (-2.69 ± 1.58 mm., $P < .05$). U1-PP in the treatment group was not significant difference from the control group.

When compared inclination and position of lower central incisors of the treatment group with the control group, mean difference of the L1axis-FH, the L1-Ptv and L1-MP in the treatment group was not significant difference from the control group.

When compared the position of upper molar of the treatment group with the control group, mean difference of U6-Ptv and U6-PP in the treatment group were not significant difference from the control group.

When compared the position of lower molar of the treatment group with the control group, mean difference of L6-Ptv in the treatment group was more forward than the control group (2.25 ± 1.53 mm., $P < .05$). L6-MP in the treatment group was not significant difference from the control group.

When compared the relationship of upper and lower incisors of the treatment group with the control group. Mean difference of overjet and overbite in the treatment group were smaller than the control group (-4.39 ± 0.55 mm. and -2.03 ± 0.46 mm., $P < .01$ respectively). Interincisal angle in the treatment group was not significant difference from the control group after treatment.

Table 10 Comparison of the difference in mean changes over treatment period between treatment and control group (pre- to post-treatment)

Measures	Treatment (n=51)			Control (n=12)			Treatment effect			
	Diff	SD	Sig.	Diff	SD	Sig.	Mean	SE	Sig.	
Age (years)	1.06	0.31	0.000**	0.90	0.22	0.000**	0.07	0.45	NS	
Anterior, condylar guidance										
AG-FH (°)	6.01	2.86	0.000**	-1.23	1.52	0.017*	6.80	1.55	0.000**	
CG-FH (°)	-0.58	2.49	NS	0.49	1.61	NS	-1.39	0.93	NS	
AG-CG (°)	6.59	3.17	0.000**	-1.73	2.67	0.047*	8.19	1.46	0.000**	
Skeletal horizontal										
SNA (°)	-0.43	1.04	0.005**	-0.10	1.10	NS	-1.36	1.01	NS	
SNB (°)	1.04	1.29	0.000**	0.10	0.93	NS	0.02	1.01	0.039*	
SN-Pg (°)	0.96	1.19	0.000**	0.26	0.74	NS	0.25	0.99	0.048*	
ANB (°)	-1.47	1.32	0.000**	-0.21	0.78	NS	-1.39	0.52	0.010*	
Cd axis-FH(°)	0.38	1.32	0.045*	0.77	1.29	NS	-0.11	0.90	NS	
Y-axis (°)	0.21	1.05	NS	0.15	0.62	NS	0.95	1.05	NS	
Gonial angle (°)	1.04	2.52	0.005**	-0.18	1.98	NS	0.18	2.11	0.039*	
Wits (mm.)	-3.20	3.55	0.000**	0.38	1.40	NS	-4.06	1.02	0.000**	
A-Ptv (mm.)	0.27	0.98	NS	0.59	1.09	NS	-0.35	1.10	NS	
B-Ptv (mm.)	1.92	2.21	0.000**	0.59	1.56	NS	0.87	1.73	0.046*	
Pg-Ptv (mm.)	1.95	2.33	0.000**	0.87	1.37	NS	1.42	1.87	0.034*	
Co-Gn (mm.)	4.55	2.34	0.000**	2.30	1.79	0.001**	2.97	1.72	0.024*	
Co-A (mm.)	0.65	1.41	0.002**	1.14	1.48	0.022*	0.37	1.35	NS	
Skeletal Vertical										
SN-FH (°)	-0.08	0.34	NS	0.01	0.21	NS	0.26	0.20	NS	
SN-PP (°)	0.23	0.98	NS	0.19	1.20	NS	0.20	0.87	NS	
SN-MP (°)	0.33	1.26	NS	-0.41	1.10	NS	-0.10	1.71	NS	
PP-MP (°)	0.10	1.58	NS	-0.56	1.61	NS	-0.30	1.81	NS	
SN-OP (°)	1.12	4.26	NS	-0.98	2.57	NS	3.57	1.61	0.030*	
Go-S (mm.)	3.34	1.91	0.000**	2.41	1.43	0.000**	2.80	1.66	NS	
Me-HP (mm.)	4.85	2.13	0.000**	2.53	1.43	0.000**	2.40	1.72	0.013*	
ANS-HP (mm.)	1.58	1.02	0.000**	1.40	1.04	0.001**	1.28	0.99	NS	
ANS-Me (mm.)	3.06	1.58	0.000**	1.11	0.93	0.002**	2.08	1.18	0.011*	
PFH/AFH (%)	0.20	1.35	NS	0.75	1.23	NS	-0.11	1.12	NS	
LAFH/AFH (%)	0.47	0.81	0.000**	-0.22	0.59	NS	0.58	0.61	0.034*	

Table 10 Comparison of the difference in mean changes over treatment period between treatment and control group (pre- to post-treatment) (continued)

Measures	Treatment (n=51)			Control (n=12)			Treatment effect			
	Diff	SD	Sig.	Diff	SD	Sig.	Mean	SE	Sig.	
Condyle, Glenoid fossa										
Mf-Ptv (mm.)	0.15	0.90	NS	0.33	0.46	NS	0.97	0.75	NS	
Ae-Ptv (mm.)	0.09	0.96	NS	0.20	0.53	NS	1.01	0.75	NS	
Co-Ptv (mm.)	0.14	0.88	NS	0.25	0.74	NS	0.86	0.77	NS	
Ar-Ptv (mm.)	0.25	0.91	NS	0.25	0.60	NS	1.54	0.76	NS	
DC-Ptv (mm.)	0.26	1.00	NS	0.18	0.63	NS	1.53	0.78	NS	
Mf-HP (mm.)	0.88	0.53	0.000**	0.54	0.38	0.000**	1.22	0.75	NS	
Ae-HP (mm.)	0.74	0.60	0.000**	0.55	0.39	0.001**	1.10	0.74	NS	
Co-HP (mm.)	0.81	0.64	0.000**	0.57	0.33	0.000**	1.06	0.78	NS	
Ar-HP (mm.)	0.85	0.89	0.000**	0.52	0.47	0.003**	0.86	0.97	NS	
DC-HP (mm.)	0.67	0.80	0.000**	0.36	0.56	NS	0.78	0.88	NS	
Dento-alveolar										
U1axis-FH (°)	5.80	3.22	0.000**	-1.05	1.49	0.032*	6.19	1.62	0.000**	
U1axis-PP (°)	5.48	3.33	0.000**	-1.27	1.51	0.014*	6.35	1.85	0.001**	
U1axis-NA (°)	-5.29	3.14	0.000**	1.14	1.90	NS	-5.09	1.55	0.002**	
U1axis-AG (°)	-0.13	0.86	NS	0.17	0.97	NS	-0.63	0.28	NS	
L1axis-MP (°)	2.83	3.46	0.000**	0.73	2.34	NS	2.75	2.34	0.024*	
Interincisal (°)	2.55	4.76	0.000**	-1.41	2.83	NS	3.88	2.58	0.013*	
U1-Ptv (mm.)	-1.34	1.68	0.000**	1.49	1.25	0.002**	-2.96	1.58	0.046*	
U6-Ptv (mm.)	0.37	1.44	NS	1.18	0.91	0.001**	-1.68	1.38	NS	
L1-Ptv (mm.)	3.08	2.07	0.000**	1.19	1.51	0.019*	1.42	1.63	0.025*	
L6-Ptv (mm.)	4.01	1.82	0.000**	1.08	0.82	0.001**	2.25	1.53	0.045*	
Overjet (mm.)	-4.42	2.06	0.000**	0.30	1.19	NS	-4.39	0.55	0.000**	
U1-PP (mm.)	0.87	1.19	0.000**	0.22	0.54	NS	1.44	0.91	NS	
U6-PP (mm.)	0.82	0.87	0.000**	0.97	0.69	0.000**	0.49	0.65	NS	
L1-MP (mm.)	0.40	0.81	0.001**	0.86	0.98	0.011*	-0.76	0.89	NS	
L6-MP (mm.)	1.93	1.01	0.000**	0.57	0.82	0.036*	1.31	0.84	NS	
Overbite (mm.)	-2.28	1.74	0.000**	-0.03	0.69	NS	-2.03	0.46	0.000**	

Significant, * P<0.05; **P<0.01, NS= Non-significant

Correlation among Anterior Guidance, Condylar Guidance and Skeletal Relationship

Correlation between Anterior Guidance and Condylar Guidance (Table 11)

In pre-treatment, both groups (treatment, control) presented significant correlation between anterior guidance and condylar guidance ($r=0.32$, $p<0.05$). Anterior guidance correlated significantly with the differences of anterior-condylar guidance ($r=0.78$, $p<0.01$). Condylar guidance showed negative correlation with the differences of anterior-condylar guidance ($r=-0.34$, $p<0.01$).

In post-treatment, the treatment group showed higher significant correlation between anterior guidance and condylar guidance ($r=0.40$, $p<0.01$). Anterior guidance correlated positively with the differences of anterior-condylar guidance ($r=0.81$, $p<0.01$). Condylar guidance did not show significant negative correlation with the differences of anterior-condylar guidance as in pre-treatment.

Correlation among Anterior Guidance, Condylar Guidance and Sagittal Skeletal Relationship (Table 11)

In pre- and post-treatment, anterior guidance significantly correlated negatively with SNA, SNB, SN-Pg, Wits, A-Ptv, B-Ptv, Pg-Ptv ($P<0.1$), and significant correlated positively with Cd-axis and Y-axis. While condylar guidance significantly correlated positively with only Cd-axis and Wits in post-treatment, and significantly correlated negatively with gonial angle. There were positive correlation between the differences of anterior-condylar guidance and Y-axis, and negative correlation with SNA, SNB, SN-Pg, A-Ptv, B-Ptv, Pg-Ptv, Co-A, and Co-Gn only in pretreatment.

Correlation among Anterior Guidance, Condylar Guidance and Vertical Skeletal Relationship (Table 11)

In pre- and post-treatment, anterior guidance presented positive correlation with SN-OP, while in post-treatment it presented positive correlation only with SN-MP, PP-MP and negative correlation with PFH/AFH. Condylar guidance showed positive correlation with SN-FH, SN-PP, Go-S, ANS-HP, PFH/AFH, and negative correlation with SN-MP, PP-MP only in pre-treatment group.

The differences of anterior-condylar guidance presented positive correlation with SN-MP, PP-MP, SN-OP, and negative correlation with PFH/AFH in both pre and post-treatment groups. Furthermore it presented positive correlation with ANS-Me and LAFH/AFH only in post-treatment and negative correlation with Go-S only in pre-treatment.

Correlation among Anterior Guidance, Condylar Guidance, Condylar and Glenoid Fossa Position (Table 11)

Most of condylar and glenoid fossa position variables did not present correlation with anterior guidance and condylar guidance variables, except Ar-Ptv and DC-Ptv correlated positively with anterior guidance in post-treatment, and DC-HP correlated negatively with the differences of anterior-condylar guidance in pre-treatment. No correlation was found with condylar guidance.

Correlation among Anterior Guidance, Condylar Guidance and Dento-alveolar Relationship (Table 11)

There was strong positive correlation between anterior guidance with U1axis-FH, U1axis-PP, U1-PP, U1-NA and interincisal in both groups, and negative correlation with U1-Ptv, U6-Ptv, L1-Ptv, L6-Ptv in both groups. Moreover anterior guidance correlated negatively with overjet and U6-PP only in pre-treatment.

Condylar guidance showed positive correlation with U1axis-FH, interincisal, overbite in both groups, and U1axis-PP only in post-treatment, and L6-MP only in pre-treatment.

There was positive correlation of the differences of anterior-condylar guidance with U1axis-FH, U1axis-PP, U1-PP, U1-NA and interincisal in both groups, and

negative correlation with U1-Ptv, U6-Ptv, L1-Ptv, L6-Ptv in both groups. Moreover it correlated negatively with overjet and U6-PP only in pre-treatment. Notice it was similar to anterior guidance correlation.



Table 11 Correlation between anterior guidance, condylar guidance and skeletal-dento-alveolar variables

Measures	AG-FH		CG-FH		AG-CG	
	Pre-	Post-	Pre-	Post-	Pre-	Post-
Age	NS	NS	.38**	.38**	-.28*	-.36**
Anterior, condylar guidance						
AG-FH (°)						
CG-FH (°)	0.32*	0.40**				
AG-CG (°)	0.78**	0.81**	-0.34**	NS		
Skeletal horizontal						
SNA (°)	-0.28*	-0.42**	NS	NS	-0.33**	-0.44**
SNB (°)	-0.33**	-0.57**	NS	NS	-0.37**	-0.56**
SN-Pg (°)	-0.32**	-0.55**	NS	NS	-0.37**	-0.57**
ANB (°)	NS	NS	NS	NS	NS	NS
Cd axis-FH (°)	0.27*	0.42**	0.27*	0.33*	NS	NS
Y-axis (°)	0.42**	0.70**	NS	NS	0.43**	0.69**
Gonial angle (°)	NS	NS	-0.54**	-0.38**	NS	NS
Wits (mm.)	NS	NS	NS	0.39**	NS	NS
A-Ptv (mm.)	-0.27*	-0.42**	NS	NS	-0.42**	-0.44**
B-Ptv (mm.)	-0.34**	-0.60**	NS	NS	-0.45**	-0.59**
Pg-Ptv (mm.)	-0.33**	-0.59**	NS	NS	-0.46**	-0.61**
Co-Gn (mm.)	NS	NS	NS	NS	-0.27*	NS
Co-A (mm.)	NS	NS	NS	NS	-0.33**	-0.29*
Skeletal Vertical						
SN-FH (°)	NS	NS	0.26*	NS	NS	NS
SN-PP (°)	NS	NS	0.28*	NS	NS	NS
SN-MP (°)	NS	0.41**	-0.36**	NS	0.41**	0.58**
PP-MP (°)	NS	0.38**	-0.45**	NS	0.44**	0.58**
SN-OP (°)	0.40**	0.37**	NS	NS	0.43**	0.55**
Go-S (mm.)	NS	NS	0.32*	NS	-0.31*	NS
Me-HP (mm.)	NS	NS	NS	NS	NS	NS
ANS-HP (mm.)	NS	NS	0.25*	NS	NS	NS
ANS-Me (mm.)	NS	NS	NS	NS	NS	0.30*
PFH/AFH (%)	NS	-0.32*	0.34**	NS	-0.37**	-0.49**
LAFH/AFH (%)	NS	NS	NS	NS	NS	0.32*

Table 11 Correlation between anterior guidance, condylar guidance and skeletal-dento-alveolar variables (continued)

Measures		AG-FH		CG-FH		AG-CG	
		Pre-	Post-	Pre-	Post-	Pre-	Post-
Condyle, Glenoid fossa							
Mf-Ptv	(mm.)	NS	NS	NS	NS	NS	NS
Ae-Ptv	(mm.)	NS	NS	NS	NS	NS	NS
Co-Ptv	(mm.)	NS	NS	NS	NS	NS	NS
Ar-Ptv	(mm.)	NS	0.28*	NS	NS	NS	NS
DC-Ptv	(mm.)	NS	0.34*	NS	NS	NS	NS
Mf-HP	(mm.)	NS	NS	NS	NS	NS	NS
Ae-HP	(mm.)	NS	NS	NS	NS	NS	NS
Co-HP	(mm.)	NS	NS	NS	NS	NS	NS
Ar-HP	(mm.)	NS	NS	NS	NS	NS	NS
DC-HP	(mm.)	NS	NS	NS	NS	-0.32*	NS
Dento-alveolar							
U1axis-FH	(°)	0.98**	0.98**	0.30*	0.40**	0.78**	0.79**
U1axis-PP	(°)	0.88**	0.89**	NS	0.30*	0.77**	0.76**
U1axis-NA	(°)	-0.92**	-0.88**	NS	NS	-0.72**	-0.66*
U1axis-AG	(°)	NS	NS	NS	NS	NS	NS
L1axis-MP	(°)	NS	NS	NS	NS	NS	NS
Interincisal	(°)	0.56**	0.55**	0.34**	0.38**	0.34**	0.34*
U1-Ptv	(mm.)	-0.59**	-0.64**	NS	NS	-0.59**	-0.61**
U6-Ptv	(mm.)	-0.36**	-0.50**	NS	NS	-0.47**	-0.60**
L1-Ptv	(mm.)	-0.31*	-0.57**	NS	NS	-0.37**	-0.50**
L6-Ptv	(mm.)	-0.38**	-0.56**	NS	NS	-0.47**	-0.58**
Overjet	(mm.)	-0.57**	NS	NS	NS	-0.46**	NS
U1-PP	(mm.)	0.31*	0.46**	NS	NS	0.30*	0.47**
U6-PP	(mm.)	-0.27*	NS	NS	NS	-0.38**	NS
L1-MP	(mm.)	NS	NS	NS	NS	NS	NS
L6-MP	(mm.)	NS	NS	0.28*	NS	NS	NS
Overbite	(mm.)	NS	NS	0.38**	0.35*	NS	NS

Significant, * P<0.05; **P<0.01, NS= Non-significant

CHAPTER VI

DISCUSSION

The results were discussed in main three parts: 1) general consideration, 2) effect of Activator and Twinblock appliances on dento-facial structures, and 3) correlation among anterior guidance, condylar guidance and skeleto-dental relationship, respectively.

General Consideration

Study Design

The present study design was retrospective study by document reviewed, comparison with untreated and criteria matched group. This investigation, whilst as possible of the methods used to evaluate growth modification in Class II malocclusions. All patients who commenced functional appliances treatment were included in the treatment group regardless of outcome. The control group included patients who comply with treatment, reached molar Class I or Class III relationship or reduced overjet and overbite. The controls were the patients matched criteria of treatment subjects. Which were reported failed to wear appliances or rejected to treat with functional appliance. A treatment effects could be investigated by compared growth of control.

Any retrospective study was likely to introduce bias by producing an inflated view of treatment outcome. Only successfully treated cases were included in the study because as with most retrospective studies the patients who failed to complete treatment did not have a final cephalometric radiograph. This was believed to exaggerate magnitude of treatment response because it could not be assumed that patients who defaulted would have responded to treatment in the same way as successfully treated cases. Bias could also creep into prospective trials as a result of the loss to follow up after randomization had taken (110).

Optimum study design to investigate treatment effects were a randomized prospective controlled trial (RCT) and previous research into the treatment effects of

functional appliances have been criticized and recommendations studied design by Tulloch et. al.(111). They recommended using of concurrently selected control group for comparison with the treatment group. All retrospective studies were liable to sampling bias as clinicians will actively recruit patients who they feel would respond favorably to treatment. Whilst a prospective randomized clinical trial was ideal approach for research into functional appliances effectiveness, this study design still presented difficulties.

If the patients were recruited early it was acceptable for them to be randomly placed into no treatment the control group, therefore allowing direct comparison of the effects of early treatment with normal growth. However, it may not be clinically or ethically acceptable to deny treatment to an older patient, having reached conventional age for functional appliances therapy. Therefore, only be able to compare effects of early treatment against the control group and would not be able to compare treatment during puberty with normal growth.

Material and Method

This study compared effects of the appliances and growth mean over 11-month period including all patients regardless of compliance or achievement of a Class I or III molar relationship. Treatment was continued if malocclusions not corrected fully within study period. As all mean changes were modest and frequently smaller than their associated standard deviations, this may had caused significant differences to underestimate true situation. It must be stressed that this study reported only the initial effects and no conclusions can be drawn about stability.

The differentiation of patient groups with good and bad cooperation proved to be difficult despite the fact that study design (retrospective design) and several criteria (wearing-time records, overjet development, patient records, clinical inspection of the appliance for fitting accuracy and sign of use, handling of the appliance by the patient) were used. This was especially true because the wearing-time records were either lacking or incomplete in several patients. Therefore, the degree of improvement and treatment effectiveness were influenced by above factors.

It has been reported that effective TMJ changes could be significantly increased during functional appliances treatment period of approximately 8 months. These

finding were in agreement with several other studies that analyzed treatment effects on mandibular condyle growth (46, 112). Therefore, treatment period in this study was enough for observed of TMJ changes from treatment effects.

There was no significant difference between sexes in this study. Supported by many studies that no significant difference condylar guidance between male and female (41, 43, 47, 52, 64, 70). Therefore, male and female groups were pooled together in this study.

Anterior Guidance and Condylar Guidance Investigation Method

Many methods have been used in measuring condylar guidance inclination. These methods include impressions done with modeling clay (42) and wax, direct measurements (37), arthrograms (38), panoramic radiographs (53), tomographic radiographs (43, 44), scaled photographs (36), cephalometry using intensifying screens (49), protrusive condylar path (51), silicone impression (4) and lateral cephalometric radiographs (25, 41, 47, 48).

A method used was a very important factor, as it influenced the results. Modeling clay and wax have been criticized as being vulnerable to distortion and shrinkage. Panoramic radiograph of TMJ were distorted, making it difficult to accurately and reliably interpret its morphology. Protrusive condylar path was an indirect method of measuring the steepness of the eminence. However, protrusive condylar path tracing could accurately reveal the articular eminence inclination was questionable. Photography and uncorrected tomograms could not overcome the anatomic difficulties of the region. It should be realized that, in using a radiographic technique, it was very important to select one that was capable of imaging the articular eminence at the sagittal plane, where the condyle-disk complex translates. This required the projection x-rays to be individually corrected according to the angulations of the width (long axis) of the condyle and fossa. The silicone impression may be offered a reliable means of articular eminence impression, hence the calculation was reliable, but it could be used in dry skull only.

A first requirement in understanding the influence of the articular eminence on mandibular movements would be to determine the relationship which axis between them and their corresponding condylar paths. Many investigators have developed

techniques to record and assess condylar movement. That these techniques do, in fact, accurately record condylar movement has been assumed primarily because the recording or measurements have been repeatable on the same patient. Anatomical evidence supporting proposal that condylar recording represent a form-function relationship, evidence related to the form of condylar head, articular disc, or articular eminence was lacking. The relationship between the anatomical form of the articular eminence and protrusive condylar path should be correlated to enhance and influence in mandibular movement (51).

The relationship between form of the articular eminence and TMJ function has been clearly established. Stallard and Stuart (113) proposed that muscles operated mandible by holding the condyles against the eminence throughout all condylar operations and would expect the condylar head to follow exactly anatomical form of articular eminence when mandible was moved into protrusion.

Corbett et. al. (51) studied correspondence of the condylar path between plaster models and tracing from cephalograms of articular eminence of skulls. They found that radiographically derived protrusive condylar paths and gnathologically recorded protrusive condylar path were the same. They concluded that in protrusion, condylar head of the mandible follows closely anatomical form of articular eminence. They suggested using a lateral cephalograms to consistently and accurately trace articular eminence and approximate protrusive condylar path, that with an appropriate some experience, articular eminence could be located from cephalograms as accurately as most cephalometric landmarks.

Lateral cephalometric radiographs have been used to investigate the condylar guidance angle and glenoid fossa changing in static positions by many investigators (41, 47, 48, 50, 53, 114-117). It might be advantageous in study of condylar path of mandibular movement by fixing the mandible in static position (maximum intercuspation) (118). Corbett et. al. (51) and Widman (49) used a cephalometric technique to show the relationship between the condyle head and the articular eminence. They concluded that condyle head closely followed anatomical form of the articular eminence in protrusive movement. Argonin and Kokiich (1987) studied a displacement of glenoid fossa during treatment. Burchang (1998) studied about condyle growth and glenoid fossa displacement during childhood and adolescence.

Silapabangleng (1991) investigated condylar path angles in a group of patients. Wattanatchariya (1998) investigated anterior guidance and condylar guidance in normal occlusion and vary skeletal pattern. Angela (1985) investigated ethnic variations in sagittal condylar guidance angles. Furthermore, there was no significant difference in sagittal condylar guidance angles measurement when comparing between prosthetic and lateral radiographs technique (50, 116, 119). Systemic and method errors were acceptable (95). Therefore the lateral radiograph technique was also accurate enough to be used in this study.

Due to the errors inherent in cephalometric, it was imperative to use appropriate and consistent techniques to identify and measure inclination of condylar guidance. Therefore, tracing was made by the same technician and rechecked accuracy by experience professional observer. However, accurate and valid to reflect the biological parameter measurements were recommended to used extensive radiographic images such as lateral tomograms, magnetic resonance image (MRI), CT and CT scan to confirm correct scientific interpretations and occlusion.

Right and left sides of articular eminence and condylar path were averaged on tracing. Katsavias (4), Ichikawa and Laskin's (120) found that the differences between right and left sides were not statistically significant. Cohen (121) has suggested that left and right protrusive condylar path were similar. Furthermore, under normal conditions, a articular eminence inclination had a symmetrical pattern of growth. So, average traced of the left and right articular eminences could be used in this study.

Effect of Activator and Twinblock Appliances on Dento-facial Structures

Treatment of Class II malocclusions was frequently aimed at correcting or masking a skeletal discrepancy, improved facial profile and also improved functional occlusion. There was conflicting evidence existed as to the effectiveness of growth modification appliances, any dento-facial change may be due to normal growth and would have occurred irrespective of therapy (17). Therefore, the present study was designed to represent treatment effects by comparing with the untreated control group.

The results of the present investigation confirmed previously held options that the Activator and Twinblock appliances were capable of producing both skeletal and dental treatment effects in growing craniofacial complex. The changes observed during treatment reflect combined effects of treatment and individual growth. Ideally, a matched or at least a comparable control group should be included for identifying the changes due to growth (10, 13, 122). So, in this study, the control group was consisted of longitudinal growth data of untreated Class II division 1 malocclusions subjects to eliminate possible differences in growth pattern.

Effect on Anterior Guidance and Condylar Guidance

Before present finding were compared to other investigators. It must be emphasized that a methodology for measuring both condylar guidance and anterior guidance were not consistent. Condylar guidance angle measured by prosthetic devices with or without the aid of cephalometric had built-in limitations. Anterior guidance was even more difficult to compare because of lack of standardized methodology and terminology. The present method was similar to Wattanatchariya's study, so data could be compared directly. But, some results could not be compared directly with other investigators.

Condylar guidance

Point on the studies that using FH plane as a reference plane, condylar guidance (CG-FH) of this study was 49.69° and 49.11° of pre- and post-treatment respectively (Fig.31 and 32). Condylar guidance of this study was close to other's studies such as, Widman's report (49), which was measured by mean of lateral cephalometric radiograph and axiographic tracing and mean value was 50.9° .

Katsavrias (4) studied change in articular eminence inclination during craniofacial growth period in dried skulls. The results showed that mean articular eminence inclinations were 42° - 56° at age 10-20 years (same age as present samples). There were 10 degrees increasing between the edge of 7-15 years or 1.25 degrees increased per year (Fig.9). Ricketts found that the inclination was 46° at age 7.5-year, and 52° at age 12.5-year respectively (4).

Flatter condylar guidance was found in some studies. Such as Javid's study (123) (45°), Posselt and Nevstedt's study (124) (40°) which measured condylar guidance from lateral cephalometric radiographs. Hanau and Dentatus recommended condylar guidance estimate 30° and 40° respectively (47). Nickel et. al. (36) studied in dried skulls, the results showed that at age 18-year, eminence angle was 45° .

Steeper condylar guidance was found by, Wattanatchariya's (41) and Silapabanleng's (47) which were measured by the same method. Mean values were 51.63° in skeletal type II group and 51.39° in normal occlusion group of Wattanatchariya's study and 60.88° of Silapabanleng's study, but the samples were adult. Kucukkeles et. al. (125) reported mean protrusive condylar path of healthy TMJ was varied between 50.1° and 54.9° by using axiograph.

A variation of condylar guidance in each study might be due to differences in methods, reference plane, age of subjects and sample groups or ethnic groups (116). Furthermore, according to large standard deviation from mean in this study and also in other studies indicated a wide variation of condylar guidance in individuals. It was therefore important that average condylar guidance angle should not be used in treatment planning.

Condylar guidance was a part of posterior wall of articular eminence. The change of articular eminence should effect on condylar guidance too. Studies have documented the adaptive mechanism of the TMJ in both human and animal models. Glenoid fossa and articular eminence remodeling have been studied through investigations of changes after condylectomy (126), condylar fractures (127), TMJ surgical procedures (128), permanent tooth loss (71), and occlusal equilibration (129). Considerable, evidence suggested that orthopedic appliance therapy could also induce adaptive change in TMJ. Little has been documented as to articular eminence slope remodeling in response to forward positioning of mandible.

When the appliances was inserted into the mouth, its downward and forward into a position determined during bite registration. As long as the appliance was in the mouth, the condyles were displaced and kept over the top of the articular eminence. The articular eminence also presented adaptive capacities (4), which has been reported these alterations were greatly influenced by the dental function (130). Therefore the articular eminence inclination (condylar guidance) would be changed by functional appliances.

Inclination of the articular eminence dictated path of condylar movement as well as a degree of rotation of the disk over the condyle. The steeper condylar guidance, the further the condyle was forced to move inferiorly as it shifted anteriorly. This results in greater vertical movement of the condyle, mandible, and mandibular arch upon opening (23). It has been reported that during opening, the posterior disk rotation was more prominent in joint with steep condylar guidance in joints than with shallow condylar guidance (131). During functional treatment, the condyles shifted anteriorly and inferiorly reaching the top of the articular eminence (Fig.30).



Fig.30 During the appliance was in the mouth, the condyle move along the inclined into the top of articular eminence.

According to Hinton's studies (130), a condyle positioned at the top of the articular eminence would cause an increase in articular eminence inclination and height. Hinton's assumption was valid, when incisor biting was taking place. With mandibular protrusive appliances, while the condyle was displaced toward the top of the eminence, it was not certain that forces will also develop. As a matter of fact, the recorded degree of horizontal forces applied to the maxilla during treatment with

Activator. This showed that the magnitude was about 100 g, which according to current concepts, was not suitable for an orthopedic effect (132, 133). In animal experiments (7) in which the mandible was forced forwards and the condyles assumed a more anterior position in the fossa have shown the fossa remodel anteriorly and become flatter. Flattening and forward remodeling of the fossa may happen as a result of increased pressure on the eminence.

Appliances needed to be worn for a prolonged period of time, usually 1.5 to 2 years to ensure complete condylar adaptation following its initial displacement from the fossa (6).

The present results of our study showed that inclination of condylar guidance was not significant change both in treatment and the control groups. However, there was a trend toward reduction of inclination, denoting a decrease of steepness. While in untreated subjects, this trend was contrary to the treated subjects, there was a trend toward increasing of steepness (Fig.32 and 33).

This results was similar to Katsavias's studies that there was no significant change in articular eminence morphology (height and inclination) as a result of using Activator for duration range from 0.72 years to 2 years (mean 1.33 years), but he lacked data from untreated subjects for comparison. Whereas, Birkbak et. al. (9) conducted a similar study; they reported inclination remained the same after treatment. However, neither the cutting depth nor the angulations of radiation was individualized, and these characteristics may explain the contradictions in their findings.

In animal studies, such as monkeys (7, 134), rats (135), and sheep (136), the results of these studies showed that the glenoid fossa was displaced forward occurred as an adaptation to chronic anterior repositioning of the mandible and the fossa became flatter. Flattening and forward remodeling of the fossa may happen as a result of increased pressure on the eminence.

A reciprocal data from dried skull studies (4). The growth rate of articular eminence inclination (condylar guidance) in skull was 1.25° per year. Considering that mean treatment time with functional appliances was 0.87 year, whereas 0.88 year of observation period in untreated subjects. They followed that the change expected in skulls came to 1.09° and 1.1° respectively. In present studies, inclination was decreased -0.58° in treated group and the increase came to 0.49° in untreated group.

It was obvious that the results of this study point to a possible effect of functional appliances on condylar guidance characteristics. It seemed that they caused flatten of articular eminence. In the other word, they decreased the condylar guidance inclination. However, our statistical analysis did not support such a conclusion because no significant was found in treated and untreated group. It was important to note that the possibility for error exists because of the small sample size, the large stand deviation of mean and the short time for bone remodeling. However, the most important feature of this study was the biological significance of our finding. Did the less than 1° of reduction of condylar guidance affect the outcome of treatment and anterior guidance relationship with a functional appliance? Therefore, the treatment significance of these finding was negligible and other mechanisms of the possible effective action of functional appliances should be sought.

However, TMJ remodeling was depended on differing with age, pathologic conditions or malocclusions. It was widely accepted that the TMJ was subjected to loading under normal function. It has been reported that TMJ loading was expected to differ among malocclusions (68, 137). After functional treatment Class II division 1 to Class I relation, the loading was expected to change, so the shape of the condyle and glenoid fossa should be altered. But from this present results the condyle and glenoid fossa were not significant changed in morphology.

In addition, it has been proposed that a steep articular eminence could be one etiologic factor in the development of TMJ disorder. There was a correlation between the prominence of the articular eminence and a development of anterior disc displacement, internal derangement of TMJ and clicking (53, 54, 57, 131, 138). This means that the steeper inclination of the articular eminence the greater the amount of posterior rotation of the disc on the condyle. Kerstens et. al. (53) reported mean condylar guidance in patients with and without anterior disc displacement (63.9° and 49.4° respectively). Mean difference was 14.5° and in a subsequent study that 87% felt better after eminectomy. This was interpreted to indicate that a flatter eminence was more favorable. Hall et. al. (57) reported the TMJ clicking group had pronounced angle than the normal joint.

According to Wattanatchariya's study (41) that Class II skeletal had steeper condylar guidance than Class I skeletal and the deep-bite had more inclination of

condylar guidance than normal overjet, overbite. Our finding showed the functional appliances could enhance mandible to Class I relation, reduced overjet, and reduced overbite and condylar guidance tended to be flatter after functional therapy. Therefore functional appliances seemed to reduce predisposing factors to anterior disc displacement and reduce etiology factors in development of TMJ disorder.




Fig.31 Diagram of anterior guidance (AG-FH), condylar guidance (CG-FH) and the difference of anterior-condylar guidance (AG-CG) between pre- and post-treatment in treatment and control group (* P<0.05; ** P<0.01)

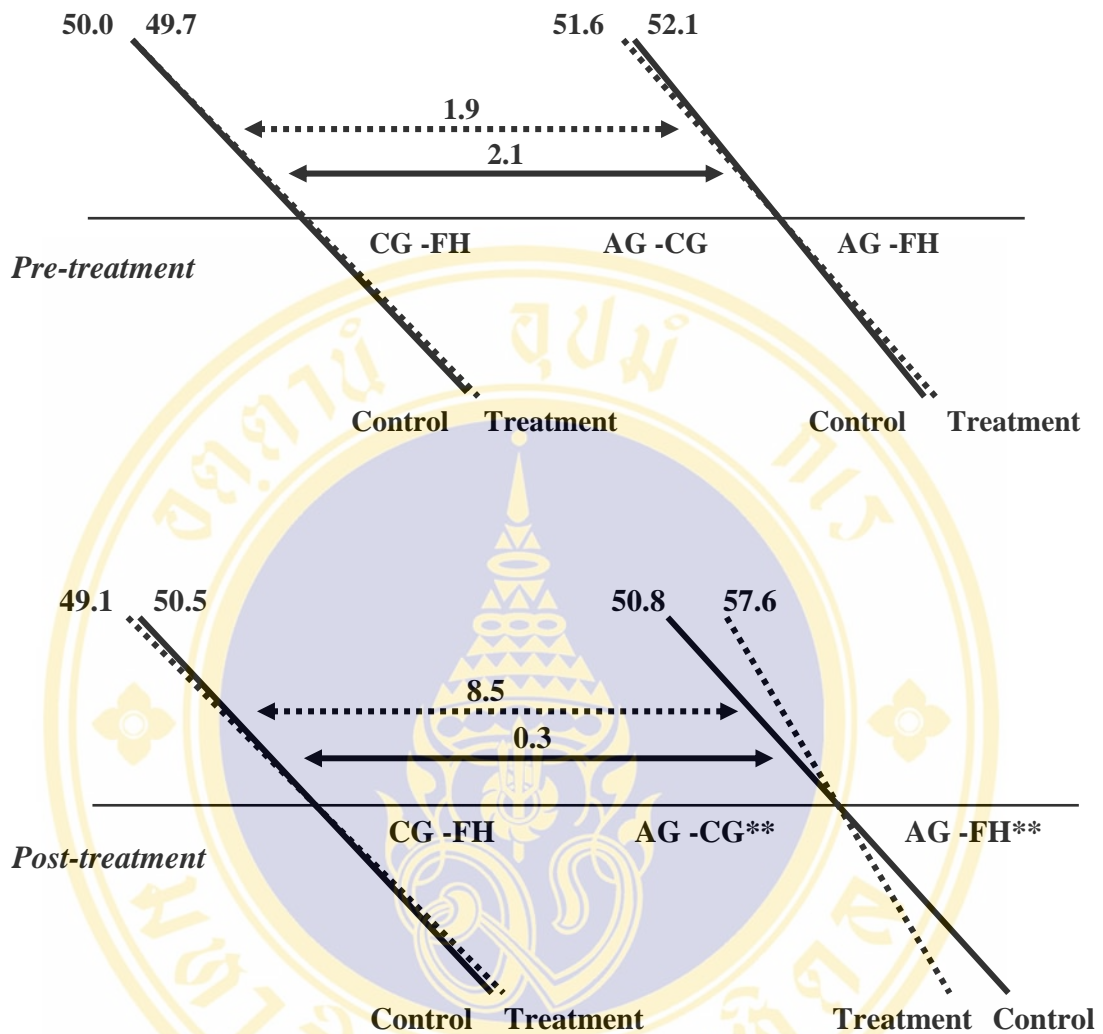


Fig.32 Diagram the comparison of anterior guidance (AG-FH), condylar guidance (CG-FH) and the difference of anterior-condylar guidance (AG-CG) between the treatment and the control group in pre- and post-treatment (* $P < 0.05$; ** $P < 0.01$)

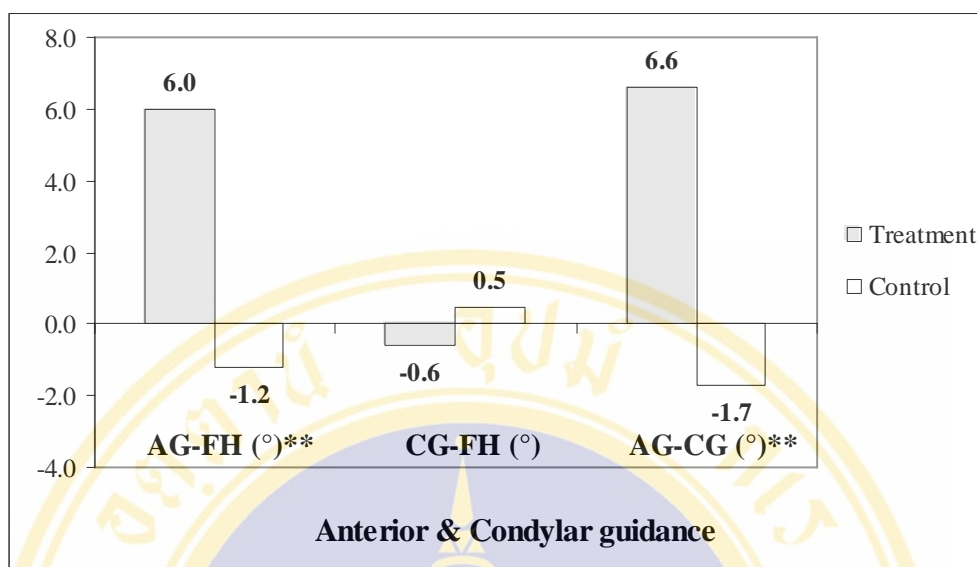


Fig.33 Diagram presented changing of anterior guidance, condylar guidance and the difference of anterior-condylar guidance over the treatment period (* P<0.05; ** P<0.01)

Anterior guidance

Anterior guidance of this study was 51.61° and 57.62° in pre- and post-treatment respectively. The findings found that functional appliances therapy resulted in steepened anterior guidance (6.01±0.31°) significantly. On the contrary, the control show mean decreased in anterior guidance (-1.23±1.57°) as a result of growth alone (Fig.31, 32, 33).

When compared with Wattanatchariya’s study (41) which was 59.28° and 58.03° in skeletal type II and normal occlusion group respectively. In pre-treatment the anterior guidance of our study was shallower than normal occlusion, but after treatment it was close to the normal. The steeper anterior guidance in skeletal type II samples of Wattanatchariya’s study than Class II division 1 samples of this study, in fact it should have near value, but it was different. It may be due to mixing of division 1 and 2 malocclusions samples of Wattanatchariya study’s samples. Because of Class II division 2 malocclusions had very steep anterior guidance than Class II division 1.

An occlusion of anterior teeth was the key to developing and perpetuating an ideal occlusion. The anterior guidance protected posterior teeth by disoccluding them in eccentric positions. A basic philosophy was gnathologic approach, which stated that

lingual surfaces of the maxillary anterior teeth are entirely controlled by condylar border movements. Articulating surfaces of teeth must be in harmony with these movements. The condylar border movements were controlled by anterior teeth and neuromuscular system (2). Without anterior teeth the mandible would close in positions that would direct forces horizontally on the posterior teeth. The lingual surfaces of the maxillary incisors acted as proprioceptive guides to bring teeth together in centric occlusion.

Down (77) recorded an average interincisal angle of 135° , because of this angle the anterior teeth were proprioceptively sensitive and served to redirect the path of closure to normal pattern. In Class II division 1, incisors were proclined and the interincisal angle was acute than normal. Therefore the proprioceptive guides to bring the teeth together in centric occlusion would not be established. After treatment, the incisor inclination and interincisal angle were close to normal, then the normal movement pattern should be occurred.

According to our concept for treating skeletal Class II malocclusions, and on the basis of the disclusive occlusion, corrected maxillary incisor inclination should be set conform to the condylar guidance to provide disclusive movement. Our finding suggested that, the functional appliances could correct incisal axis inclination to normal and provide disclusive occlusion with condylar guidance during mandibular protrusion.

The implication of such a finding could be clinically important. It became possible to draw some functional information from a patient's cephalometric radiograms. This information could be helpful not only in diagnosing and planning the best esthetic treatment for a patient. It could also helpful in providing a rather simple method of incorporating some functional parameters within that patient's treatment plan.

Difference of anterior-condylar guidance (AG-CG)

Contemporary gnathological concepts dictated that the anterior guidance should disclude the posterior teeth during mandibular protrusion. Improper anterior guidance has been associated with excessive posterior tooth wear, alveolar bone loss, tooth mobility due to traumatic occlusion and TMJ dysfunction (25). If anterior guidance was flatter than condylar guidance, potential harmful posterior cusp contacts would occur when mandible moved eccentrically. So, if the anterior guidance was slightly steeper, the posterior teeth will be separate from occlusion (24, 32). While, a over steeper anterior guidance in relation to condylar guidance could create unfavorable leverages on the anterior teeth or result in uncomfortable mastication (25). There must be harmony between the anterior and condylar guidance with disclusion of posterior teeth by the incisors when the mandible moved eccentrically (24).

Both in pre- and post-treatment mean values of anterior guidance were more than mean values of condylar guidance. The difference of anterior-condylar guidance (AG-CG) was 1.92° in pre-treatment and 8.51° in post-treatment (Fig.30, 31, 32). Activator and Twinblock therapy resulted in increased the difference of anterior-condylar guidance ($6.59 \pm 3.17^\circ$) significantly. On the contrary, the control group showed decreasing of the difference of anterior-condylar guidance ($-1.73 \pm 2.67^\circ$) as a result of decreasing of anterior guidance. The difference of this angle in treatment and the control group after treatment were influenced by changing of anterior guidance in each group. Because of the condylar guidance did not change significantly after treatment. Therefore, changing in incisors inclination could effect directly to the difference of anterior-condylar guidance.

When compared with the other studies, Wattanatchariya's (41) reported the difference of anterior-condylar guidance was 6.64° in normal occlusion and 7.65° in skeletal type II group. Bell and Harris (24) found that mean difference of the two angles was 6.3° in Class I molar relationship and 4.9° in good occlusions (grand mean 5.6°). This angular difference would create the hinge rotation of condyle around the transverse horizontal axis that assists the posterior disclusion, so the disclusive occlusion could be established when mandible in protrusive movement (3, 62, 139, 140). McHorris (32) suggested that the ideal anterior disclusive angle 5° greater than condylar disclusive angle. Kohno and Nakano (34) suggested that incisal path should

be equal to or steeper than the condylar path to some extent, not more than 25° steeper, whereas the incisal path should not be much flatter than the condylar path.

From this finding, in pre-treatment the difference of anterior-condylar guidance was too small to provide posterior disclusion during protrusive movement. When upper incisors were retracted, after treatment, the difference of anterior-condylar guidance was increased enough to provide posterior disclusion. In the control group, the difference of anterior-condylar guidance was decreased and not enough to provide posterior disclusion. When the mandible was protruded, the anterior guidance did not control anterior movement. The posterior teeth were occluded as group function, risked to trauma occlusion of posterior teeth and developed TMJ dysfunction (Fig.34). This was the one of advantages of early treatment by functional appliances. This provided posterior disclusion during protrusive movement for improving functional occlusal and reducing predisposing TMJ dysfunction factor.

However, difference angular was greater than ideal suggestion. According to continuous increasing of condylar guidance from growth after removal function appliances, suggested that it was increased 1.25° per year until the end of growth spurt (4), may be 5-8 degrees. If we kept in position of incisal inclination until finishing of treatment or end growth spurt and the condylar guidance was continue growing, the different of anterior-condylar guidance would be as normal suggestion.

In order to harmonize the anterior guidance and condylar guidance, inclination of upper incisors should be set individually according to their condylar guidance. Condylar guidance was unique to individual and did not remodel significantly over functional appliances treatment. So, average condylar guidance should not be used in treatment planning (49). In Activator and Twinblock therapy, upper incisors were always retraced base on normal inclination, overjet and overbite correction that were not related to individual variation or function. So inclination of maxillary incisors must be planned base on many considerations especially functional relationships and their effect on joint accompany with esthetics, malocclusions correction and stability (41, 59).

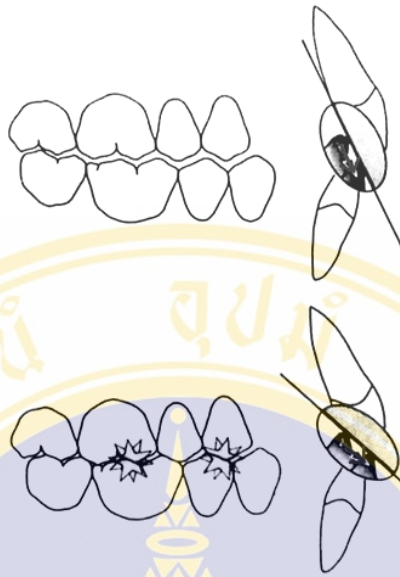

Fig.34 Upper and lower posterior teeth interfere with incisive action of anterior teeth if inclination of anterior guidance is flatter than that of condylar guidance

Effect on Maxilla

Complexity of facial growth and development has been widely discussed in orthodontics literature. Maxillary growth occurred in three ways: through deposition of bone at circum-maxillary sutures, by periosteal deposition of bone on various anatomic surfaces, and by dental eruption producing vertical alveolar bone height (141, 142).

According to the particular cephalometric landmarks used (SNA, A-Ptv, A-HP), the present finding found that no major orthopedic effect exerted on the maxillary skeletal structures. The treatment group demonstrated a small mean reduction of SNA -0.43 ± 1.04 degrees but significantly. A maxillary length was increased 0.65 ± 1.41 mm. after treatment. The control group showed relatively no change in SNA and A-Ptv over observation period but the maxillary length was increased 1.41 ± 1.48 mm. (Fig.35). This suggested that forward movement of point A and maxillary length were slightly restricted as a result of functional therapy. It was possible to clinically alter growth direction and velocity of maxilla. However, when compared the change between the treatment and the control groups, it was no significant difference.

This result was in agreement with many previous studies (10, 13, 122, 143-145). Vargervik and Harvold (14) found that Activator inhibited a horizontal growth of the maxilla by 2 mm.. Panchez et. al. (12) found a mean reduction, although minimal (-0.4 ± 1.0 degrees) in SNA and restricted by 1.7 mm., as did Cura et. al. (122) with -0.7 ± 1.8 degrees. Jakobsson and Paulin (146) indicated that basal areas of maxilla were restrained in their normal forward development by functional appliances therapy. Croft et. al. (147) reported a slight restriction of maxillary growth by a decrease of 0.9° in SNA angle in their mixed dentition patients and concluded that maxillary orthopedic effect of early treatment in their sample produced a 1.2 mm. restraint on a sagittal displacement of point A. Illing et. al. (17) and Birkebæk et. al. (148) stated that, reduction of SNA was due to tipping of maxillary plane backward accounting for a downward and backward movement of point A, thus reducing SNA in present finding did not show any rotation of palatal plane.

In addition, point A was a deep alveolar point rather than a true skeletal landmark. Changes in inclination of the teeth would alter location of this landmark, so anterior

movement of the apices of the central incisors would cause forward movement of point A (17).

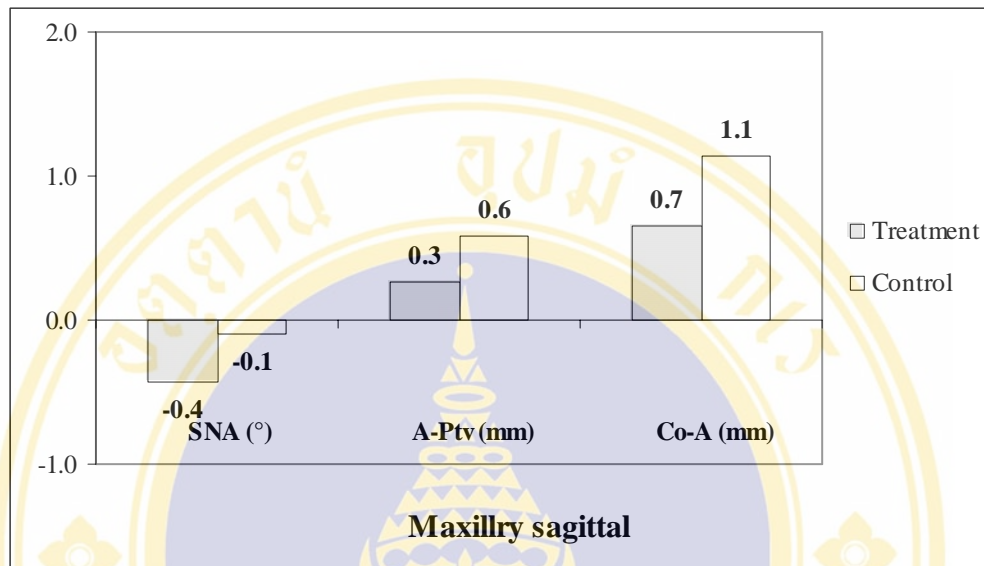


Fig.35 Diagram presented changing of maxillary sagittal relationship over the treatment period (* P<0.05; ** P<0.01)

Effect on Mandible

Complexity of facial growth and development has been widely discussed in orthodontic literature. Mandible increased in size by a combination of 3 growth processes: 1) endochondral bone growth at the condyle, 2) periosteal bone remodeling on the posterior border of ramus, and 3) dental eruption. When evaluated cephalometric, these three mandibular growth processes did not only result in increased mandibular size, but also affected the direction of mandibular growth relative to cranial base (141, 142).

Our findings founded that functional appliance therapy resulted in anterior relocation of point B ($SNB\ 1.04\pm 1.29^\circ$) and point Pg ($SNPg\ 0.96\pm 1.19^\circ$). The increased values of B-Ptv ($1.92\pm 2.21\text{ mm.}$) and Pg-Ptv ($1.95\pm 2.33\text{ mm.}$) supported these findings, demonstrating that the mandible had moved forward as a result of active functional therapy. The control group did not show a mean increased in SNB and SNPg as a result of growth alone. The displacement of point Pg in the treatment group, in comparison with the control group, was probably caused by treatment approach itself since the appliances displaced mandible along the path of incisal guidance (13). Overall mandibular growth changes in our treatment group revealed increasing of condylar growth (Co-Gn) of $4.55\pm 2.34\text{ mm.}$, whilst, increasing of $2.30\pm 1.79\text{ mm.}$ in the control group and $2.97\pm 1.72\text{ mm.}$ more than the control group (Fig.36).

One of the key questions addressed in this study was the effect of Activator and Twinblock appliances on increasing in mandibular length. As the appliance was used only 12-18 hours a day, the threshold for adaptive remodeling in the condyles may not occur in some individuals. When comparing the treatment group with the control samples in present investigation mandibular growth appeared significantly increased, as occurs with the other functional appliances (12, 145, 149). Cephalometrically, there seemed to be increased mandibular growth in sagittal plane, which assisted in correcting Class II malocclusions by virtue forward mandibular growth that was greater than that anticipated from natural growth increments (150).

Our results supported the work of many authors (17, 148, 151) which have reported an increasing in total mandibular length during functional appliances treatment. Evidence from prospective cephalometric studies suggested that mandibular

length increased between 2 and 2.5 mm. more than controls during treatment with functional appliances. A retrospective studies tended only to consider successfully treated cases. These suggested that mandibular length increased by approximately 4 mm. more than controls (152).

Mill and McCulloch (19), who's used of Twinblock appliance, resulted in an average increasing in mandibular length during active treatment. In the post-treatment period, there was a slight reduction in mandibular growth rate, but most of the increasing in mandibular length achieved during treatment was still evident 3 year later.

Birkebaek et. al. (153) in an implant study that featured laminographs of TMJ concluded that the major effects of Activator treatment were increased amount of condylar growth and remodeling of articular fossa. This combination of these effects resulted in permanent anterior displacement of the mandible. Condylar growth during 10-month period of Activator treatment increased 1.1 mm. and redirected 12° in a more posterior direction compared with untreated control. Pancherz et. al. (12) also showed an increased in SNB with functional therapy of 1.6 ± 1.1 degrees and increased mandibular growth by 0.3 mm. per year. Illing et. al. (17) reported condylar growth of 3.3 ± 2.6 mm. in Bionator and Twinblock groups. Chadwick et. al. (151) reported that functional regulator increased mandibular length of 4.2 mm., similar to many investigators finding of 3.3-4.5 mm. (143, 154). These changes were most likely a result of a stimulation of condylar growth. Additionally, a remodeling of the glenoid fossa or condylar position changes within fossa influencing the amount and direction of effective condylar growth could not be excluded (13).

In normal individual of untreated subjects, Baumrind and Frantz stated that, a mandible grew 2-3 mm. per year (155). Björk (103) observed that condylar growth grew 3 mm. per year during childhood period, slightly decreased to a prepubertal minimum and followed by an adolescent spurt peaking growth at 5.5 mm. per year at approximately 14.5 years of age. In longitudinal follow-up study of 21 patients, Hägg and Attstrom (156) observed condylar growth was greater before (11.3 mm. per 3 years) than after the pubertal peak (9.6 mm. per 3 years). Burchang et. al. (157) studied condylar growth between 6 and 16 years of 113 males and 108 females. They found that condylar growth for males ranged between 2.1 and 3.1 mm. per year and for

female was 2.0-2.7 mm. per year. Therefore, these changes of present study were likely to be the result of a stimulation of condylar growth (9, 10, 158).

However, other investigators maintained that using of the functional appliances did not affect a significant increased in mandibular length (80, 111, 146, 159-162). There was a large amount of individual variation in treatment response. For example, Pancherz et. al. (12) evaluated 30 Class II division 1 children in mixed dentition who treated successfully with Activator. The controls were persons of the same sex and similar ages with excellent occlusion. He found that mandibular growth increased by 0.3 mm. per year, but this was not statistically significant. He concluded that the magnitude of mandibular growth was not affected by Activator treatment.

In addition, there was a correlation between mandibular length and ages of the patients ($r=0.48$), indicated that the mandibular growth was related to an increasing age in growing patient. This age-related difference in treatment response has been shown in previous study of functional therapy (111, 143, 163, 164). For example, McNamara et. al. (143) examined a large group of patients ($N=100$) treated with FR-2 appliance of Frankel. Mandibular length increased by 6.4 mm. during a two-year period in the younger group (~8.5 years at the beginning of treatment) and 8.0 mm. in the older age group (~11.5 years). Therefore the timing of starting treatment of functional appliances was important, indicated that a greater mandibular growth response was observed if Class II treatment was initiated during the circumpubertal growth period.

An effect of functional appliances on condylar growth remained a controversial issue (165-167) and mechanisms by which those changes triggered were not completely understood. Several studies have reported a positive response of the condyle to mandibular advancement (165, 167). Some researchers believed that this positive response was actual growth of the mandible (14, 46, 143), while others believed that functional appliances only accelerated mandibular growth, helping it to reached its final size earlier, but not producing a larger size overall (168).

Different theories have been discussed with respect to the mechanism by which the condylar cartilage responds to an altered functional position of the condyle. Such as, alteration in functional position of the superior head of the lateral pterygoid muscle (169), alterations in functional loading of the condyle (60) resulting in changes of the

intracellular cAMP and Ca^{2+} concentration as biochemical signal transducers or pressure induced changes in electric signal (45). An increase in condylar growth has been shown histological in experimental animal studies due to hyperpropulsion of the mandible (84, 135, 165, 167). It has been shown that the proliferation of chondrocytes in condylar cartilage increased, and deposited bone in posterior of glenoid fossa (83).

The mesenchymal cells within articular layer of both condyle and glenoid fossa were main source for bone formation. In an attempt to elucidate the mechanism, mesenchymal cells proliferated and differentiated in response to mandibular protrusion. Rabie et. al. (135) identified a temporal sequence of cellular changes in posterior aspect of TMJ in rats. He found that the mesenchymal cells were found to be stretched and oriented in the direction of the pull. This might trigger the biophysiological path of mesenchymal cells differentiating into bone making cells in TMJ. Recent studies by examining the growth markers such as type X collagen, VEGF and neovascularization related factors at molecular and genetic level, have predominantly confirmed an increased endochondral ossification in condyle of growing rats in response to mandible protrusion (84).

Rabie et. al. (167) studied about functional appliances therapy accelerates and enhances condylar growth, they concluded that forward mandibular positioning accelerated and enhanced chondrocyte differentiation and cartilage matrix formation in the mandibular condyle by accelerating and enhancing the expression of Sox 9 and type II collagen. This enhancement of growth did not result in a subsequent pattern of subnormal growth for most of the growth period, indicating that functional appliances therapy could induce true enhancement of condylar growth.

McNamara and Carlson (165) analyzed TMJ adaptation to protrusive function in monkeys. They sited that adaptive response of the prechondroblastic-chondroblastic cartilage layer of specific regions of the condyle was pronounce in thickness in posterior-superior region. Superior condylar region was not significantly affected by the functional protrusive appliances. Kantomaa (128) explained the increased vertical growth of condyle during the forward pull of mandible in. The adaptive growth of condyle tending to restore its original position in the fossa resulted also in an increase in the height of the ramus on the experimental side. It thus seemed that as the growth

of the condyle was adaptive at least as far as direction was concerned and it tended to maintain its original position in relation to the fossa.

According to Petrovic et. al. (169), the retrodiscal pad effected mandibular growth by means of a biomechanics and a vascular component. The biomechanics component of the retrodiscal pad was probably responsible for the posterior condylar growth direction and the supplementary lengthening of the mandible during functional appliances treatment. As a result of piezoelectric and other effects, an increase in negative charges occurred along the posterior border of the ramus result in producing increased periosteal bone formation and reciprocally increased bone resorption on the anterior border.

Voudouris et. al. (170) reported that, experiments in growing animals with intermittent forward positioning of mandible have also demonstrated increased cellular activity at the prechondroblastic and chondroblastic zones of the condylar head. They suggested that lateral pterygoid muscle activity was a necessary prerequisite for increased condylar growth. They found that appliances insertion and activation were associated with a decreasing in postural EMG activity of the superior and inferior head of the lateral pterygoid, superficial masseter, and anterior digastric muscles. This was remarkable because condylar growth and glenoid fossa growth response were related to the absence of increased postural activity in the masticator muscles investigated. This pointed to specific, non-muscular soft tissues around TMJ playing a direct or indirect role in new bone formation described in the growth of the condyle and glenoid fossa.

Long-term effects of this treatment were disputed and it has suggested that there might be a limited or preordained amount of mandibular growth that could occur in any patient. The effects of the functional appliances were only a temporary acceleration of mandibular growth adaptation, which were followed by subnormal growth (171). The above-mentioned reported a controversy regarding the response of TMJ to mandibular advancement. In particular the length of the treatment period could allow the extra bone to mature before going back to normal levels of growth.

The matrix of newly formed bone was of the same nature as that formed during bone development and bone repair (172). The type of collagen matrix that formed in the human condyle in situations of repair was known to be type III (173). Type III

collagen was the emergency type. It was a good candidate for the repair of bone matrix. It was weak of cross-links and required stabilizing the collagen molecules to form the collagen fibrils of the bone matrix. The cross-links were weaker than those present in type I collagen matrix. This make its removal at a later stage and its replacement by the more stable type I collagen matrix. Therefore, it was possible that in cases of early removal of the appliance, the process of maturation of the emergency type of bone to the more stable type I collagen matrix was not allowed to take place. Therefore, the emergency type of bone with the inherently weak type III collagen matrix would not be stable enough to resist the forces of mastication and normal function (171).

Therefore, a stability of newly formed bone in the condyle and the glenoid fossa in response to mandibular advancement could be influenced by whether the clinician allows the newly formed bone to remodel to the more stable type of bone in patient treated with functional appliances (174). According to Chayanupatkul et. al. (171) and those of Hägg et. al. (174), it was safe to recommend that the period of mandibular advancement should be increased from that commonly reported period in the literature of 5-7 months (112, 175) to double that period of treatment to allow for the newly formed bone to mature into more stable bone. This should offer the mandible a chance to resume growth at nature levels after complete of treatment.

The significant increased of the gonial angle ($1.04 \pm 2.52^\circ$) in the treatment group may be contributed to a change in a location of articulare. Because of the condyles were positioned downward and slightly forward at the end of treatment. Supported by Animal experiments in mandibular repositioning and functional appliances studies that gonial angle was changed due to a remodeling in response to altered activity and tone in the masseter-internal pterygoid muscle sling (7, 176).

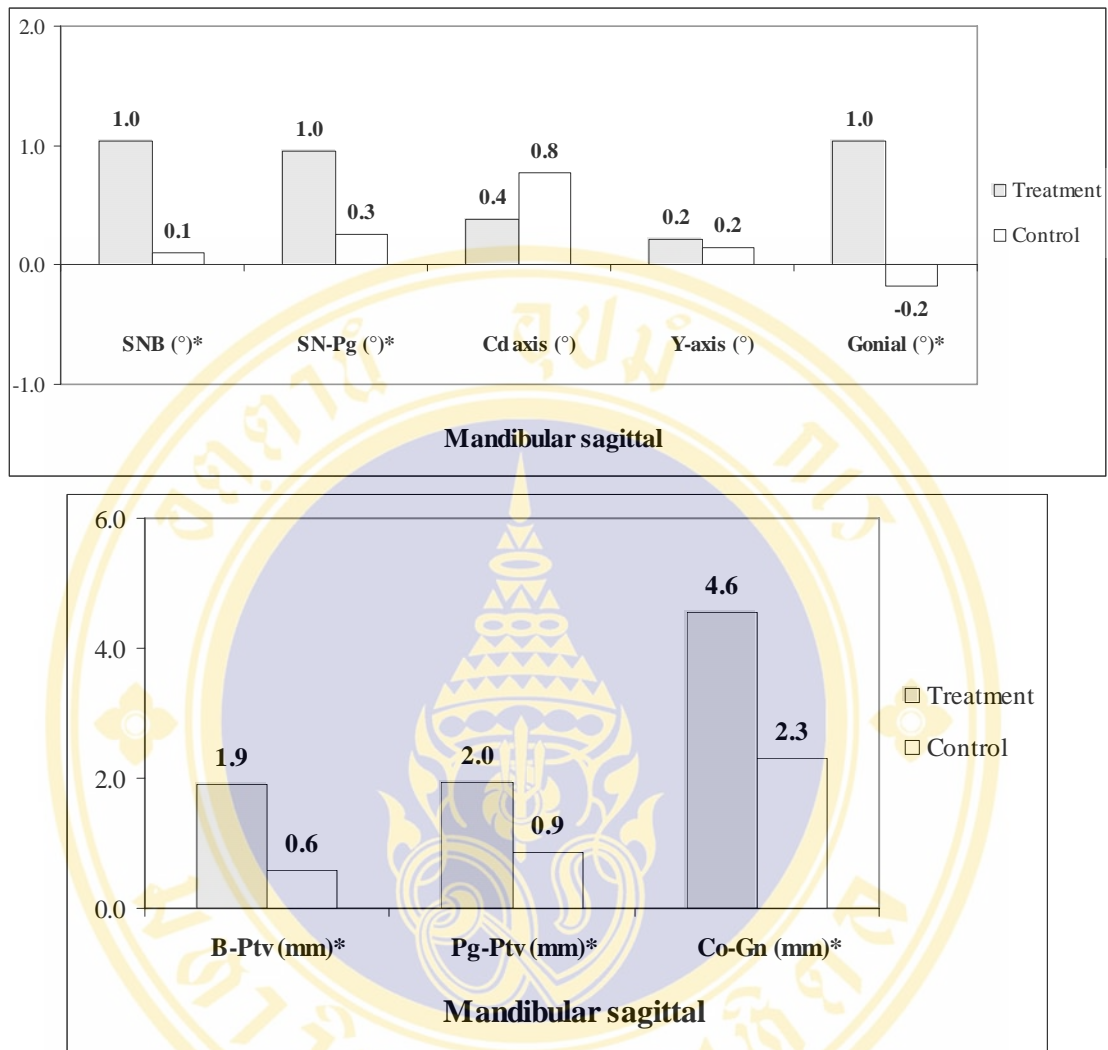


Fig.36 Diagram presented changing of mandibular sagittal relationship over the treatment period (* P<0.05; ** P<0.01)

Effect on Maxillary-Mandibular Relationship

Changes in value of ANB would be suggested that Activator and Twinblock appliances were effective in reducing the sagittal intermaxillary relationship. In our results, ANB was decreased $-1.47 \pm 1.32^\circ$. This was mainly due to forward advancement of mandibular structure (SNB 1.04°) and less important of maxillary growth (SNB -0.43°). Wits was reduced -3.20 ± 3.55 mm. (Fig.37). ANB and Wits of the control group did not change significantly. These suggested that functional appliances could correct skeletal discrepancy of Class II to be Class I relationship. However, reducing of ANB was lesser than other investigators's findings, such as, Coza et. al. (11) reported of -2.14° (SNB 1.64° , SNA -0.50°) after treatment with Activator in 21 months. Trenouth (110) reported a correction of ANB -2.6° was mainly due to increase in SNB 2.0° with small reduction in SNA -0.6° due to restraint of forward maxillary growth. The difference may be due to a longer treatment period for enhancement of mandibular growth, the appliances design and also patient cooperation.


In the present study, mandibular plane (SN-MP) and palatal plane (SN-PP) did not showed any rotation significantly, similar to some previous studies (10, 145, 177, 178). The factors may be enough bite opening used with our appliances, the enough extrusion of molars contributes to increase in vertical condylar growth. In some cases which were normodivergent that we did not want to change in their configuration, so the functional appliance should be constructed carefully.

However, others (19, 82, 179) have reported small but significant, increased in mandibular plane angle during treatment with Activator and little or no change during treatment with functional regulator. Chabre (180) described Activator appliances as creating a force system passing behind the centre of resistance of both maxilla and upper alveolar process. This generated negative moments that resulted in backward rotation of both mandibular and palatal planes. Mills and McCulloch (19) reported slightly increasing of mandibular plane (1.0°) and posterior facial height after treatment with Twinblock. Presumably factors, because of the lesser bite opening used with their appliances, the smaller extrusion of molars, and downward displacement of upper facial skeleton during treatment. Birkbeak et. al. (153) reported that anterior

facial height increased by 1.1 mm. and mandibular plane increased 2.5°. Contrary to mandibular plane angle slightly decreased in the controls group.

There was no mean change in intermaxillary plane angle in this finding (Fig.38). In contrary to some investigators reported difference results. Ill et. al. (17) reported a decrease -1.5 ± 1.5 degrees in Twinblock group. Birkebæk et. al. (148) showed different results, reported an increasing of 2.5 degrees in their Activator group. The control group showed a similar finding in this variable.

Occlusal plane was backward rotated 1.12 ± 4.26 degrees (Fig.38) significantly after treatment. Occlusal plane rotation may be due to more extrusion of lower molars than upper molars, while the maxillary-mandibular skeletal did not show rotation.



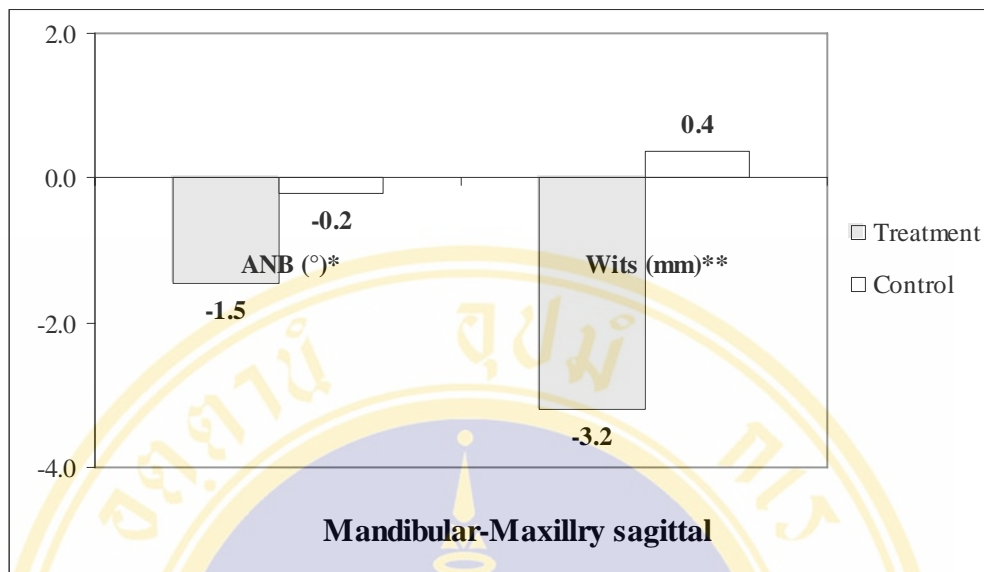


Fig.37 Diagram presented changing of mandibular-maxillary sagittal relationship over the treatment period (* P<0.05; ** P<0.01)

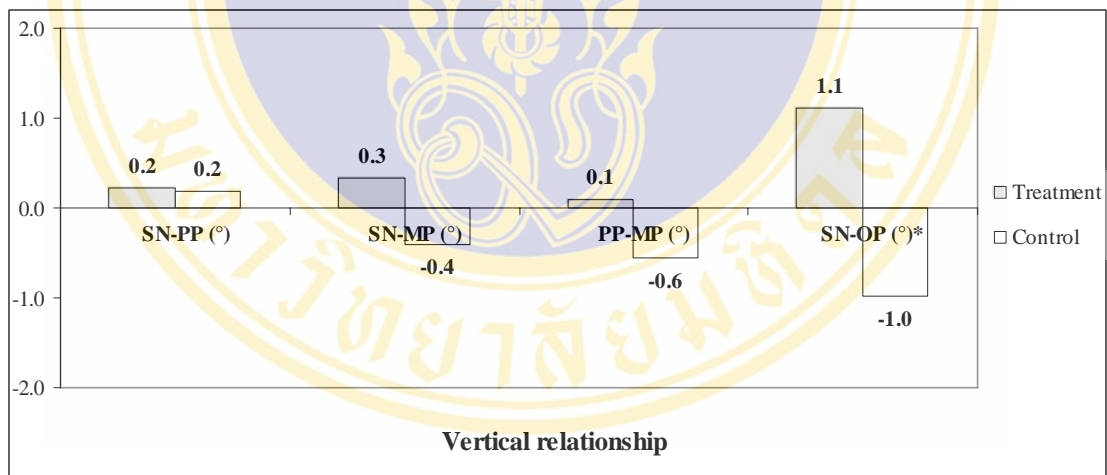


Fig.38 Diagram presented changing of vertical relationship over the treatment period (* P<0.05; ** P<0.01)

Effect on Facial Height

Anterior and posterior facial heights played an important role in facial balance. They defined a direction of mandibular rotation. In normal occlusions, a posterior facial height developed more than anterior facial height. Orthodontics treatment must be in equilibrium with normal growth process to be effective, stable and compensation for unpleasant facial patterns (107). In Class II division 1 presented short anterior facial height, so objectives of treatment were to increase anterior facial height and improved facial proportion.

The treatment group and the control group showed increasing in lower anterior facial heights of 3.06 ± 1.58 mm. and 1.11 ± 0.93 mm. respectively (Fig.39). An increasing of lower anterior facial height caused of downward displacement of maxilla and mandible, and extrusion of incisors. That contributed to extrusion of molars and increased of vertical condylar growth.

This finding corroborates the results of many studies. Ill et. al. (17) reported an increase of 2.7 ± 1.7 mm.. Croft et. al. (147) and Pancherz (12) observed a similar increase of 1.8 mm. in lower facial height during treatment. However, it was disagreed with other investigators (145, 181) that there was no significant effect on lower facial height after therapy or at the end of two-phase treatment. McNamara (109) has reported that without treatment an increase of about 1 mm. per year in lower facial height could be expected. In addition, from this study, an increase of lower anterior facial height effected the improvement of the facial proportion (LAFH/AFH) (54.38 %) to be Thai norm (55.84 %) (182).

Total anterior facial height in this study was increased 4.85 ± 2.13 mm. in the treatment group and increasing of 2.40 ± 1.72 mm. more than controls (Fig.39). Other studies showed that treatment results were increased between 2.5 and 4 mm. more than controls (152). Cura et. al. (122) showed an increase in total with Activator of 4.6 ± 1.8 mm.. Clark (16) showed a significant increase in total vertical face height, being 6.29 mm. in males and 4.93 mm. in females, over a 12-month period.

Posterior facial height (Go-S) showed an increasing in both treatment and the control groups. However, no difference between the group was found, indicated that the treatment did not effect the posterior facial height when comparing with the controls (Fig.39). This finding was similar to Almeida's finding (145). The increased

of posterior facial height might be effected by extrusion of molars and increased in vertical condylar growth.

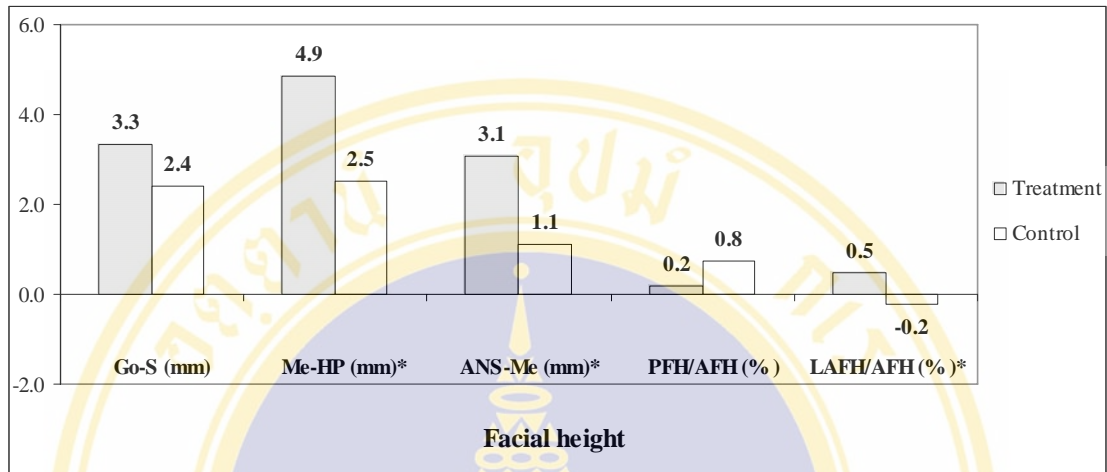


Fig.39 Diagram presented changing of facial height over the treatment period.

(* P<0.05; ** P<0.01)

Effect on Condyle and Glenoid Fossa Displacement

Orthopedic procedures aimed at improving profile of the retrognathic mandible by protruding mandible were dependent on mandibular condylar growth and displacement of glenoid fossa. The condyle, a well established mandibular growth site (183), served as a primary focus of functional orthopedic therapy to stimulate mandibular growth (9, 14, 80, 114). Because a glenoid fossa determined posterior/superior limit of the mandible, it held important implications for mandibular displacement (115, 162). Therefore, when planning skeletal corrections, posterior fossa displacement should be added to any existing anterior-posterior discrepancies and future growth deficiencies. Both condylar growth and fossa displacement must be evaluated to understand mandibular growth changes occurring with or without therapy.

The purposes of this study, the first was to test the validity of a view that has long existed that mandibular protrusive appliances caused mandible and condyles to take forward and downward position after treatment. The second was to clarify the mode of action of protrusive appliances on glenoid fossa displacement, and thus contribute to correcting skeletal Class II malocclusions.

The present findings indicated that mandibular protrusive appliances did not displace the condyles and glenoid fossa significantly after treatment as compared with the controls (Fig.41). To confirm the displacement of glenoid fossa and condyle, the articulare and condylion were used to draw conclusions regarding glenoid fossa displacement (9), the results confirmed that no significant displacement of glenoid fossa and condyle.

The findings were supported by some investigators (184), whereas which refute previous studies that report anterior and inferior positioning of the condyle after treatment. However, glenoid fossa was displaced slightly downward (~0.8 mm. /year) both in treatment and the control groups. This findings were similar to Katsavias's study (8) that no significant modification of glenoid fossa for the correcting of Class II malocclusions treated with functional appliances for treatment period 1.33 years using lateral tomograms. Pirttiniemi et. al. (48) reported, the location of the roof of the fossa seemed to have remained unchanged in relation to clival plane. Sahn and Witt (185), found that the posterior wall of glenoid fossa did not remodel anteriorly in association with anterior dislocation in condylar fractures. Whereas the fossa marked

changes in the eminence were observed. Thus they assumed that the location of the posterior wall was related to the morphologic factor, whereas the eminence was more under functional influence.

A natural growth of glenoid fossa was downward and backward direction from sella-nasion plane facial growth. Buschang and Santos-Pinto (114) found that the glenoid fossa in growing humans grew backward between 1.8 and 2.1 mm. over a 4-year period. Birkbak and Dahan et. al.'s studies (9, 186) reported that in untreated Class II cases. The glenoid fossa was displaced backward and downward, whereas cases treated with an Activator showed a forward and downward displacement.

In animal studies, such as monkeys (7, 134), rats (135) and sheep(136), the results of these studies showed that, there was bone deposition on anterior surface of postglenoid process. Which indicated that the glenoid fossa was displaced forward occurred and the fossa became flatter as an adaptation to chronic anterior repositioning of the mandible. Flattening and forward remodeling of the fossa may happen as a result of increased pressure on the eminence. However, it was not significant occurring with the present findings.

On the contrary, other researchers described posterior reposition of the glenoid fossa during growth (115, 162, 187). Argonin and Kokich (115) studied displacement of the glenoid fossa of growth during treatment by lateral cephalograms, the results showed that articulare and fossa was displaced posteriorly and inferiorly during craniofacial development. Popovich and Thompson (187) showed posterior and inferior movement of articulare in patients from Burlington growth study. Baumrind et. al. (162) measured the change in position of the glenoid fossa in four groups of orthodontics treated patients. They also reported a posterior repositioning of the glenoid fossa, but they did not find a significant difference in the amount of change between groups.

Although our finding showed that the glenoid fossa and condyle did not displace forward and downward as a result of treatment with protrusive appliances. However, this finding by no means excluded the relative contribution of the glenoid fossa and condyle to the resolution of a skeletal Class II problem treated with protrusive appliances. It has been shown in normally during craniofacial growth, as in the control samples, that the glenoid fossa and condyle were displaced downward and backward

(3-4 mm. over the 4-year periods) during natural facial growth and development (114, 187). Since our results found no significant increase in distance of glenoid fossa and condyle to vertical reference line (Ptv plane) and mean values of backward displacement of glenoid fossa and condyle in the treatment group were less than the control group. Therefore this could be interpreted as a restriction of the glenoid fossa and condyle from continuing its natural growth direction. This restriction of temporal bone (fossa) growth might assist the explanation of how unexpected Class II corrections occur in treatment. It may be assumed that the articular eminence and glenoid fossa was affected by functional appliances (Fig.40).

In addition, the appliances needed to be worn for a prolonged period of time, usually 1.5 to 2 years to ensure complete condylar adaptation following its initial displacement from the fossa (6).

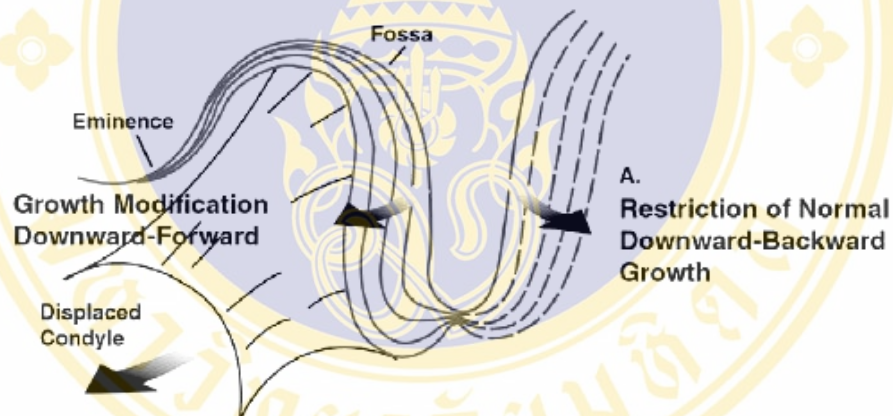


Fig.40 Illustration of orthopedic treatment. Solid line show forward and downward growth due to treatment. Natural growth (dot line) was backward and downward direction

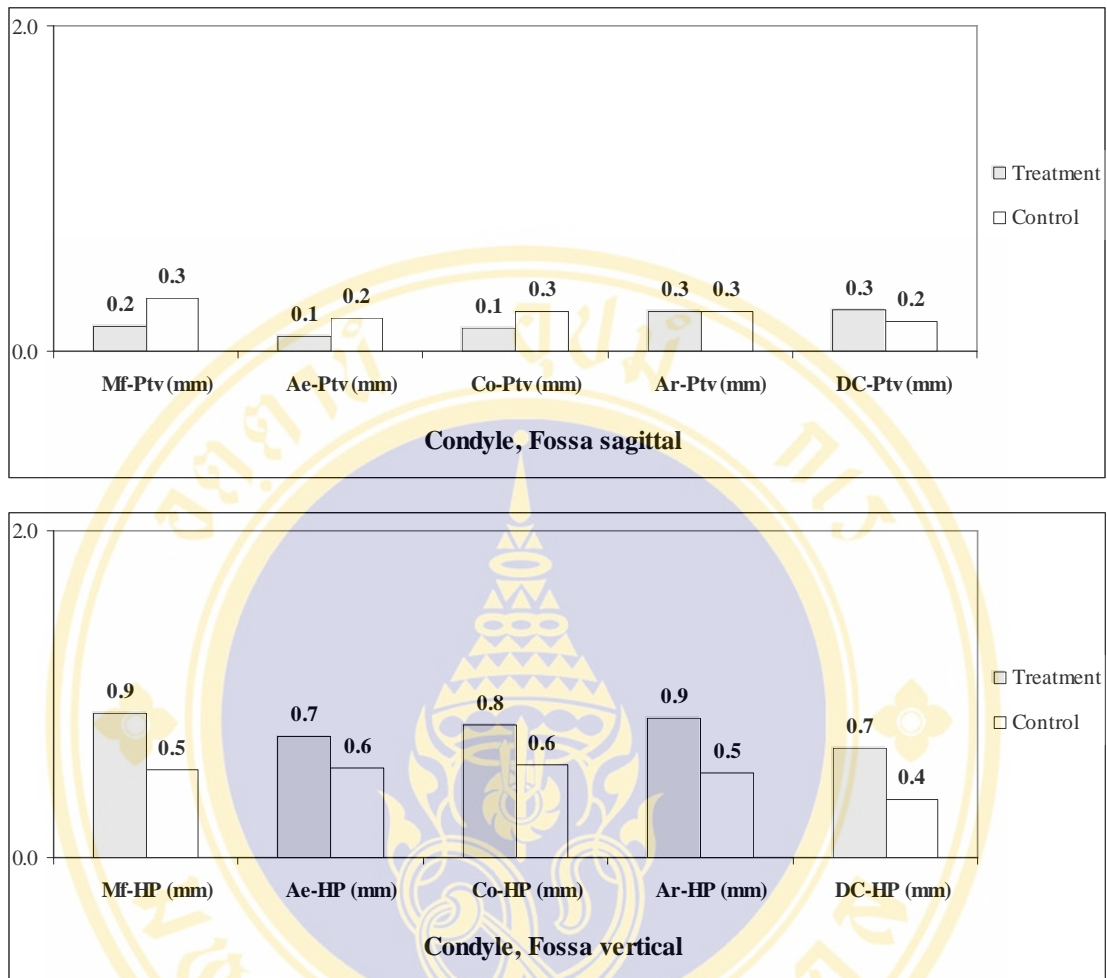


Fig.41 Diagram presented changing of glenoid fossa and condyle displacement over the treatment period (* P<0.05; ** P<0.01)

Effect on Dento-alveolar

Maxillary incisors

This study found that inclination of upper central incisor related to FH plane was 57.43° and 63.23° of pre- and post-treatment respectively. When compared with a normal incisal inclination, Wattanatchariya (41) reported the long axis of upper central incisor of normal occlusion related to the FH plane was 65.6° . Thompson (26) suggested that a pleasing appearance was provided when the angle of the maxillary incisors to the FH plane was about 72° . This indicated that before treatment, upper incisors were very proclined, and after treatment inclination was close to Thai normal incisal inclination, however it was too more procline than the suggestion.

Treatment group demonstrated a mean reduction in the proclination of upper incisors (5.80 ± 3.22 degrees) and relocation -1.34 ± 1.68 mm. lingually (Fig.42). This was an expected treatment outcome of functional appliances therapy due to their Class II 'traction effect'. Illing et. al. showed a reduction in the proclination upper incisors of 9.1 ± 3.22 degrees. The findings supported those of Clark (16). In this study, upper incisors were retroclined 5.80° and retracted -1.34 mm. lingually in the treatment group. Trenouth (110) reported the effect of Twinblock on upper incisor retroclination -14.37° .

Lund and Sandler (188) incorporated a labial bow into their appliances and this account for the greater retroclining effect found by these authors. However, it was clear that upper incisors became retroclined, even in the absence of a labial bow. Therefore in case with up righting incisors, torque control was required for limiting retroclination of maxillary incisors.

As in the present study, Lund and McCulloch (188) and Trenouth (110) achieved significant upper incisor retracted by using an upper labial bow. In contrast to Mill and McCulloch (19) who did not use a labial bow, they were found little change in upper incisor position. This showed that the differences in outcome appeared to be related to appliance design.

Conversely, upper incisors of the control group were proclined -1.05 ± 1.49 degrees and forward 1.49 ± 1.25 mm. labially (Fig.42) after observation period. It was possibly due to a continued retroclining effect of the lower lip lying lingual to upper incisors. The progressive labial tipping of upper incisors in the control group over

observed period was the one reason that we should treatment of Class II division 1 malocclusions early.

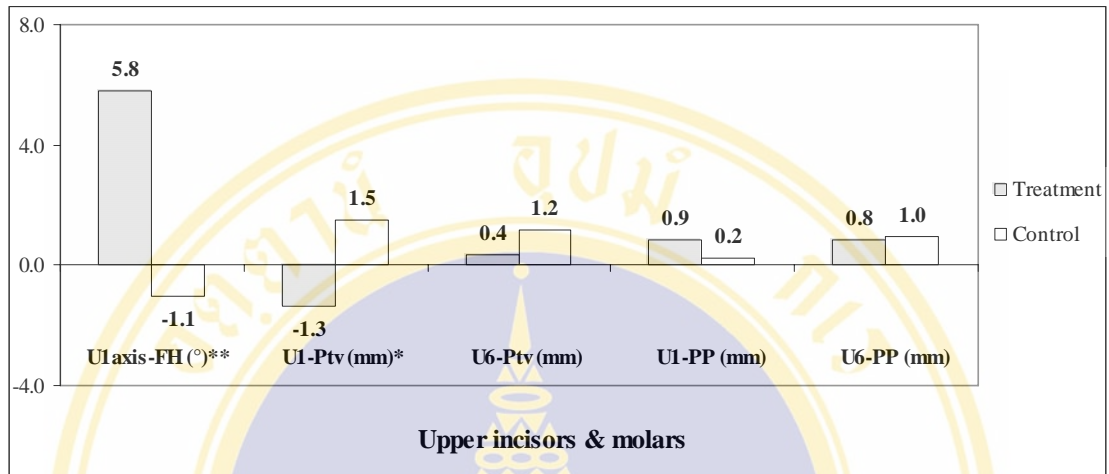


Fig.42 Diagram presented changing of upper incisors and upper molars relationship over the treatment period (* P<0.05; ** P<0.01)

Mandibular incisors

In the treatment group, the lower incisors were proclined 2.83 ± 3.46 degrees and moved forward 3.08 ± 2.07 mm. labially (Fig.43). The degree of mandibular incisor proclination found in this study was closed to some reports (178). Illing et. al. (17) reported the proclination of lower incisors was 2.0 ± 7.3 degrees in Twinblock group. Clark (16) reported a similar movement of the lower incisors during functional appliance therapy. Lund and Sandler (188) reported a mean mandibular incisor proclination of 8° during treatment. In contrary to Trenouth's (110) finding that Twinblock had no effect on lower incisor proclination. He explained, due to using of ball clasps or acrylic labial bow that provide less rigid retention in the lower labial segment than Southend clasps.

Proclination of the lower labial segment during treatment was undesirable in most cases because it contributed to overjet reduction and limited the potential for further skeletal growth. The lower incisors were susceptible to relapse. Subsequently fixed appliance treatment would be more likely to involve extractions as space required if the lower incisors were to be retracted to their pre-treatment position (152). Currently, there were no clinical data on the effects of lower incisors capping on controlling lower incisors movement during treatment.

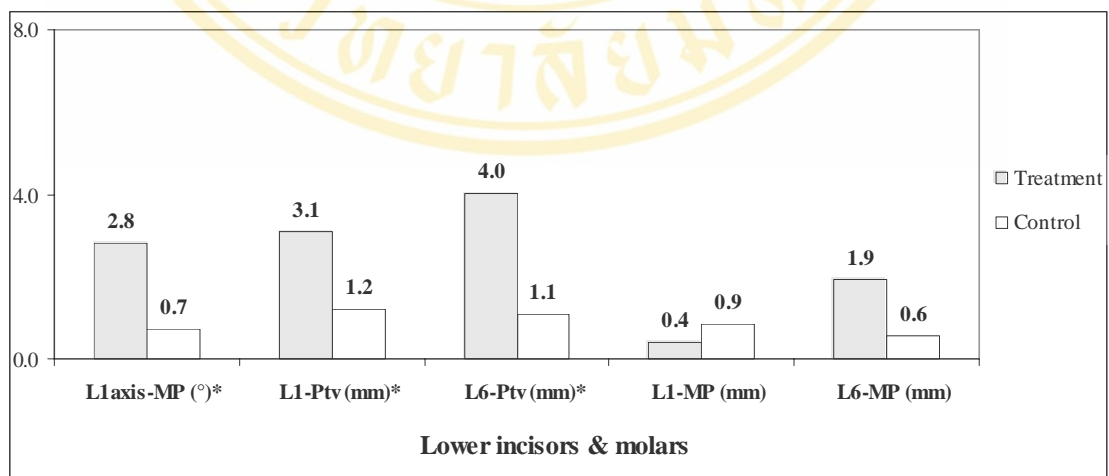


Fig.43 Diagram presented changing of lower incisors and lower molars relationship over the treatment period (* $P < 0.05$; ** $P < 0.01$)

Inter-incisal relationship

Our results presented that overjet was decreased in the treatment group (-4.42 ± 2.06 mm.) and slightly increased in the control group (Fig.44). Overjet was reduced -4.42 mm. due to upper incisors tipping lingually combined with lower incisors flaring by -2.50 mm. and orthopedics effects by -1.92 mm.. Some investigators have observed significant dento-alveolar changes with functional appliances treatment (10, 12, 159). A Class I occlusion was achieved through distal tipping of the maxilla teeth and a mesial movement of the mandibular dentition. Pancherz (12) found that more than 70% of the overjet was corrected by upper incisors tipping lingually 50% (2.5 mm.) and 22% (1.1 mm.) by lower incisors flaring. Harvold and Vargervik (80) observed that the appliances also caused 1.4 mm. of maxillary incisor lingual tipping and 0.5 mm. of mandibular labial tipping. They concluded that the appliances achieved a Class I occlusion by inhibiting maxillary dento-alveolar mesial development, while encouraging mandibular dento-alveolar mesial and vertical development.

Interincisal angle of the treatment group was increased $2.55 \pm 4.76^\circ$ and $3.88 \pm 2.58^\circ$ comparing with the controls (Fig.44). The angle was mainly increased by retroclination of upper incisors. Down (105) recorded an average interincisal angle of 135° , because of this angle the anterior teeth are proprioceptively sensitive and serve to redirect the path of closure to normal pattern. In Class II division 1 malocclusions, the incisors were too proclined and the interincisal angle was more acute than normal. Therefore proprioceptive guides to bring the teeth together in centric occlusion would not be established. After treatment, the incisor inclination and interincisal angle were close to normal, then normal movement pattern would be occurred.

Class II traction forces were transmitted to the maxillary dentition during functional appliances treatment. These forces transmitted to upper incisors as they were brought under the controls of the lower lip during mandibular protrusion. This resulted in palatal movement of the incisors. Overjet correction was often taken as the end point of functional appliances treatment. Disadvantage of retroclination as overjet correction was incisor movement rather than mandibular growth (152).

Our results of therapy presented that overbite was decreased in the treatment group -2.28 ± 1.74 mm. (Fig.44). It has been suggested that excessive horizontal and

vertical overlap of the anterior dentition predisposes an individual to the development of mandibular dysfunction (189, 190). Ricketts (191) and Roth (192) suggested that overlap of the anterior was responsible for the development of mandibular dysfunction. Therefore, reduced overbite and overjet in Class II division 1 malocclusions by functional appliances would reduce predisposing factor of TMJ dysfunction.

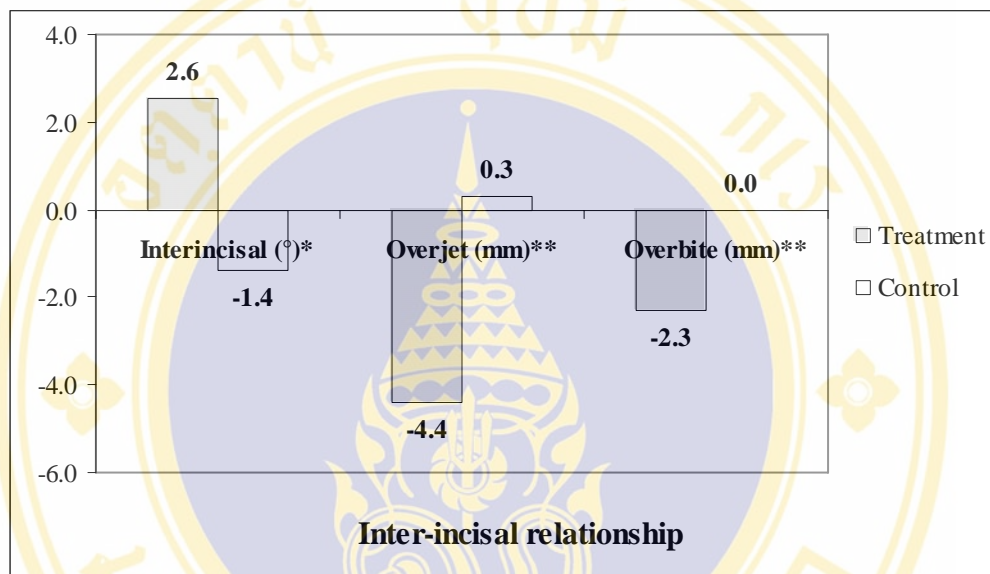



Fig.44 Diagram presented changing of interincisal dental relationship over the treatment period (* $P < 0.05$; ** $P < 0.01$)

Effect on Soft Tissue

Major objectives of this study did not include assessing the effects of functional appliances treatment on facial soft tissue. We could also suggest soft tissue changes that: improved profile, reduced facial convexity, reduced mentalis hyperactivity, forward chin position and protruded lower lip. The changes of soft tissue appeared to be correlated to the underlying skeletal changes. The lower lip became more protrusive. This may be related to favorable mandibular growth and proclination of the mandibular incisors during treatment, which most found in these patients.



Correlations among Anterior Guidance, Condylar Guidance and Skeleto-dental Relationships

Correlation among Anterior guidance and Condylar Guidance (Table 11)

The orbit of the incisal point during protrusive movement was guided by the lingual surface of upper incisors. This was termed anterior guidance. For the health of dynamic and static occlusion, TMJ and anterior teeth, which were called condylar and anterior guidance, must be correlated in harmony (23). The lack of harmony between anterior and posterior guidance during mandibular excursions may be contributory to TMJ dysfunction (22).

There was positive correlation of anterior guidance (AG-FH) with condylar guidance (CG-FH) ($r=0.32$, $P<.05$) in both pre-treatment. After treatment the correlation was higher than before treatment ($r=0.40$, $P<.01$) (Table 11). This finding was supported by gnathologic concept that a fully balanced occlusion as ideal occlusion with anterior guidance conform to the condylar path. Furthermore it was found like many investigators (1, 22-25, 32, 34, 41). Wattanatchariya (41) reported significant correlation among anterior guidance and condylar guidance in normal occlusion ($r=0.283$, $P<.01$). Bell and Harris (24) suggested that the angle of the articular eminence and lingual surface of the maxillary incisor are strongly correlated.

This data also supported the anthropologists' long-held principle of a mutually protected occlusion, in which the posterior and anterior determinants were in harmony (1, 32). Granados (42) studied the relations of articular eminence and occlusion; he found that loss of anterior guidance as displayed in severe attrition was accompanied by resorption of the articular eminence, making it more shallow and complete flat. McHorris (32) suggested that the lingual area and shape of the maxillary incisor reflected area and shape of articular eminence. Weinberg (193) reported that a larger condylar guidance angle would appear together with a larger incisal guidance angle.

However, it was not agreement with some investigators (28, 35, 64, 140, 194-196). Anterior guidance and condylar path were considered to be independent factors. Ogawa et. al. (194) suggested that the influence of the incisal and condylar guidance on the protrusive movement path varied according to kind of tooth and gender of the subjects. Darendeliler et. al. (189) cited that incisal and condylar paths were not parallel, whereas the condylar path was convex and the anterior guidance was concave

and a linear relationship between both could not be expected. According to our results, functional appliances therapy could also increase the correlation of the two guidances and possibly improved smooth disclusive protrusion.

There was high positive correlation of anterior guidance (AG-FH) with upper incisors inclination (U1axis-FH) ($r=0.98$, $r=0.98$, $P<.01$) in both pre- and post-treatment respectively. From this finding, the steepness of anterior guidance could also be assessed from inclination of upper central incisors. There was positive correlation of condylar guidance (CG-FH) with condylar axis (Cd axis-FH) ($r=0.27$, $r=0.33$, $P<.05$) in both pre- and post-treatment respectively. So, a steepness of condylar guidance could also be roughly assessed from the condylar axis. This assessment method was suggested by Wattanachariya's study (41).

When evaluating a position of the maxillary incisors during orthodontic diagnosis and treatment planning. It may prove necessary to consider also the incisor's relationship to condylar guidance slope in order to allow for harmonious mandibular excursions. Such as in patient with steep condylar guidance, upper incisors should be retracted to establish steep anterior guidance during treatment.

The difference of anterior-condylar guidance (AG-CG) correlated positively with anterior guidance ($r=0.78$, $r=0.81$, $P<.01$) in pre- and post-treatment respectively. While it correlated negatively with condylar guidance ($r=-0.34$, $P<.01$) in post-treatment. The reason was that anterior guidance was steeper than the condylar guidance in all groups.

Correlation among Anterior Guidance, Condylar Guidance and Skeleto-dental Relationships (Table 11)

Condylar guidance (CG-FH) was correlated positively with age in pre- and post-treatment ($r=0.38$, $P<.05$), even though all samples had about same age range. Previous investigations have shown that most of the fossa and condyle growth were completed at an early age (4, 68). Therefore it might reflect continued growth at the TMJ at older ages.

Whether an anatomy of TMJ varied with facial morphology and type of occlusion was still debatable. Rickettes (197) found no difference in anatomy of TMJ between persons with Class I malocclusions with Class II malocclusions, while the height of the tubercle was less in person with Class III malocclusions. Several authors have found a correlation between overbite and height of the tubercle and being greater in deep bite subjects (64). Ingervall (64) studied inclination of condylar path on movement of the mandible from intercuspal position to protrusion in 7 to 10 year-old children and adults comparing with variables of facial morphology. They concluded that a marked inclination were associated with a rectangular face, i.e., with a parallelism of occlusal plane, mandibular plane, large posterior facial height and small gonial angle. A small inclination was found in triangular profile. So, there was controversy of the correlation of TMJ and skeleton-dental morphology.

Correlation between anterior, condylar guidance and sagittal skeletal relationships

There was a negative correlation of anterior guidance with SNA ($r=-0.28$, $P<.05$ and $r=-0.42$, $P<.01$) and SNB ($r=-0.33$, $r=-0.57$, $P<.01$) in pre- and post-treatment respectively. In our findings did not find any correlation between condylar guidance and ANB. This finding was similar to Wattanatchariya's study (41), and agreement with Bibby (63) and Goldman (198) that skeletal type II or prognathic maxilla had relatively retroclined upper incisors to compensate the skeletal discrepancy. The correlation of anterior guidance with SNB supported the compensation mechanism of skeletal discrepancy. Many investigators (39, 41, 62, 199) reported that Class II malocclusions had steep articular eminence and Class III malocclusions had shallow angle of articular eminence. Nagata et. al. (200) reported flatter condylar path in the reverse bite group. They suggested that the articular fossa with skeletally based

anterior reverse bite was flatter than those of normal occlusion. Takahashi et. al. (201) reported that the most inferior points of the articular fossa of adults with mandibular prognathism were located more anteriorly than in adult with normal occlusion. A curve of the slope of their articular tubercle was also flatter than normal. Iwakata (202) reported that a sagittal inclination of the condylar path in skeletal Class III malocclusions was gentler than normal during protrusive excursion. Ikai et. al. (66) measured dry skull and reported a negative correlation between angle of eminence and ANB angle. They suggested that a steeper middle angle of the eminence was related to protrusive maxilla or protrusive mandible.

However, other investigators did not agree with this finding. Some investigators reported that there was no correlation of condylar guidance with any sagittal skeletal relationship. A steepness of the eminence may be influenced during growth and development by the position of the teeth in arches, skeletal relationships and the muscle activities. So, vary malocclusions was different in articular fossa growth pattern. Thompson (59) explained the indirect effect of skeletal discrepancy on inclination of the anterior teeth that muscular abnormalities may lead to inadequate muscle forces being directed on the teeth. Therefore the proclination upper incisors may due to an incompetent lip seal and tongue producing a forward force on upper incisors. Ingervall (64) found that a marked inclination of the condylar path associated with prognathism facial type and a small inclination of the condylar path associated with retrognathism.

Correlation between anterior, condylar guidance and vertical skeletal relationships

Condylar guidance showed negative correlation with gonial angle in both pre- and post-treatment ($r=-0.54$, $r=-0.38$, $P<.01$ respectively), correlated with SN-MP, PP-MP in pre-treatment ($r=-0.36$, $r=-0.45$, $P<.01$ respectively), and showed positive correlation with PFH/AFH in pre-treatment ($r=0.34$, $P<.01$). By the way, the steep condylar guidance related to small gonial angle, anterior rotation of mandible, the more horizontal the occlusal plane, deep configuration and brachycephalic facial type.

The difference of anterior-condylar guidance correlated positively with SN-MP ($r=0.41$, $r=0.58$, $P<.01$), PP-MP ($r=0.44$, $r=0.58$, $P<.01$), SN-OP ($r=0.44$, $r=0.58$, $P<.01$) and correlated negatively with PFH/AFH ($r=-0.37$, $r=-0.49$, $P<.01$) both in pre-

and post-treatment. By the way, the more difference of anterior-condylar guidance related to obtuse gonial angle, posterior rotation of mandible, open configuration and dolichocephalic facial type. This relation was contrary to condylar guidance, the reason was the decreasing of condylar guidance, the increasing of the difference. This finding was closed to many studies (41, 49, 61, 64, 65).

Kantomma (61) supported the finding that a steep inclination glenoid fossa was correlated a rectangular shape of the mandible, small angle between ramus and corpus of mandible. Conversely, a flat fossa configuration was associated with obtuse shape of mandible. The shape of the glenoid fossa had a significant role in the direction of condylar growth and mandibular morphogenesis. A steep articular eminence inclination directed vertical growth of condyle, led to rectangular shape and anterior rotation of mandible. In the same way, a flat glenoid fossa configuration would influence posterior growth of condyle and led to posterior rotation of mandible. Ingervall (64) and Langer (203) have reported similar finding that the condylar path was pronounced in hypodivergent patients and less marked in hyperdivergent patients.

A hypothesis that the shape of the glenoid fossa effected growth direction of the mandible was supported by the assumption of the adaptive condylar growth (183). Cohlma et. al. (65) and Ingervall (64) also found that the patient with open configuration or vertical growth pattern related to shallow glenoid fossa and flatter condylar path. It may be related to shallower anterior guidance during protrusive functional typically associated with open bites and vertical growth patients. They sited that the flat condylar guidance related to protrusive movement of mandible. If this hypothesis was correct, the functional appliances may lead to flatten articular eminence or reduced condylar guidance. However the mechanism implication was not clearly understood.

According to that inclination of the condylar guidance played a role in direction of condylar growth and thus in the morphogenesis of the mandible (61). Specifically, it has been reported that a steep or flat articular eminence inclination directs vertically or posteriorly, respectively. On the basis of our finding, the direction of condylar growth also did not be changed by using of functional appliances.

Correlation between anterior, condylar guidance and dento-alveolar relationships

Anterior guidance had negative correlation with overjet ($r=-0.57$, $P<.01$) in pre-treatment. Similar to Okeson's (23) and Wattanatchariya's (41) finding that when the horizontal overlap increased, the anterior guidance would decrease. Therefore after treatment, overjet was decreased, anterior guidance would be increased. Okeson's (23) and Wattanatchariya's (41) also found that anterior guidance had positive correlation with overbite. But we did not find any significant correlation in our study.

There was relation between condylar guidance and overbite ($r=0.38$, $P<.01$ and $r=0.35$, $P<.05$) in pre- and post-treatment respectively. Many studies (22, 41, 64, 199) were found as the same results. Cohlma (65) sited that patients with anterior open bite had a tendency to smaller articular eminence slope angle (50.06°) and steeper angle (58.44°) in deep overbite. However Sato et. al. (138) found that there was no association between the magnitude of articular eminence slope angle and overjet or overbite.

Summary Treatment Effects and Clinical Implications

Activator and Twinblock appliances were popular appliances for treatment of Class II division 1 malocclusions because of their high patient acceptability and their abilities to rapid treatment changes. The findings suggested that correction of Class II division 1 malocclusions with the Activator and Twinblock appliances was achieved by a combination of significant dento-alveolar changes as well as by maxillo-mandibular skeletal effects. The appliances worked principally by inducing dento-alveolar changes with a small amount of favorable skeletal change. Changes in soft tissue tended to accompany hard tissue changes.

To summarize, it appeared that functional appliances achieved sagittal correction in Class II division 1 malocclusions predominantly by dento-alveolar changes. Mandibular growth enhancement effect was statistically significant. Maxillary restraint did not show significantly in our study. However, it was questionable if these changes were clinically relevant. Treatment result was provided disclusive occlusions of posterior teeth by steeping anterior guidance harmoniously with condylar guidance. Overjet and overbite were corrected through a combined of maxillary and mandibular orthopedic effect with maxillary incisor lingual tipping and mandibular incisor labial tipping. Treatment also associated with an increase in the vertical facial dimension, which advantaged in patients with short facial height.

For now, based on some available evidence, that functional appliances may not increase mandibular growth in long term. Although attaining a Class I relationship can be achieved with functional appliances. We also recommended maintaining the correction throughout transition to permanent dentition for proper post-treatment stabilization in order to prevent reverting back to its original occlusal during the transition to the permanent dentition. Without an adequate retention period to permit mineralization, adaptation of bone remodeling, the positive dento-alveolar, condylar and glenoid fossa response were subject to some relapse.

It has been reported that, appropriate functional appliances included Twinblock, Activator, Herbst appliance. These functional appliances caused a downward and forward movement of the condyle, which routinely eliminated many signs and symptoms of TMD in these patients. Functional appliances enabled to advance mandible to its correct position, allowed the condyles to assume their correct position

Symptoms of TMD included headaches, necklaces, ringing in the ears, stiffness in the ears, earaches, pain behind the eye, difficulty swallowing, fainting, and dizziness. (204). However, the samples of this study did not present any TMD symptoms in pre- and post-treatment.

The more advantage of using functional appliances to reposition the mandible forward in skeletal Class II malocclusions was expansion maxillary arch. This resulted in a much broader smile for the patients. When the maxilla was expanded, the palate would be drop, increased the size of the nasal cavity and encouraged nasal breathing. A proper development of the maxilla helped to improve respiration and provide more space for the tongue, eliminating many speech problems. The advancement of the mandible also increased the size of the airway in the posterior pharyngeal area and helps to encourage nasal breathing (204).

Sometime growing orthodontic patients later develop abnormal joint function. This may be the result of continuing mandibular growth after orthodontic treatment, rather than effects of treatment. Useful as mandibular growth may be during orthodontic treatment, it could nevertheless produce functional disharmony in later years. It was hard to coordinate the ultimate condyle growth and intercuspation of the teeth in advance of treatment. It was essential to be knowledgeable and alerted to disharmonies that may exist prior to, during, and after orthodontic treatment. It is important for the orthodontists to understand that continuing mandibular growth. A factor could not be controlled by any treatment procedure. This could produce a large problem of post-pubertal or post-orthodontic TMJ dysfunction.

In many diagnosis analysis and appliance-based techniques, the corrected position of maxillary incisors in the face was dictated by statistically generated or aesthetically based norms. The position of upper incisors in face must be based on several considerations going far beyond arbitrary conformity to some standard values based on average. Functional relationships and their effects on the joint were one of those considerations, along with esthetics. Upper incisors should not be over-retracted and over-steepened anterior guidance.

CHAPTER VII

CONCLUSIONS

This study investigated anterior guidance, condylar guidance, the difference and relation of these two angles in Class II division 1 patients treated with Activator and Twinblock appliances. Pre- and post-treatment lateral cephalometric radiographs of 63 patients (38 Activator, 13 Twinblock and 12 controls) were measured and evaluated. Findings were:

1. Anterior guidance inclination was increased, but condylar guidance inclination was not changed significantly by Activator and Twinblock appliances.
2. The relation of anterior guidance and condylar guidance were improved. The difference between anterior guidance and condylar guidance was increased. This difference made posterior disclusion possible. Furthermore, the correlation of these guidances was increased after treatment.
3. There was high positive correlation of anterior guidance with upper incisors inclination. Therefore, steepness of anterior guidance could also be assessed from inclination of upper central incisors
4. There was positive correlation of condylar guidance with condylar axis. Therefore steepness of condylar guidance could also be roughly assessed from condylar axis.
5. Activator and Twinblock therapy could produce the same orthopedics and orthodontics effects.
6. Antero-posterior relationship of maxillary-mandibular skeletal and dentition were improved significantly by treatment. There was no significant change in forward growth of maxilla. Mandible was increased in length and displaced forward and downward. Facial height and facial proportion was improved. Overjet was reduced by forward movement of mandible combine with retroclination and retraction of upper incisors as well as labial tipping and protraction of lower incisors. Glenoid fossa and condyle did not be displaced as result of treatment.

Limitation and Suggestion

This study compared the effects of the appliances and growth mean over an 11-month period. This included all patients regardless of compliance or achievement of a Class I or III molar relationship. Treatment was continued if malocclusions were not fully corrected within study period. Treatment time was too short to observe articular eminence and TMJ remodeling obviously in radiographic. The appliances needed to be worn for a prolonged period of time, usually 1.5 to 2 years to ensure complete condylar (6).

Some mean changes were modest and frequently smaller than their associated standard deviations. This may be caused the significant differences to underestimate the true situation. It must be stressed that this study reported the initial effects and no conclusions could be drawn about stability. Overall improvements in facial profile required long-term observation and follow-up.

Due to strict inclusion criteria for enrolment into the study, differences between groups would always exist. Increasing sample size would undoubtedly result in a more acceptable and would be advisable in view of the extremely variable treatment effects of functional appliances therapy.

It was difficult to identify TMJ structure especially glenoid fossa and condyle in lateral cephalometric radiographs. Therefore a second professional observer was recommended for checking accuracy. Condylar guidance measurement from cephalograms only may be not absolute truly accurate, because of condylar movement path was depended on anatomical and functions of meniscus, glenoid fossa shape, ligament attachment and involvement muscular function. Definite condylar guidance should be further investigated by other methods for comparison with cephalometric condylar guidance.

Finally, future studies should also include data on patients which were out of therapy for a number of years. In that respect it would be interesting to re-observe the patients of the present sample 5, 10 and 15 years out of retention, to evaluate which changes remained stable over the long-term and to find out in which cases unfavorable craniofacial developments occurred afterwards.

REFERENCES

1. Roth RH. Functional occlusion for orthodontis. *J Clin Orthod* 1981;14(1):32-51.
2. Broderson SP. Anterior guidance-The key to sucessesful occlusal treatment. *J Prosthet Dent* 1978;39(4):396-400.
3. Hobo S. Twin-tables technique for occlusal rehabilitation: Part 1-mechanism of anterior guidance. *J Prosthet Dent* 1991;66:299-303.
4. Katsavias EG. Changes in articular eminence inclination during the craniofacial growth period. *Angle Othod* 2002;72(3):258-64.
5. Katsavias EG. The effect of mandibular protrusive (Activator) appliances on articular eminence morphology. *Angle Othod* 2003;73(6):647-53.
6. Bishara SE, Ziaja RR. Functional appliances: A review. *Am J Orthod Dentofac Orthop* 1989;95(3):250-8.
7. Woodside DG, Metaxas A, Altuna G. The influence of functional appliance therapy on glenoid fossa remodeling. *Am J Orthod Dentofac Orthop* 1987;92(3):181-98.
8. Katsavias EG, Voudouris JC. The treatment effect of mandibular protrusive appliances on the glenoid fossa for Class II correction. *Angle Othod* 2004;74(1):79-85.
9. Birkbak L, Melsen B, Terp S. A laminagraphic study of the alterations in the temporo-mandibular joint following activator treatment. *Eur J Orthod* 1984;6:257-66.
10. Basciftci FA, Uysal T, Buyukermen A, Sari Z. The effect of activator treatment on the craniofacial structures of Class II division 1 pateints. *Eur J Orthod* 2003;25:87-93.
11. Cozza P, Toffol LD, Iacopini L. An analysis of the corrective contribution in Activator treatment. *Angle Othod* 2004;74(6):739-46.
12. Pancherz H. A cephalometric analysis of skeletal and dental changes contributing to Class II correction in activator treatment. *Am J Orthod* 1984;85(2):125-34.

13. Ruf S, Baltromejus S, Pancherz H. Effective condylar growth and chin position changes in Activator treatment: A cephalometric roentgenographic study. *Angle Othod* 2001;71(1):4-11.
14. Vargervik K, Harvold EP. Response to Activator treatment in Class II malocclusions. *Am J Orthod* 1985;88(3):242-51.
15. Clark WJ. Twin block functional therapy applications in dentofacial orthopaedics. London: Mosby-Wolfe; 1995.
16. Clark WJ. Twin block functional therapy. 2 ed. Edinburgh: Mosby; 2002.
17. Illing HM, Morris DO, Lee RT. A prospective evaluation of Bass, Bionator and Twin Block appliances. Part I - the hard tissues. *Eur J Orthod* 1998;20:501-16.
18. O'Brien K, Wright J, Conboy F, Sanjie Y, Mandall N, Chadwick S, et al. Effectiveness of early orthodontic treatment with the Twin-block appliance: A multicenter, randomized, controlled trial. Part 1: Dental and skeletal effects. *Am J Orthod Dentofac Orthop* 2003;124(3):234-43.
19. Mills CM, McCulloch KJ. Posttreatment changes after successful of Class II malocclusions with Twin block. *Am J Orthod Dentofac Orthop* 2000;118(1):24-33.
20. Singh GD. Bimaxillary morphometry of patients with Class II division 1 malocclusion treated with Twin Block appliance. *Angle Othod* 2002;72(5):402-9.
21. Trenouth MJ. Proportional changes in cephalometric distances during Twin Block appliances therapy. *Eur J Orthod* 2002;24:485-91.
22. Griffin AC. Temporomandibular joint morphology as relate to anterior occlusion and vertical facial height: a laminagraphic study. *Am J Orthod* 1983;83(1):85.
23. Okeson JP. Management of temporomandibular disorder and occlusion. 5 ed. St. Louis: Mosby; 2003.
24. Bell DE, Harris EF. Disclusion in mandibular protrusion. *Angle Othod* 1983;53(2):146-55.

25. Huffer RA, Vincenzo JPD, Corbett NE, Shryock EF. Relationship between the lingual of the maxillary central incisor and the articular eminence in ideal occlusions. *Angle Othod* 1972;42(1):44-9.
26. Thomson H. *Occlusion*. 2 ed. London: Wright; 1990.
27. Hobo S, Takayama H. *Oral rehabilitation clinical determination of occlusion*. Tokyo: Quintessence book; 1997.
28. Ash MM, Ramfjord S. *Occlusion*. 4 ed. Philadelphia: Saunders; 1995.
29. Clyde HS. The function and importance of incisal guidance in oral rehabilitation. *J Prosthet Dent* 1963;13:1011-29.
30. Kubein-Meesenburg D, Jager A, Bleifuss P. Incisal position analysis. *J Clin Orthod* 1986;20(1):37-42.
31. Wasson JL. *Achieving functional occlusion with orthodontics*. Maryland: J.W. Harper and Row; 1980.
32. McHorris WH. Occlusion with particular emphasis on the functional and parafunctional role of anterior teeth. *J Clin Orthod* 1979;13(9):606-20.
33. Schuyler CH. The function and importance of incisal guidance in oral rehabilitation. *J Prosthet Dent* 1963;13:1011-29.
34. Kohno S. The measurement and development of anterior guidance. *J Prosthet Dent* 1987;57(5):620-5.
35. Servadio Y, Aviv E, Gazit E, Fitzig S, Lieberman M. A craniographic examination of the condylar angle and the maxillary incisal palatal angle in Bedouin skulls. *Int J Adult Orthod Orthog Surg* 1990;5(3):199-203.
36. Nickel JC, McLachlan KR, Smith DM. Eminence development of the postnatal human temporomandibular joint. *J Dent Res* 1988;67(6):896-902.
37. Ichikawa W, Laskin DM, Rosenberg HM, Richmond. Trancranial radiographic and tomographic analysis of the lateral and midpoint inclined planes of the articular eminence. *Oral Surg Oral Med Oral Pathol* 1990;70:516-22.
38. Panmekiate S, Petersson A, Akerman S. Angulation and prominence of the posterior slope of the eminence of the temporomandibular joint in relation to disc position. *Dentomaxillofac Radiol* 1991;19:205-8.

39. Kertens HCJ, Tuinzing DB, Golding RP, Kwast WAMVd. Inclination of the temporomandibular joint eminence and anterior disc displacement. *Int J Oral Maxillofac surg* 1989;18:229-32.
40. Olsson A, Posselt U. Relationship of various skull reference lines. *J Prosthet Dent* 1961;11(6):1045-9.
41. Wattanatchariya W. Anterior guidance and condylar guidance in normal occlusion and skeletal type I, II and III. Bangkok: Mahidol University; 1998.
42. Granados JI. The influence of the loss of teeth and attrition on the articular eminence. *J Prosthet Dent* 1979;42(1):78-85.
43. Ren Y-F, Isberg A, Westesson P-L, Umea, Beijing. Steepness of the articular eminence in the temporomandibular joint. *Oral Surg Oral Med Oral Pathol Oral Radiol Endod* 1995;80:258-66.
44. Galante G, Paesani D, Tallents RH, Hatala MA, Katzberg RW, Murphy W, et al. Angle of the articular eminence in patients with temporomandibular joint dysfunction and asymptomatic volunteers. *Oral Surg Oral Med Oral Pathol Oral Radiol Endod* 1995;80:242-9.
45. Ruf S, Pancherz H. Temporomandibular joint growth adaptation in Herbst treatment: a prospective magnetic resonance imaging and cephalometric roentgenographic study. *Eur J Orthod* 1998;20:375-88.
46. Ruf S, Pancherz H. Temporomandibular joint remodeling in adolescents and young adult during Herbst treatment: A prospective longitudinal magnetic resonance imaging and cephalometric radiographic investigation. *Am J Orthod Dentofac Orthop* 1999;115:607-18.
47. Silapabangleng Y. Condylar path angles in a group of patients. *C. U. Dent. J.* 1991;14(1):25-31.
48. Pirttiniemi P, Kantomaa T, Ronning O. Relation of the glenoid fossa to craniofacial morphology, studied on dry human skulls. *Acta Odontol Scand* 1990;48:359-64.
49. Widman DJ. Functional and morphologic considerations of the articular eminence. *Angle Othod* 1988;58(3):221-36.
50. Fletcher AM. Ethnic variations in sagittal condylar guidance angles. *J Dent* 1985;13(4):304-10.

51. Corbett NE, Vincenzo JPD, Huffer RA, Shryock EF. The relation of the condylar path to the articular eminence in mandibular protrusion. *Angle Othod* 1971;41(4):286-92.
52. Reungrongrat P, Silapabangleng Y. Degree of condylar path angles from protrusive records. *C. U. Dent. J.* 1991;14(2):95-103.
53. Kerstens HCJ, Tuinzing DB, Golding RP, Kwast WAMVd. Inclination of the temporomandibular joint eminence and anterior disc displacement. *Int J Oral Maxillofac surg* 1989;18:229-32.
54. Sulun T, Cemgil T, Jean-Marc, Rammelsberg P, Jager L, Gernet W, et al. Morphology of the mandibular fossa and inclination of the articular eminence in patients with internal derangement and in symptom-free volunteers. *Oral Surg Oral Med Oral Pathol Oral Radiol Endod* 2001;92:98-107.
55. Kurita H, Ohtsuka A, Kobayashi H, Kurashina K. Is the morphology of the articular eminence of the temporomandibular joint a predisposing factor for disc displacement? *Dentomaxillofac Radiol* 2000;29:159-62.
56. Kurita H, Ohtsuka A, Kobayashi H, Kurashina K. Flattening of the articular eminence correlates with progressive internal derangement of the temporomandibular joint. *Dentomaxillofac Radiol* 2000;29:277-9.
57. Hall MB, Gibbs CC, Sclar AG. Association between the prominence of the articular eminence and displaced TMJ disks. *Cranio* 1985;3:237-9.
58. Gokalp H, Turkkahraman H, Bzeizi N. Correlation between eminence steepness and condyle disc movements in temporomandibular joints with internal derangement on magnetic resonance imaging. *Eur J Orthod* 2001;23:579-84.
59. Thompson JR. Abnormal function of the temporomandibular joints and related musculature. *Angle Othod* 1986;56(2):181-95.
60. Kantomaa T. The shape of the glenoid fossa affects the growth of the mandible. *Eur J Orthod* 1988;10:249-54.
61. Kantomaa T. The relation between mandibular configuration and the shape of the glenoid fossa in the human. *Eur J Orthod* 1989;11:77-81.

62. Lundeen HC, Gibbs CH. Advances in occlusion. Massachusetts: John Wright; 1982.
63. Bibby RE. Incisor relationships in different skeletofacial patterns. *Angle Othod* 1980;50(1):41-44.
64. Ingervall B. Relation between height of the articular tubercle of the temporomandibular joint and facial morphology. *Angle Othod* 1974;44(1):15-23.
65. Cohlma JT, Ghosh J, Sinha PK, Nanda RS, Currier GF. Tomographic assessment of temporomandibular joints in patients with malocclusion. *Angle Othod* 1996;66(1):27-36.
66. Ikai A, Sugisaki M, Young-Sung K, Tanabe H. Morphologic study of the mandibular fossa and the eminence of the temporomandibular joint in relation to the facial structures. *Am J Orthod Dentofac Orthop* 1997;112(6):634-8.
67. Akahane Y, Deguchi T, Hunt NP. Morphology of the temporomandibular joint in skeletal Class III symmetrical and asymmetrical cases: a study by cephalometric laminography. *J Orthod* 2001;28:119-27.
68. Katsavias EG, Halazonetis DJ. Condyle and fossa shape in Class II and Class III skeletal patterns: A morphometric tomographic study. *Am J Orthod Dentofac Orthop* 2005;128(3):337-46.
69. Agronin KJ, Kokich VG. Displacement of the glenoid fossa: A Cephalometric evaluation of growth during treatment. *Am J Orthod Dentofac Orthop* 1987;91(1):42-8.
70. Tanaka T, Morimoto Y, Tanaka Y, Kobayashi S, Okumura Y, Kito S, et al. Radiographic examination of the mandibular (glenoid) fossa in ancient and modern man. *Oral Diseases* 2004;10:369-77.
71. Zarb GA, Carlsson GE, Sessle BJ, Mohl ND. Temporomandibular joint and masticatory muscle disorders. 2 ed: Munksgaard; 1994.
72. Wright DM, Benjamin C, Moffett J. The Postnatal development of the human temporomandibular joint. *Am J Anat* 1974;141:235-50.
73. Roberts WE, Hartsfield JK. Bone development and function: Genetic and environment mechanisms. *Semin Orthod* 2004;10:100-22.

74. Klineberg I, Jagger R. Occlusion and clinical practice an evidence-based approach. Edinburgh: Wright; 2004.
75. Moyers RE. Handbook of orthodontics. 4 ed. Chicago: Year book medical publishers; 1988.
76. Shaw WC. Orthodontics and occlusal management. Oxford: Wright; 1993.
77. Proffit WR, Henry W, Fields J. Contemporary orthodontics. 3 ed. St. Louis: Mosby; 2000.
78. Caldwell S, Cook P. Predicting the outcome of Twin Block functional appliance treatment: a prospective study. *Eur J Orthod* 1999;21:533-9.
79. Graber TM, Robert L, Vanarsdall J. Orthodontics current principles and techniques. 2 ed. St. Louis: Mosby; 1994.
80. Harvold EP, Vargervik KS. Morphogenetic response to activator treatment. *Am J Orthod* 1971;60:478-90.
81. Vardimon AD, Koklu S, Iseri H, Shpack N, Fricke J, Mete L. An assessment of skeletal and dental responses to the functional magnetic system (FMS). *Am J Orthod Dentofac Orthop* 2001;120(4):416-26.
82. Nelson C, Harkness M, Herbison P. Mandibular changes during functional appliances treatment. *Am J Orthod Dentofac Orthop* 1993;104(2):153-61.
83. Hinton RJ, McNamara JA. Temporal bone adaptations in response to protrusive function in juvenile and young adult rhesus monkeys (*Macaca mulatta*). *Eur J Orthod* 1984;6:155-74.
84. Rabie ABM, Wong L, Tsai M. Replicating mesenchymal cells in the condyle and the glenoid fossa during mandibular forward position. *Am J Orthod Dentofac Orthop* 2003;123(1):49-57.
85. Ruf S, Wusten B, Pancherz H. Temporomandibular joint effect of Activator treatment: A prospective longitudinal magnetic resonance imaging and clinical study. *Angle Orthod* 2002;72(6):527-40.
86. Hagg EU, Taranger J. Skeletal stages of the hand and wrist as indicators of the pubertal growth spurt. *Acta Odontol Scand* 1980;38:187-200.
87. Houston WJB, Miller JC, Tanner JM. Prediction of the timing of the adolescent growth spurt from ossification events in hand-wrist films. *Br J Orthod* 1979;6:145-52.

88. Grave K, Townsend G. Cervical vertebral maturation as a predictor of the adolescent growth spurt. *Aust Orthod J* 2003;19(1):25-32.
89. Baccetti T, Franchi L, McNamara JA. An improved version of the cervical vertebral maturation (CVM) method for the assessment of mandibular growth. *Angle Othod* 2002;72(4):316-23.
90. Rajagopal R, Kansal S. A comparison of modified MP3 stages and the cervical vertebrae as growth indicators. *J Clin Orthod* 2002;36(7):398-406.
91. Sawaengkit P, Dechkunakorn S, Anuwongnukroh N, Sonthilawat P. Sagittal jaw base relationship in Thai norms. *J Dent Assoc Thai* 1992;42:62-8.
92. Dechkunakorn S, Sawaengkit P, Chaiwat J, Anuwongnukroh N, Taweeseedt N. Thai adult norms in various lateral cephalometric analyses. *J Dent Assoc Thai* 1994;44(5-6):202-14.
93. Ferrario VF, Sforza C, Franco DJD. Mandibular shape and skeletal divergency. *Eur J Orthod* 1999;21:145-53.
94. Phillips C. Sample size and power: What is enough? *Semin Orthod* 2002;8(2):67-76.
95. Houston WJB. The analysis of errors in orthodontic measurements. *Am J Orthod* 1983;83(5):382-90.
96. Jacobson A. *Radiographic cephalometry*. Chicago: Quintessence books; 1995.
97. Gravely JF, Bezies M. The clinical significance of tracing error in cephalometry. *Br J Orthod* 1974;1(3):95-101.
98. Ricketts RM. Perspectives in the clinical application of cephalometrics. *Angle Othod* 1981;51:115-50.
99. Burstone CJ, James RB, Legan H, Murphy GA, Norton LA. Cephalometrics for orthognathic surgery. *J Oral Surg* 1978;36:269-77.
100. Miyashita K. *Contemporary cephalometric radiography*. Tokyo: Quintessence book; 1996.
101. Anuwongnukroh N, Sawaengkit P, Chaiwat P, Dechkunakorn S. Magnification of lateral and posteroanterior cephalograms in various x-ray machines. *J Dent Assoc Thai* 1992;42(5-6):244-55.
102. Dahlberg G. *Statistical methods for medical and psychological students*. New York: Interscience Publications; 1940.

103. Bejork A, Skieller V. Normal and abnormal growth of the mandible. A synthesis of longitudinal cephalometric implant studies over a period of 25 years. *Eur J Orthod* 1983;5:1-46.
104. Steiner CC. The use of cephalometrics as an aid to planning and assessing orthodontic treatment. *Am J Orthod* 1960;46:721-35.
105. Downs WB. Analysis of the dento-facial profile. *Angle Othod* 1956;26:191-212.
106. Rochanawutanon S, Chaiwat J. Condylar axis rotation following sagittal split ramus osteotomy for mandibular reposition. *J Dent Assoc Thai* 1993;43(5):252-9.
107. Hayasaki SM, Henriques JFC, Janson G, Freitas MRd. Influence of extraction and nonextraction orthodontic treatment in Japanese-Brazilians with Class I and Class II Division 1 malocclusions. *Am J Orthod Dentofac Orthop* 2005;127(1):30-6.
108. Jacobson A. The "Wits" appraisal of jaw disharmony. *Am J Orthod Dentofac Orthop* 2003;124(5):470-479.
109. McNamara JA. A method of cephalometric evaluation. *Am J Orthod* 1984;86:449-69.
110. Trenouth MJ. Cephalometric evaluation of the Twin-block appliance in the treatment of Class II division 1 malocclusion with matched normative growth data. *Am J Orthod Dentofac Orthop* 2000;117(1):54-9.
111. Tulloch JF, Proffit WR, Phillips C. Outcomes in a 2-phase randomized clinical trial of early Class II treatment. *Am J Orthod Dentofac Orthop* 2004;125:657-67.
112. Pancherz H, Hagg EU. Dentofacial orthopedics in relation to somatic maturity: an analysis of 70 consecutive cases treated with the Herbst appliance. *Am J Orthod* 1985;88:273-87.
113. Stallard H, Stuart CE. Concepts of occlusion. In: *Dent Clinics. North America*; 1963. p. 591-606.
114. Buschang PH, Santos-Pinto A. Condyle growth and glenoid fossa displacement during childhood and adolescence. *Am J Orthod Dentofac Orthop* 1998;113(4):437-42.

115. Argonin K, Kokiich V. Displacement of glenoid fossa: a cephalometric evaluation of growth during treatment. *Am J Orthod Dentofac Orthop* 1987;91:42-8.
116. Angela MF. Ethnic variations in sagittal condylar guidance angles. *J Dent* 1985;13(4):304-10.
117. Kikuchi K, Takeuchi S, Tanaka E, Shibaguchi T, Tanne K. Association between condylar position, joint morphology and craniofacial morphology in orthodontic patients without temporomandibular joint disorders. *J Oral Rehabil* 2003;30:1070-5.
118. Christensen LV, Slabbert JCG. The concept of the sagittal condylar guidance: biological fact or fallacy? *J Oral Rehabil* 1978;5:1-7.
119. Fretitas Ad. A comparison of the radiograph and prosthetic measurements of the sagittal path of movement of the mandibular condyle. *Oral Surg* 1970;30:631.
120. Ichikawa W, Laskin DM. Anatomic study of the angulation of the lateral and midpoint inclined planes of the articular eminence. *Cranio* 1989;7:22-6.
121. Cohen R. The relationship of anterior guidance of condylar guidance in mandibular movement. *J Prosthet Dent* 1956;6:758-67.
122. Cura N, Sarac M, Ozturk Y, Surmeli Y. Orthodontic and orthopedic effects of activator, activator-HG combination and Bass appliance: a comparative study. *Am J Orthod Dentofac Orthop* 1996;110:36-45.
123. Javid NS. An comparative study of sagittal and lateral condylar paths in different articulators. *J Prosthet Dent* 1974;31:130-6.
124. Posselt U, Nevstedt P. Registration of the condylar path inclination by intraoral wax records. *J Prosthet Dent* 1961;11:43-7.
125. Kucukkeles N, Ozkan H, Ari-Demirkara A, Cilingirturk AM. Compatibility of mechanical and computerized axiographs: A pilot study. *J Prosthet Dent* 2005;94:190-4.
126. Poswillo DE. The late effects of mandibular condylectomy. *Oral Surg Oral Med Oral Pathol* 1972;33:500-12.

127. Lindahl L, Hollender L. Condylar fractures of the mandible. A radiographic study of the remodeling processes in the temporomandibular joint. *Int J Oral Maxillofac surg* 1977;6:153-65.
128. Kantomaa T. Effect of increased posterior displacement of the glenoid fossa on mandibular growth: A methodological study on the rabbit. *Eur J Orthod* 1984;6:15-24.
129. Mongini F. Condylar remodeling after occlusal therapy. *J Prosthet Dent* 1980;43:568-77.
130. Hinton RJ. Changes in articular eminence morphology with dental function. *Am J Phys Anthropol* 1981;54:439-55.
131. Isberg A, Westesson PL. Steepness of articular eminence and movement of the condyle and disk in asymptomatic temporomandibular joint. *Oral Surg Oral Med Oral Pathol Oral Radiol Endod* 1998;86(2):152-7.
132. Katsavias EG, Halazonetis DJ. Intermaxillary forces during Activator treatment. *Am J Orthod Dentofac Orthop* 1999;115:133-7.
133. Novo T, Tanne K, Sakuda M. Orthodontic forces exerted by activators with varying construction bite heights. *Am J Orthod Dentofac Orthop* 1994;105:169-79.
134. Voudouris JC, Kuftinee M. Improved clinical use of Twinblock and Herbst as a result of radiating viscoelastic tissue forces on the condyle and fossa in treatment and long-term retention. *Am J Orthod Dentofac Orthop* 2000;117:247-66.
135. Rabie ABM, Zhao Z, Shen G, Hagg EU, Robinson W. Osteogenesis in the glenoid fossa in response to mandibular advancement. *Am J Orthod Dentofac Orthop* 2001;119:390-400.
136. Ma B, Sampson W, Fazzalari N, Wilson D, Wiebkin O. Experimental forward mandibular displacement in sheep. *Arch Oral Biol* 2002;47:75-84.
137. O'Ryan F, Epker BN. Temporomandibular joint function and morphology: observations on the spectra of normalcy. *Oral Surg Oral Med Oral Pathol* 1984;58:272-9.

138. Sato S, Kawaura H, Motegi K, Takahashi K. Morphology of the mandibular fossa and the articular eminence in temporomandibular joints with anterior disk displacement. *Int J Oral Maxillofac surg* 1996;25:236-8.
139. Lucia VO. Principles of articulation. *Dent Clin North Am* 1979;23(2):199-211.
140. Dawson PE. Evaluation, diagnosis, and treatment of occlusal problems. St. Louis: C.V. Mosby; 1974.
141. Enlow DH. Facial growth. 3 ed. Philadelphia: Saunders; 1990.
142. Bjork O. Normal and abnormal growth of the mandible: A synthesis of longitudinal cephalometric implant studies over a period of 25 years. *Eur J Orthod* 1983;5:1-46.
143. McNamara JA, Bookstein FL, Shaughnessy TG. Skeletal and dental changes following functional regulator therapy on Class II patients. *Angle Othod* 1985;88:91-110.
144. Chang HF, Wu KM, Chen KC, Cheng MC. Effects of activator treatment on Class II division 1 malocclusion. *J Clin Orthod* 1989(23):560-3.
145. Almeida MRd, Henriques JFC, Almeida RRd, Ursi W, McNamara JA. Short-term treatment effects produced by the Herbst appliance in the mixed dentition. *Angle Othod* 2005;75(4):540-7.
146. Jakobsson SO, Paulin G. The influence of activator treatment on skeletal growth in Angle Class II:1 cases. A roentgenocephalometric study. *Eur J Orthod* 1990;12:174-84.
147. Croft RS, Burchang PH, English JD, Moyer R. A Cephalometric and tomographic evaluation of Herbst treatment in the mixed dentition. *Am J Orthod Dentofac Orthop* 1999;116:435-43.
148. Birkebak L, Melsen B, Terp S. A laminagraphic study of the alterations in the temporo-mandibular joint following activator treatment. *Eur J Orthod* 1984;6:257-66.
149. Pancherz H, Fischer S. Amount and direction of temporomandibular joint growth changes in Herbst treatment: A cephalometric long-term investigation. *Angle Othod* 2003;73:493-501.
150. Owen AH. Morphologic changes in the sagittal dimension using the Frankel appliance. *Am J Orthod Dentofac Orthop* 1981;80:573-603.

151. Chadwick SM, Aird JC, Taylor PJS, Bearn DR. Functional regulator treatment of Class II division 1 malocclusion. *Eur J Orthod* 2001;23:495-505.
152. Gill D, Sharma A, Naini F, Jones S. The Twin block appliance for the correction of Class II malocclusion. *Dent Update* 2005;32:158-68.
153. Birkebaek L, Melsen B, Terp S. A laminagraphic study of the alterations in the temporo-mandibular joint following activator treatment. *Eur J Orthod* 1984;6:257-66.
154. Righellis EG. Treatment effects of Frankel, activator and extraoral traction appliances. *Angle Othod* 1983;53:107-21.
155. Baumrind S, Frantz RC. The reliability of head film measurements. *Am J Orthod* 1971;60:111-27.
156. Hagg EU, Attstrom K. Mandibular growth estimated by four cephalometric measurements. *Am J Orthod Dentofac Orthop* 1992;102:146-52.
157. Burchang PH, Santos-Pinto A, Demirjian A. Increment growth charts for condylar growth between 6 and 16 years of age. *Eur J Orthod* 1999;21:167-73.
158. Marschner JF, Harris JE. Mandibular growth and Class II treatment. *Angle Othod* 1966;36(1):89-93.
159. Bjork O. The principle of the Andresen method of orthodontic treatment, a discussion based on cephalometric X-ray analysis of treated cases. *Am J Orthod Dentofac Orthop* 1951;37:437-58.
160. Ghafari J, King GJ, Tulloch JF. Early treatment of Class II division 1 malocclusion-comparision of alternative treatment modalities. *Clin Orthod Res* 1998;1:107-17.
161. King GJ, McGorray SP, Wheeler TT, Dolce C, Taylor M. Comparision of peer assessment rating (PAR) from 1-phase and 2-phase treatment protocols for Class II malocclusions. *Am J Orthod Dentofac Orthop* 2003;123:489-96.
162. Baumrind S, Korn EL, Issacson RJ, West EE, Molthen R. Superimpositional assestment of treatment-associated changes in the temporomandibular joint and the mandibular symphysis. *Am J Orthod* 1983;84:443-65.

163. Baccetti T, Franchi L, Toth LR, McNamara JA. Treatment timing for twin block therapy. *Am J Orthod Dentofac Orthop* 2000;118(159-70).
164. Faltin KJ, Faltin RM, Baccetti T, Franchi L, Ghiozzi B, McNamara JA. Long-term effectiveness and treatment timing for bionator therapy. *Angle Othod* 2003;73:221-30.
165. McNamara JA, Carlson DS. Quantitative analysis of temporomandibular joint adaptations to protrusive function. *Am J Orthod* 1979;76(6):593-611.
166. Pancherz H. The effects, limitations, and long term dentofacial adaptations to treatment with the herbst appliance. *Semin Orthod* 1997;3:232-43.
167. Rabie ABM, She TT, Hagg U. Functional appliance therapy accelerates and enhances condylar growth. *Am J Orthod Dentofac Orthop* 2003;123(1):40-8.
168. Johnston LE. Functional appliances: a mortgage on mandibular position. *Aust Orthod J* 1996;14:154-7.
169. Petrovic AG, Stutzmann JJ, Gasson N. The final length of the mandible: Is it genetically determined? *Craniofacial biology* 1981;10:105-26.
170. Voudouris JC, Woodside DG, Altuna G, Kuflinec MM, Angelopoulos G, Bourque PJ. Condyle-fossa modifications and muscle interactions during Herbst treatment, Part 2. Results and conclusions. *Am J Orthod Dentofac Orthop* 2003;124(1):13-29.
171. Chayanupatkul A, Rabie ABM, Hagg EU. Temporomandibular response to early and late removal of bite-jumping devices. *Eur J Orthod* 2003;25:465-70.
172. Delvin H. Early bone healing events following rat molar tooth extraction. *Cells and Tissue Organs* 2000;167:33-7.
173. Salo LA, Raustia AM. Type II and type III collagen in mandibular condylar cartilage of patients with temporomandibular joint pathology. *J Oral Maxillofac surg* 1995;53:39-44.
174. Hagg EU, Du X, Rabie ABM. Growth modification of severe skeletal Class II malocclusions by dentofacial orthopaedics. *Eur J Orthod* 2001;23:452.
175. Wieslander L. Long-term effect of treatment with the headgear-Herbst appliance in the early mixed dentition. Stability or relapse? *Am J Orthod Dentofac Orthop* 1993;104:319-29.

176. Tomer BS, Harvold EP. Primate experiments on mandibular growth direction. *Am J Orthod* 1982;82:114-9.
177. Ruf S, Pancherz H. The effect of Herbst appliance treatment on the mandibular plane angle: a cephalometric roentgenographic study. *Am J Orthod Dentofac Orthop* 1996;110:225-9.
178. Gill DS, Lee RT. Prospective clinical trial comparing the effects of conventional Twin-block and mini-block appliances: Part 1. Hard tissue changes. *Am J Orthod Dentofac Orthop* 2005;127(4):465-72.
179. Luder HU. Skletal profile changes related to two patterns of activator effects. *Am J Orthod* 1982;81(2):390-6.
180. Chabre C. Vertical control with headgear-activator combination. *J Clin Orthod* 1990;24:618-24.
181. Lai M, McNamara JA. An evaluation of two phase treatment with the Herbst appliance and preadjusted edgewise therapy. *Semin Orthod* 1998;4:46-58.
182. Chengprapakorn S. Roentgenographic cephalometry study in Thai children age 11-16 years. Bangkok: Chulalongkorn; 1981.
183. Moss ML, Rankow RM. The role of the functional matrix on mandibular growth. *Angle Orthod* 1968;38(2):95-103.
184. Katsavias EG. Effects of mandibular protrusive (functional) appliances on condylar position. *World J Orthod* 2003;4:243-9.
185. Sahm G, Witt E. Long-term results after childhood condylar fractures. A computertomographic study. *Eur J Orthod* 1989;11:154-60.
186. Dahan J, Dombrowsky K, Oehler K. Static and dynamic morphology of the temporomandibular joint before and after functional treatment with activator. *Trans Eur Orthod Soc* 1969;45:255-74.
187. Popovich F, Thompson GW. Craniofacial templates for orthodontic case analysis. *Am J Orthod* 1977;71:406-20.
188. Lund DI, Sandler PJ. The effects of Twin blocks: a prospective controlled study. *Am J Orthod Dentofac Orthop* 1998;113:104-10.
189. Darendeliler N, Dincer M, Soylu R. The biomechanical relationship between incisor and condylar guidances in deepbite and normal cases. *J Oral Rehabil* 2004;31:430-7.

190. Tallent RH, Catania J, Sommers E. Temporomandibular joint finding in pediatric population and young adults: a critical review. *Angle Othod* 1990;61:7-15.
191. Ricketts RM. Clinical implications of the temporomandibular joint. *Am J Orthod* 1973;52:416-39.
192. Roth RH. Temporomandibular pain-dysfunction and occlusal relationships. *Angle Othod* 1966;43:136-53.
193. Weinberg LA. Incisal and condylar guidance in relation to cuspal inclination in lateral excursions. *J Prosthet Dent* 1958;9(851-62).
194. Ogawa T, Koyano K, Suetsugu T. The influence of anterior guidance and condylar guidance on mandibular protrusive movement. *J Oral Rehabil* 1997;24:303-9.
195. Alawaf MM, Garlapo DA. Influence of tooth contact on the path of condylar movement. *J Prosthet Dent* 1992;67:394-400.
196. Pelletier LB, Campbell SD. Evaluation of the relationship between anterior and posterior functionally disclusive angles. *J Prosthet Dent* 1990;63:395.
197. Ricketts RM. Variations of the temporomandibular joint as revealed by cephalometric laminagraphy. *Am J Orthod* 1950;36:877-98.
198. Goldsman S. Facial types. *Angle Othod* 1959;29:63.
199. Weinberg S. Eminectomy and meniscorhaphy for internal derangments of the TMJ. *Oral Surg* 1984;57(3):241-9.
200. Nagata M, Yamasaki Y, Hayasaki H. Incisal and condylar paths during habitual mouth opening movement of children with anterior reverse bite in the primary dentition. *J Oral Rehabil* 2002;29:64-71.
201. Takahashi A, Ogura H, Tokuoka O, Iwasaki H, Fujishita M, Fuchihata H. Radio-diagnosis study the temporo-mandibular joint in mandibular protrusion. *J Japan Dent Radiol* 1985;25:166.
202. Iwakata S. A study on occlusion of subjects with skeletal Class III malocclusion Part 1. Positional relation between occlusal surfaces of upper and lower molars during protrusive excursion. *J Japan Prosthodontic Society* 1990;34:921.

203. Langer G. A tomographic comparison of the temporomandibular joint in the hypo- and hyperdivergent patient. *Am J Orthod Dentofac Orthop* 1977;74:335.
204. Rondeau B. The benefits of early orthodontic treatment. *Gen Dent* 2003;71(2):114-9.



BIOGRAPHY



NAME Mr. Phanlop Tribuppachatsakul

DATE OF BIRTH 8 April 1974

PLACE OF BIRTH Kamphaengphet, Thailand

INSTITUTIONS ATTENDED Chiangmai University, 1992-1998:
Doctor of Dental Surgery
Mahidol University, 2004-2006:
Master of Science (Orthodontics)

OFFICE ADDRESS Dental Department, Bantak Hospital
Bantak, Tak, Thailand, 63120
Tel. 0-5559-1435-6

HOME ADDRESS 72, Moo 1, Tambol Srakaew, Amphur Muang
Kamphaengphet, Thailand, 62000
Tel. 0-5571-3898, 0-1324-2273